

LA VIOLENZA **SUI SOGGETTI FRAGILI**

9 OTTOBRE 2021



ORDINE DEI MEDICI CHIRURGI
E DEGLI ODONTOIATRI
DELLA PROVINCIA DI BERGAMO



ASPETTI MEDICO-LEGALI **IN CASO DI VIOLENZA** **SU MINORI E ANZIANI**

Matteo Marchesi
Medico legale
ASST Papa Giovanni XXIII

FONDAMENTI

1. Sono anzitutto casi **CLINICI** (!)
2. Esistono **criteri diagnostici** (→ studiare)
3. **Responsabilità** genitoriale → *“superiore interesse del minore”*
4. **“Accortezze”** medico-legali
5. **Collegialità**: sanitaria – sociale – giudiziaria





*Di rado è possibile
(e quasi mai necessario)
concludere definitivamente
nelle **prime ore** di una valutazione
che si è verificato un abuso.*

*Quando si sospetta
un abuso su un minore,
occorre aver presente la necessità
di **ulteriori valutazioni**
ed evitare di formulare accuse.*



Responding to children and adolescents who have been sexually abused: WHO Clinical Guidelines (2017)

WHO Guidelines for the Health Sector Response to Child Maltreatment (2019)

CHILD ABUSE:

Recognition, Diagnostic evaluation and management

Neglect

Abusive head trauma

Orthopedic aspects

Munchausen syndrome by proxy

Differential diagnosis

Social and medicolegal issues



Red flag history for child physical abuse

- No history or denial of trauma despite severe injury
- Implausible history for degree or type of injury*
- Unexplained or excessive delay in seeking care
- Injury attributed to in-home resuscitation efforts
- Caregiver histories that change with retelling or conflict with versions from other observers
- Severe injury explained as self-inflicted or blamed on other young children or pets

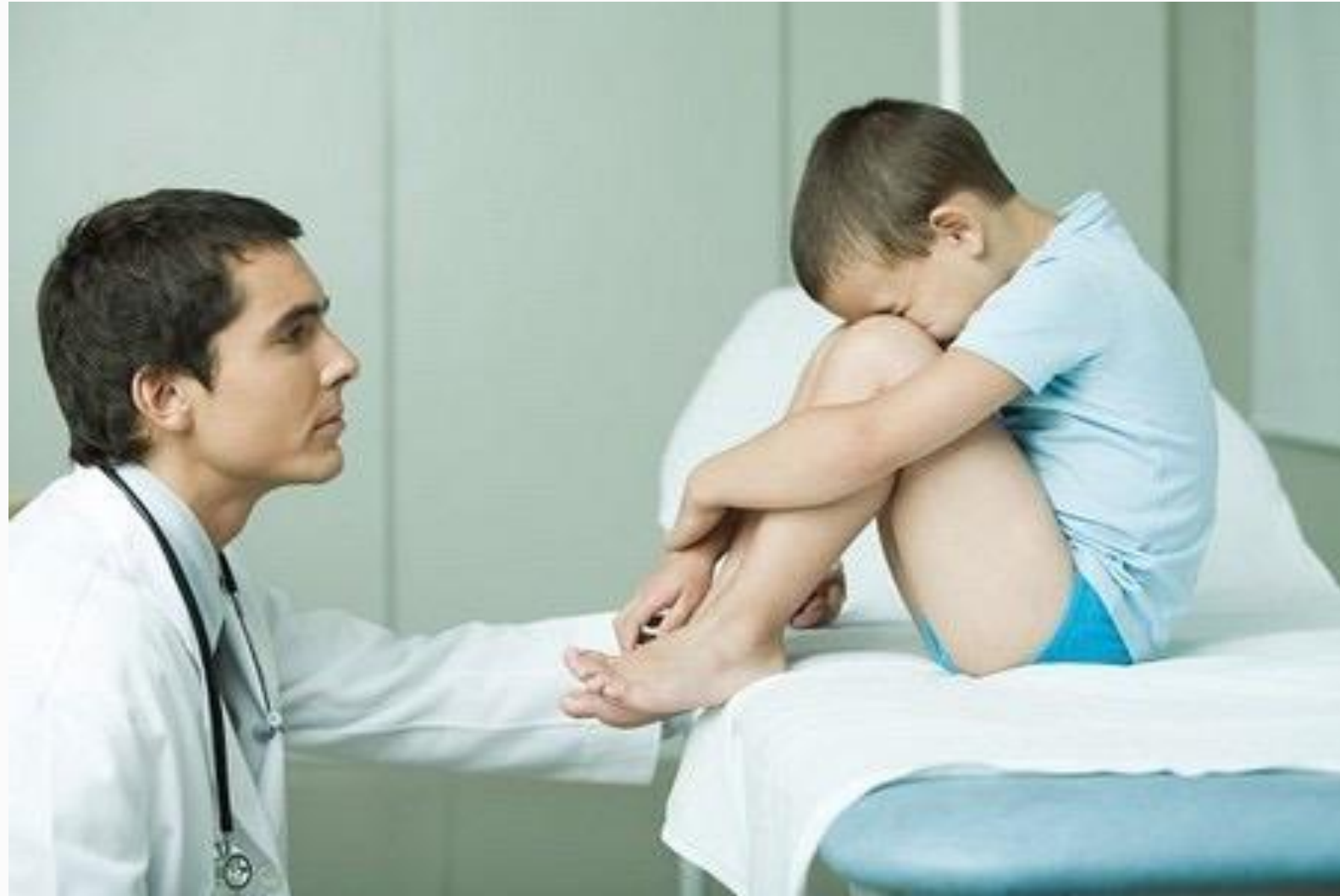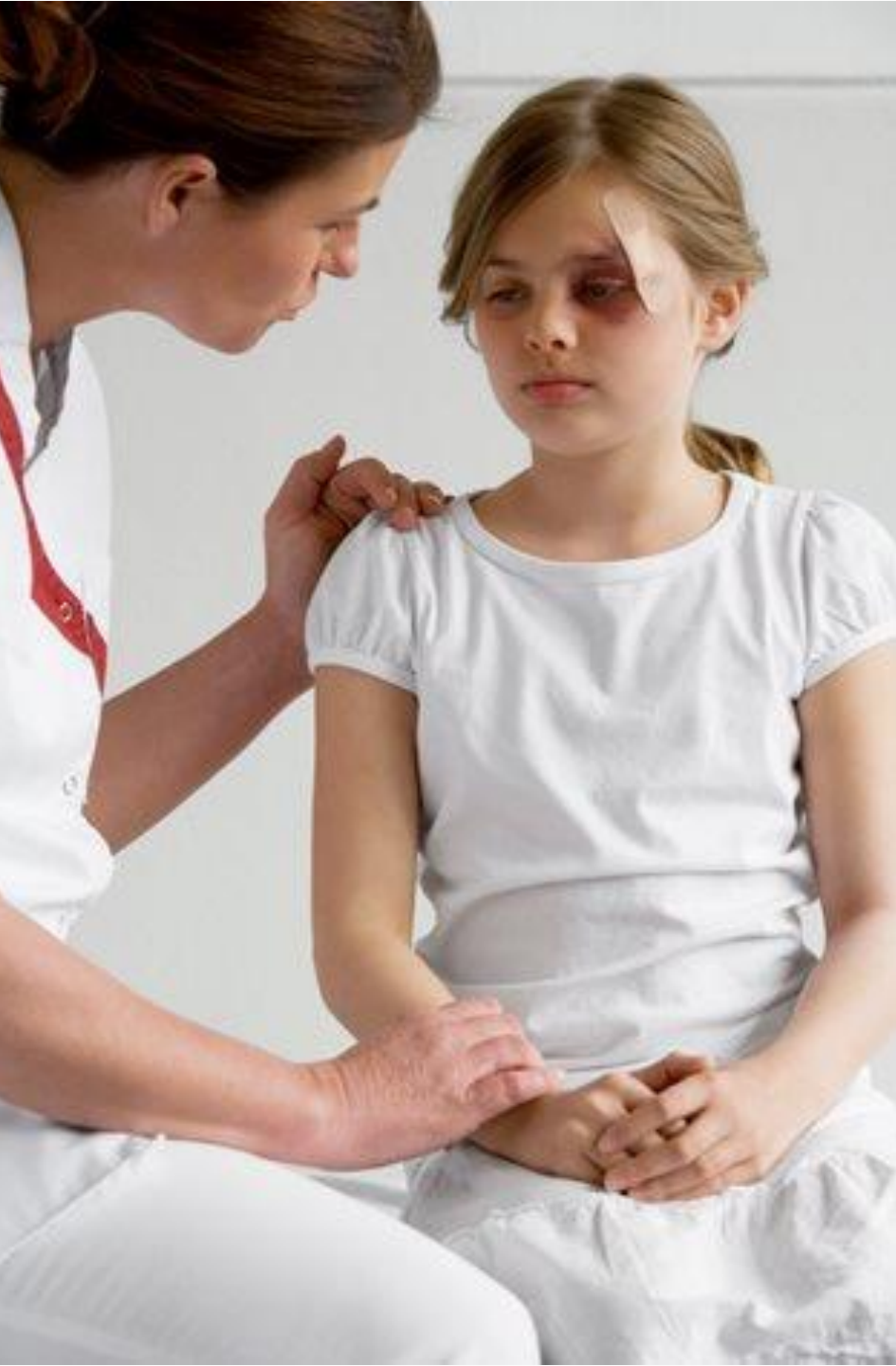* Examples of implausible histories include major trauma attributed to a "fall down the stairs" or other short fall, such as a fall from a sitting position, or an injury mechanism that requires the child to have capability beyond his or her developmental level (eg, severe scald burns in a 12-month-old attributed to the patient "turning on the hot water faucet").

ANAMNESI

TEMPO + AMBIENTE TRANQUILLO

ANAMNESI → fattori di rischio

correlati al minore / ai genitori / al contesto sociale



Distinzione

Chi riferisce? Pz? Accompagnatori?
Forze dell'Ordine?
Sulla base di cosa riferisce?



Dettaglio

NON rielaborare né sintetizzare,
ma registrare le **“esatte parole”**,



senza domande intrusive né suggestive,

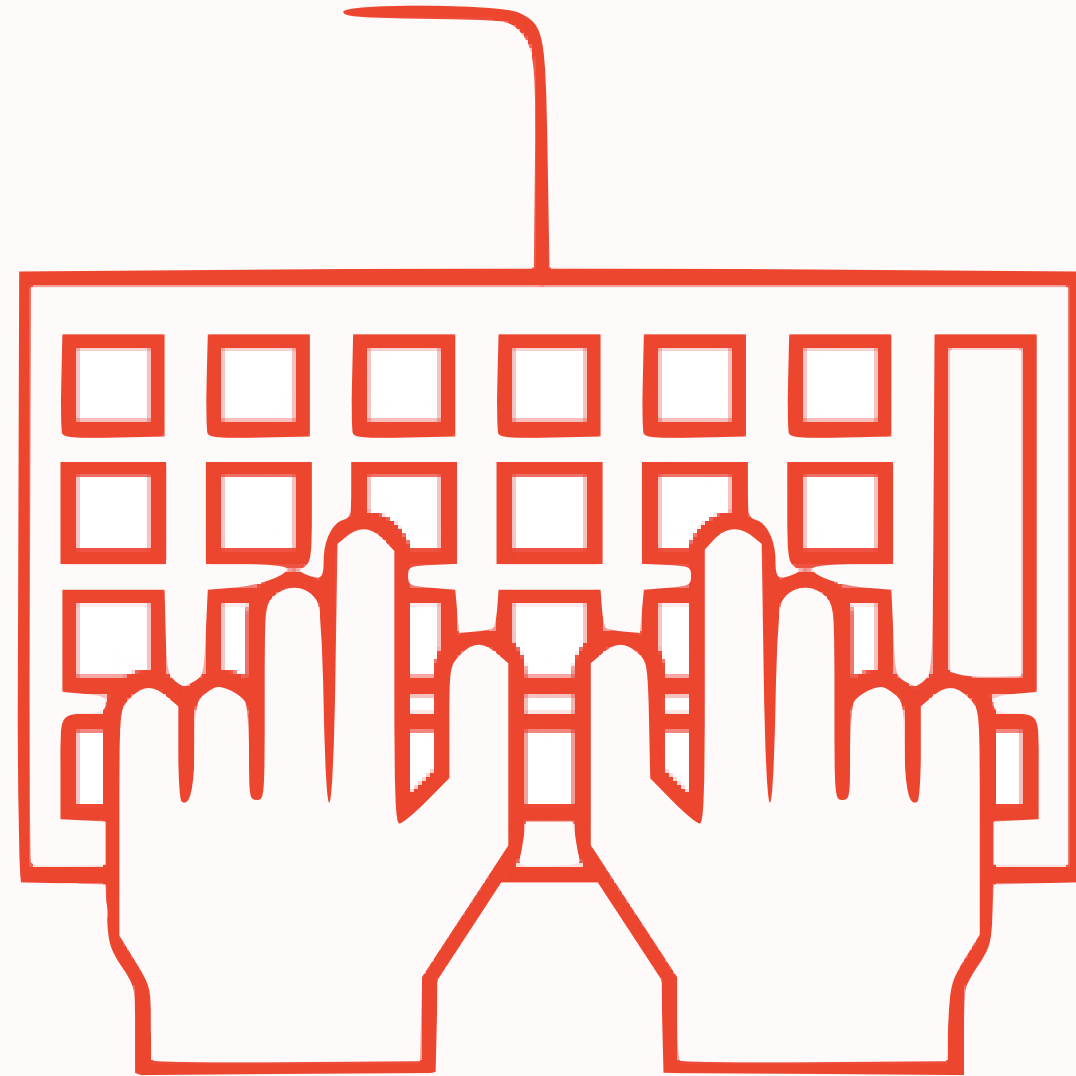
senza forzare la risposta,

senza commenti,

senza fretta



Completezza




E se la/il minore dice poco o nulla?



→ **NON** forzare la persona assistita

Descrivere nella documentazione sanitaria:

- Stato emotivo incongruente con la sintomatologia descritta
- Difficoltà a spiegare l'accaduto
- Presenza di “accompagnatore/i” interferente/i
- Ripetuti accessi in Pronto Soccorso



SEMEIOTICA

Sentinel injuries suggesting physical child abuse in infants and young children

Injury	Patient age					
	<6 months	6 to 12 months	1 year old	2 to 3 years old		
Soft tissue injury	Frenulum tears or unexplained oral injuries (teeth, lips, palate)	Frenulum tears or unexplained oral injuries (teeth, lips, palate)	Frenulum tears or unexplained oral injuries (teeth, lips, palate)	Frenulum tears or unexplained oral injuries (teeth, lips, palate)		
	Isolated subconjunctival hemorrhage outside of the newborn period					
	Any bruise	Unexplained bruises in non-cruising children			Bruises of the trunk, ear, neck, jawline, or cheek	Bruises of the trunk, ear, neck, jawline, or cheek
		Patterned bruising			Patterned bruising	Patterned bruising

Child Abuse—A Review of Inflicted Intraoral, Esophageal, and Abdominal Visceral Injuries

Daniel Ta Yo Yu, MB BCh,
Thuy L. Ngo, DO, MEd,
Mitchell Goldstein, MD, MBA

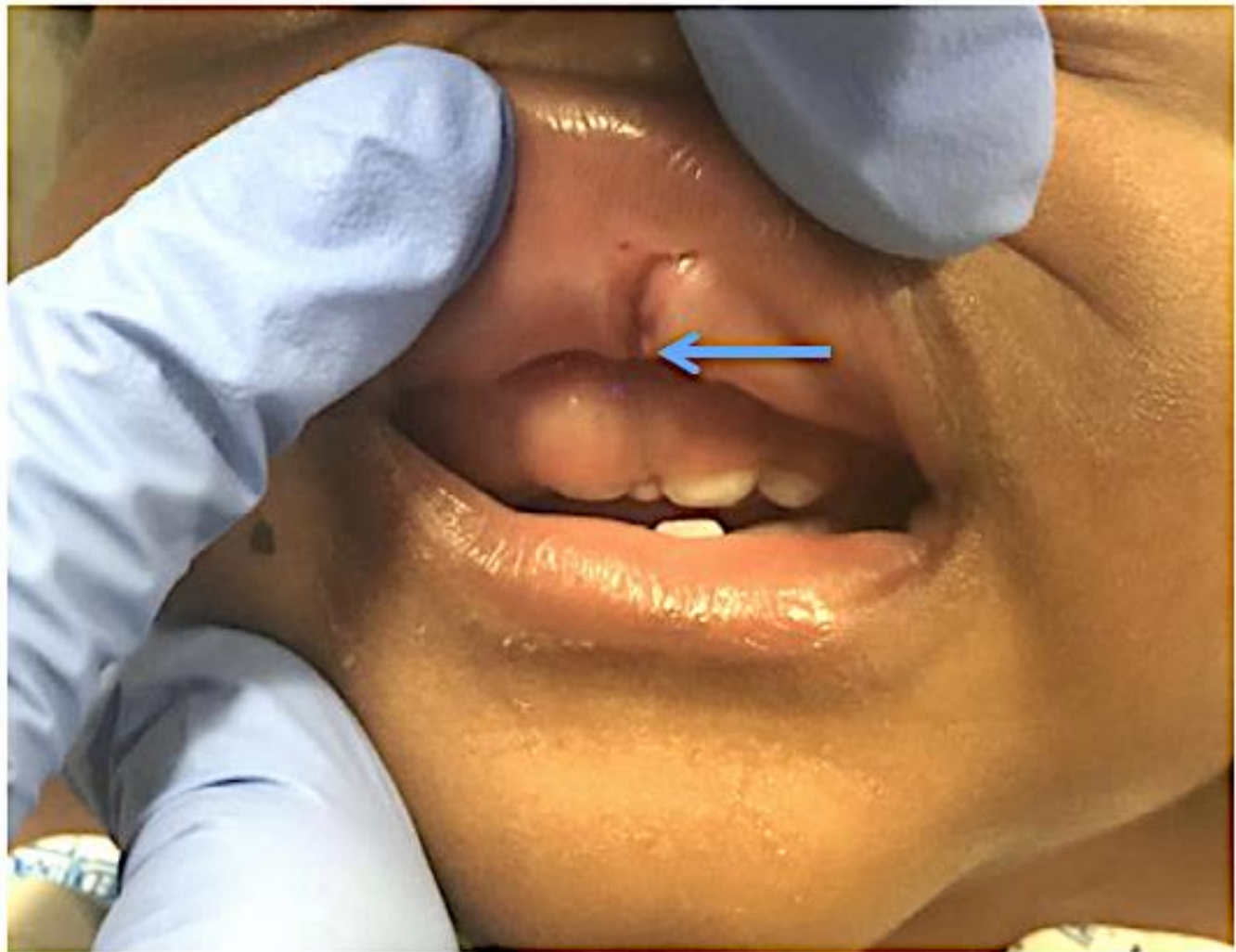

Figure 1. Torn labial frenulum (arrow) found in an 11-month-old child who presented with inflicted burn injury.

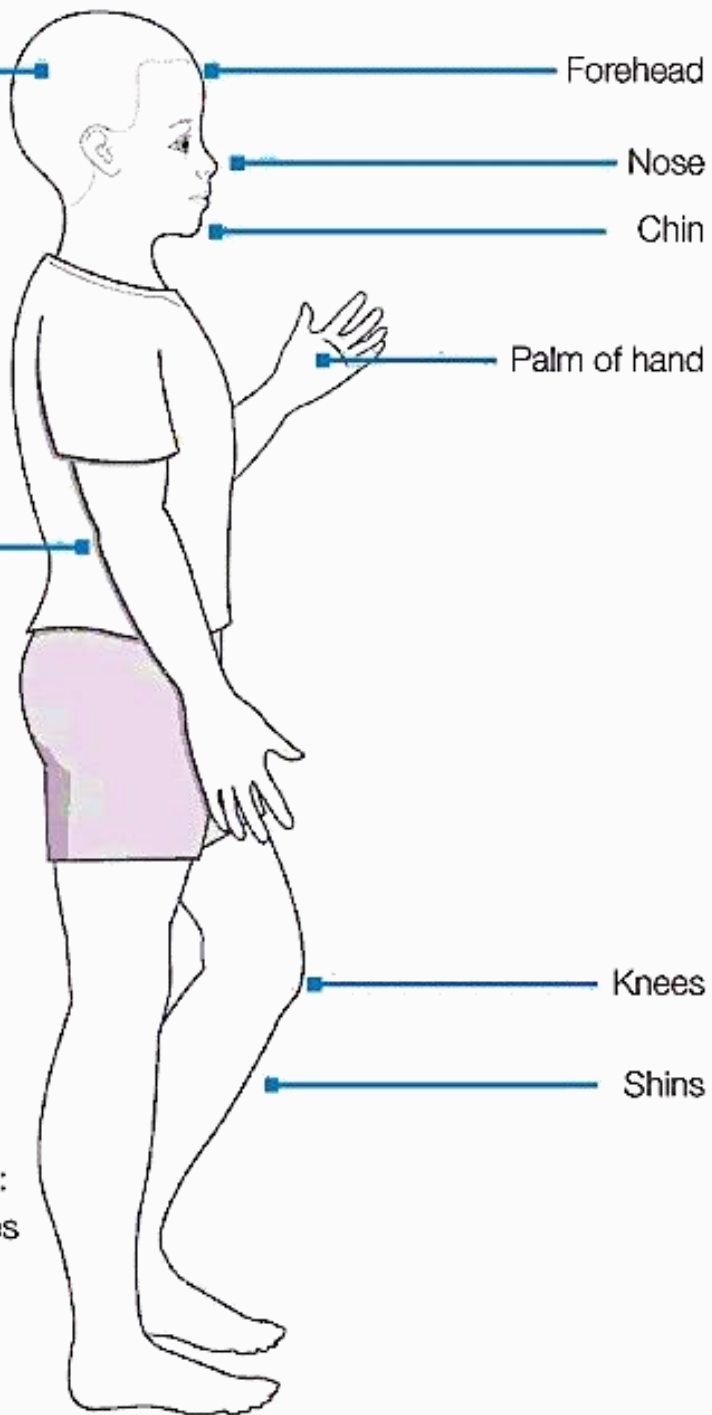
Clinical Pediatric Emergency Medicine 2016;17(4):284-295

Head injuries tend to involve the parietal bone, occiput or forehead

Elbows

REMEMBER

- Accidental injuries typically:
- involve bony prominences
 - match the history
 - are in keeping with the development of the child



Ears – especially pinch marks involving both sides of the ear

The “triangle of safety” (ears, side of face, and neck, top of shoulders): accidental injuries in this area are unusual

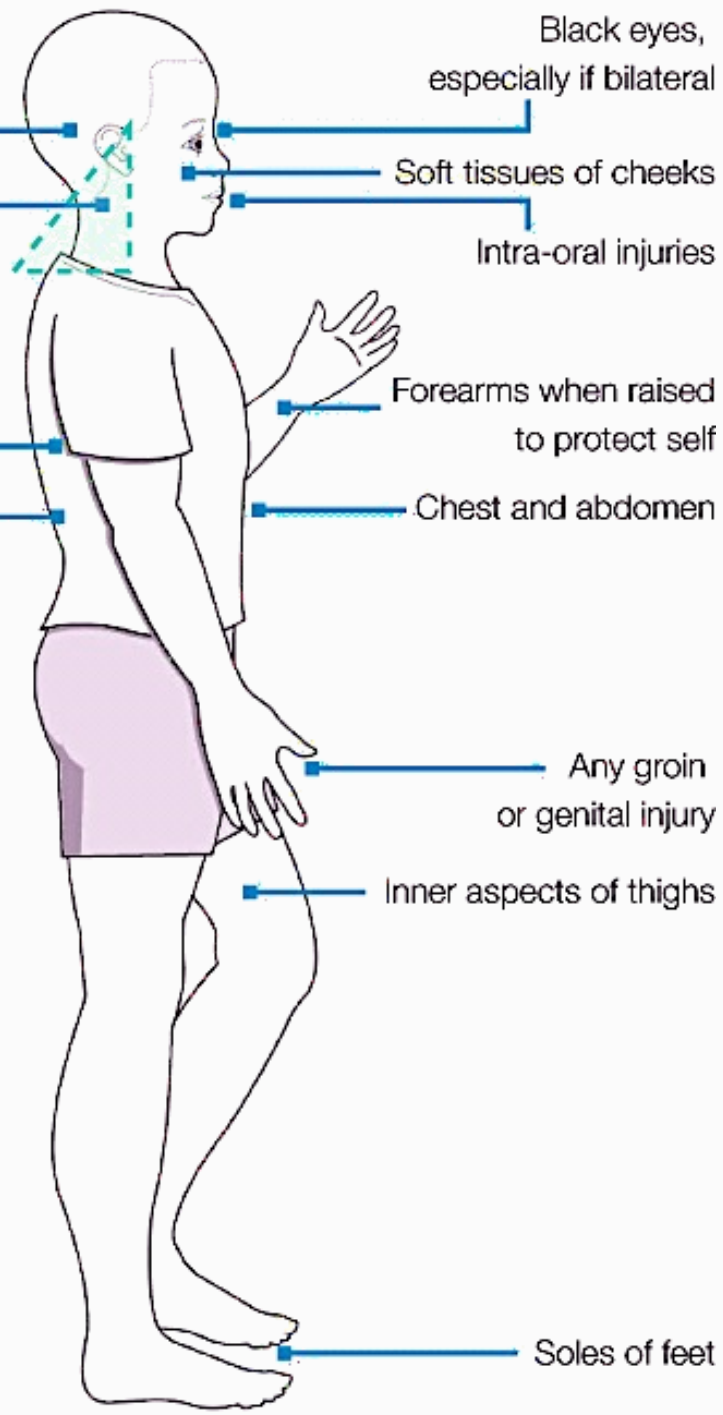
Inner aspects of arms

Back and side of trunk, except directly over the bony spine

REMEMBER

Concerns are raised by:

- injuries to both sides of the body
- injuries to soft tissue
- injuries with particular patterns
- any injury that doesn't fit the explanation
- delays in presentation
- untreated injuries



Bruising patterns that suggest child abuse

Marks from instruments

Belt buckle



Belt



Looped cord



Stick/whip



Fly swatter



Coat hanger



Board or spatula



Hand/knuckles



Bite



Sauce pan



Paddles



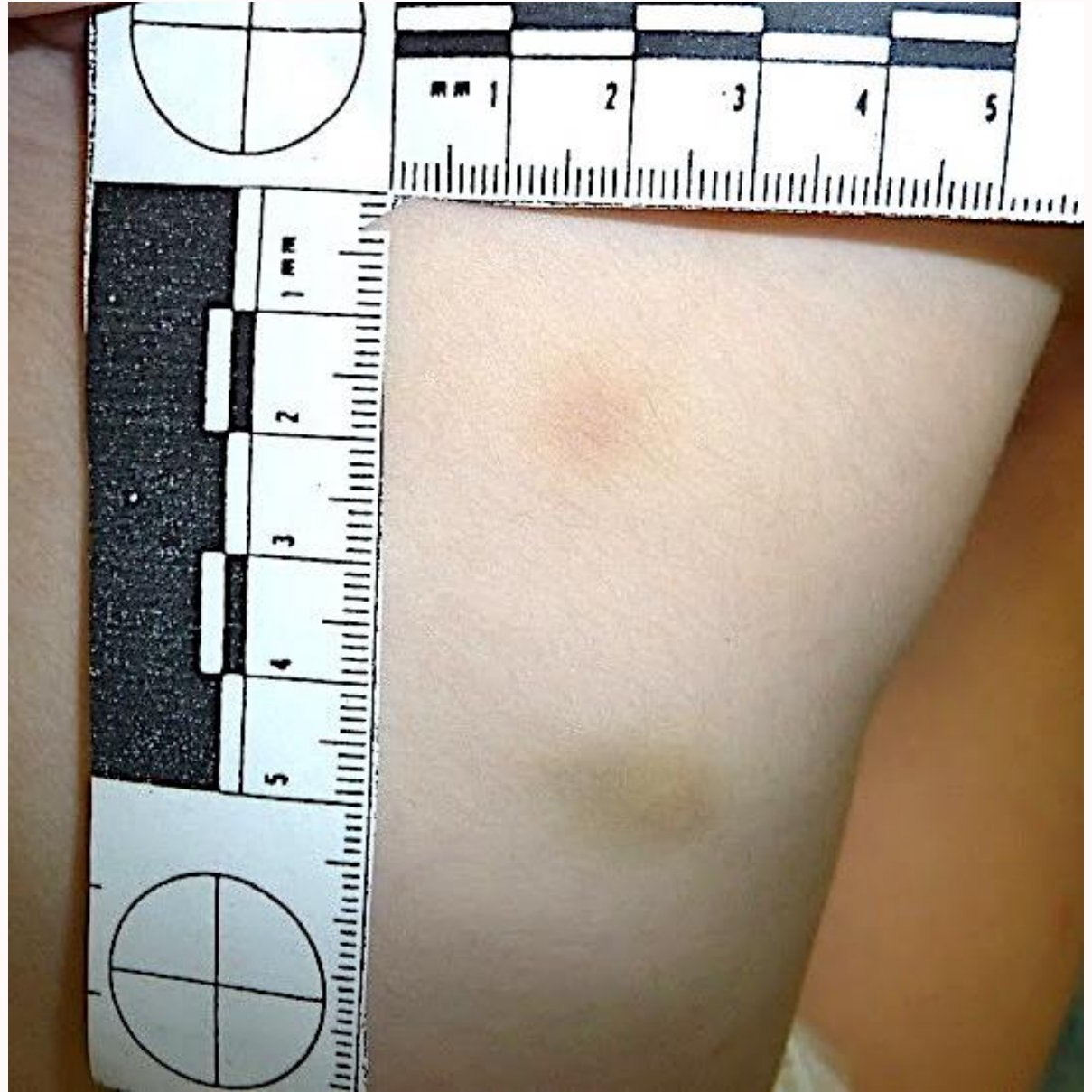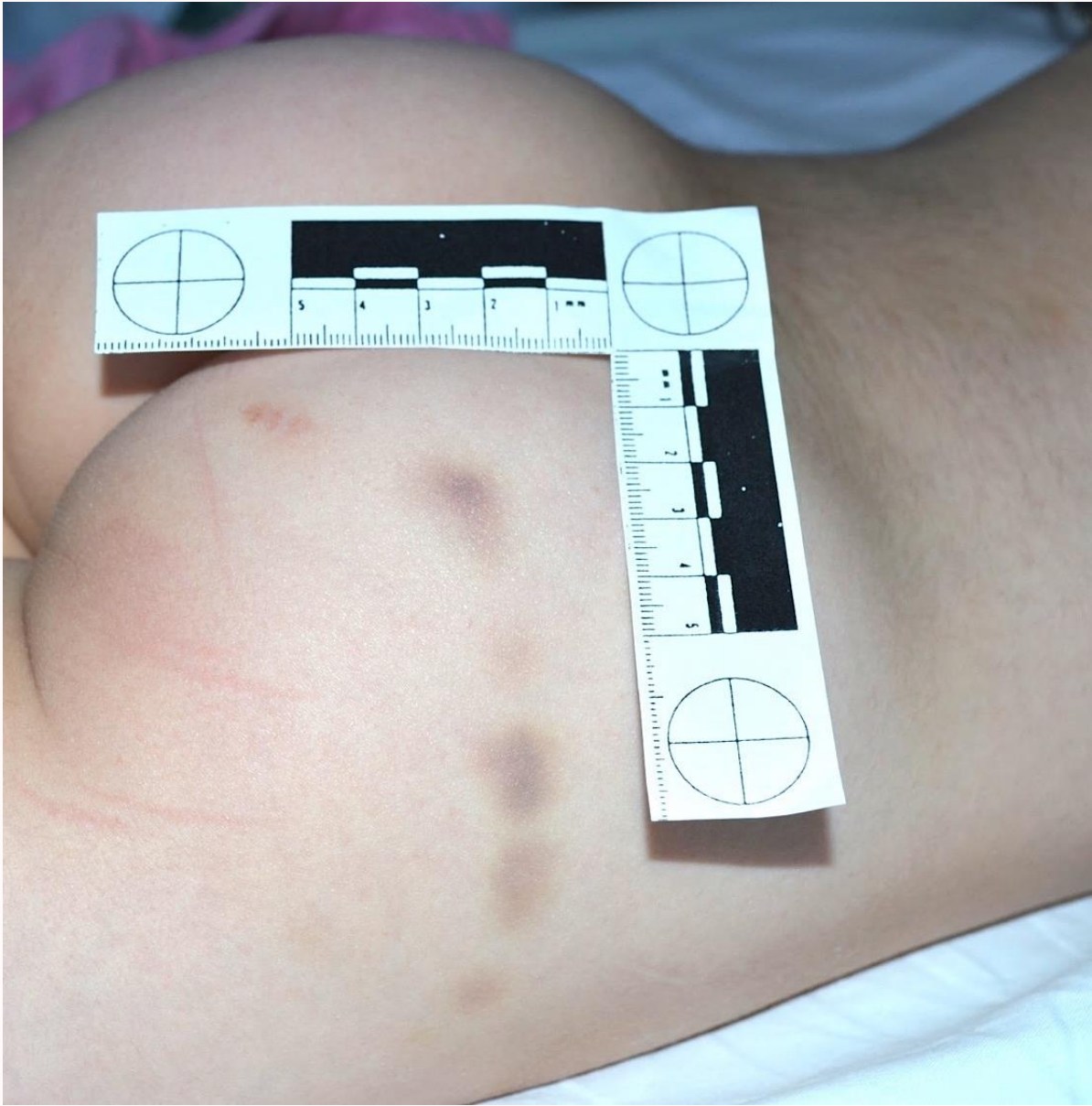
Hair brush

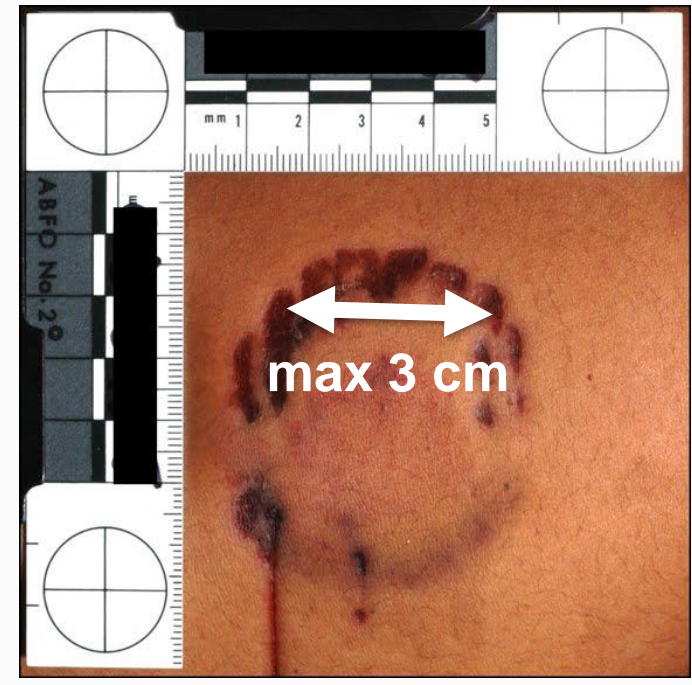
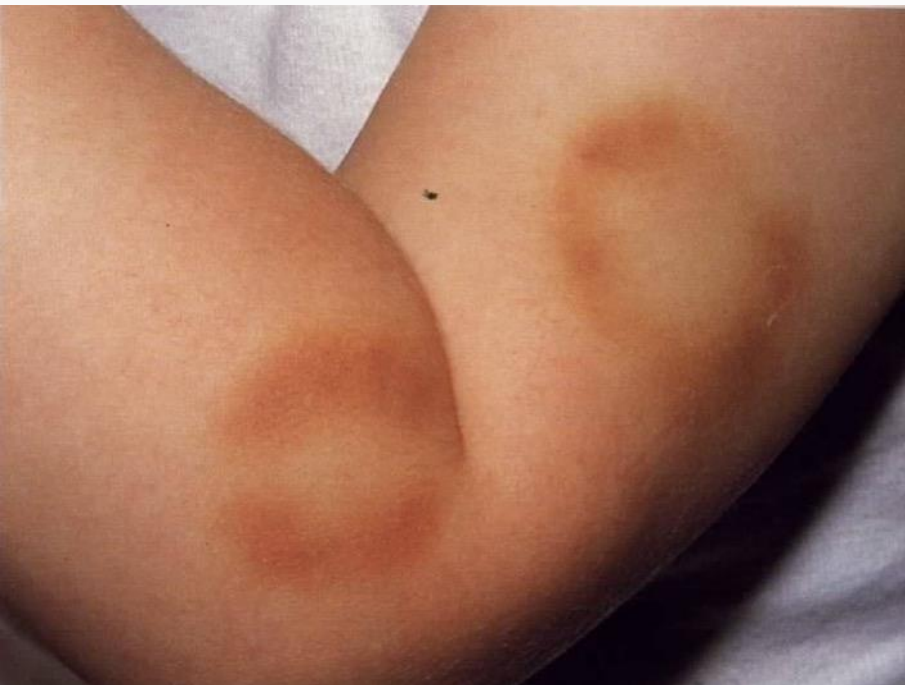
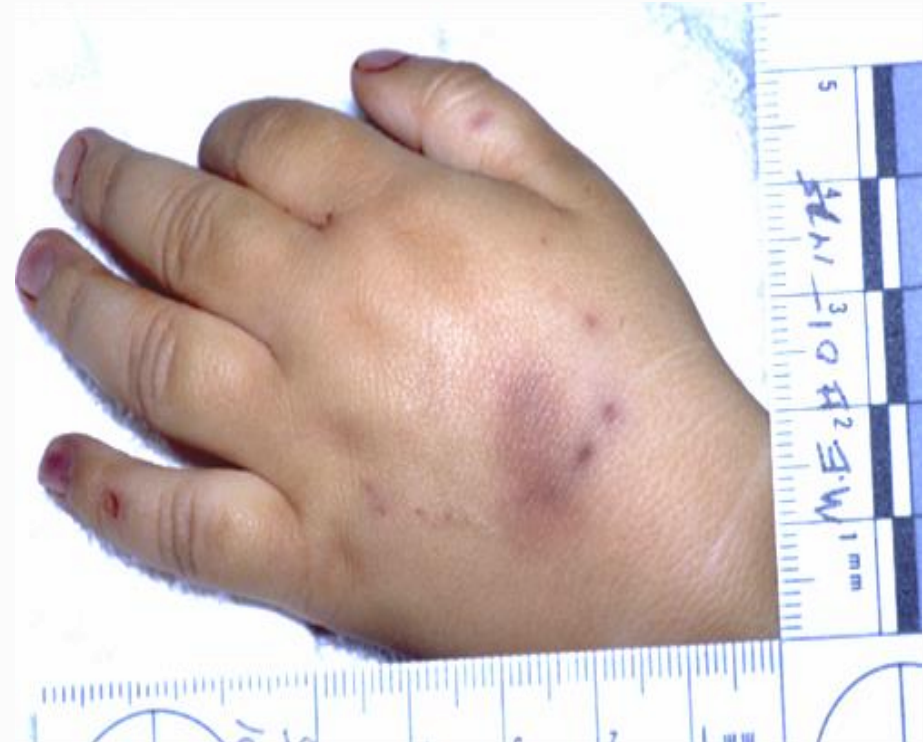
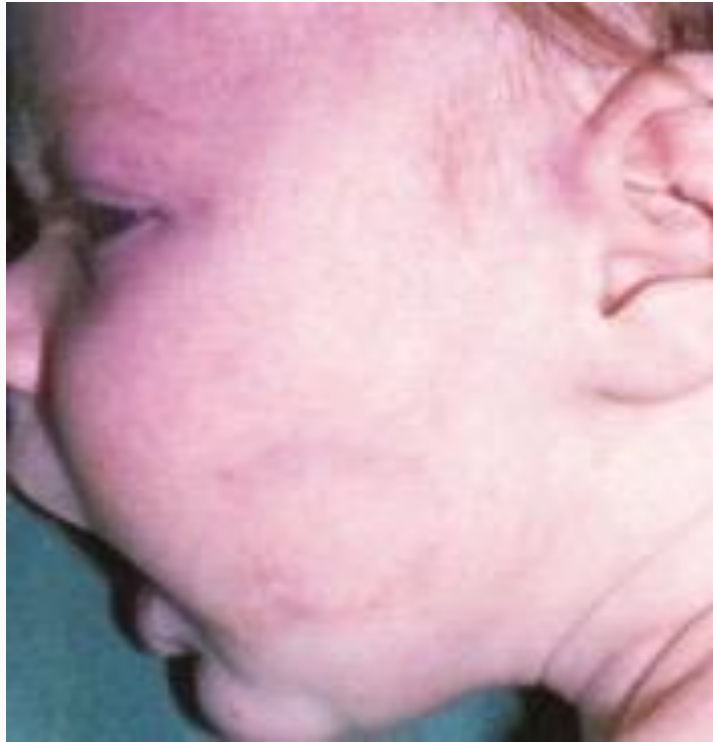Spoon

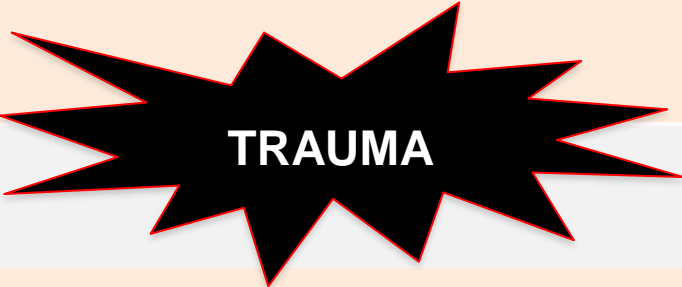






A variety of instruments may be used to inflict injury on a child. Often the choice of an instrument is a matter of convenience. Marks tend to silhouette or outline the shape of the instrument. The possibility of intentional trauma should prompt a high degree of suspicion when injuries to a child are geometric, paired, mirrored, of various ages or types, or on relatively protected parts of the body. Early recognition of intentional trauma is important to provide therapy and prevent escalation to more serious injury.





Ecchimosi



TEMPO

Sentinel injuries suggesting physical child abuse in infants and young children

Injury	Patient age			
	<6 months	6 to 12 months	1 year old	2 to 3 years old
Burns	Unexplained burns	Unexplained burns	Unexplained burns	Unexplained burns
	Burns in the shape of a heated object	Burns in the shape of a heated object	Burns in the shape of a heated object	Burns in the shape of a heated object
	Immersion burns	Immersion burns	Immersion burns	Immersion burns
	Burns of the perineum and lower extremities	Burns of the perineum and lower extremities	Burns of the perineum and lower extremities	Burns of the perineum and lower extremities

Contact burn patterns suggesting abuse

Burn marks

Hot plate



Light bulb



Curling iron



Car cigarette lighter




Steam iron



Knife



Grid



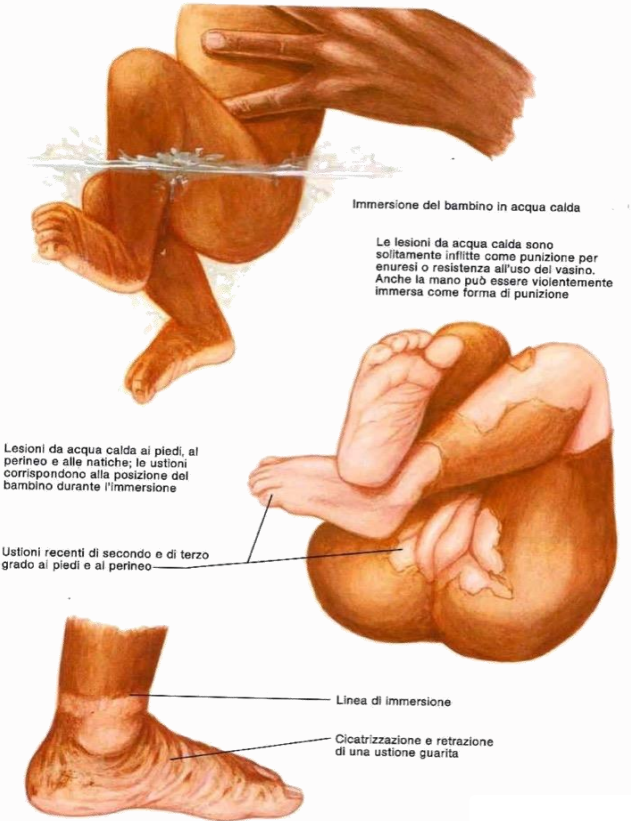
Cigarette



Forks



Immersion




Marks from heated objects cause burns in a pattern that duplicates that of the object. Familiarity with the common heated objects that are used to traumatize children facilitates recognition of possible intentional injuries. The location of the burn is important in determining its cause. Children tend to explore surfaces with the palmar surface of the hand and rarely touch a heated object repeatedly or for a long time.

Reproduced from: Dubowitz H, Lane WG. *Abused and neglected children*. In: Nelson's Textbook of Pediatrics. Kliegman RM, Stanton BF, St. Geme JW, Schor NF (Eds), 20th ed, Elsevier: Philadelphia, 2015. Illustration used with the permission of Elsevier Inc. All rights reserved.

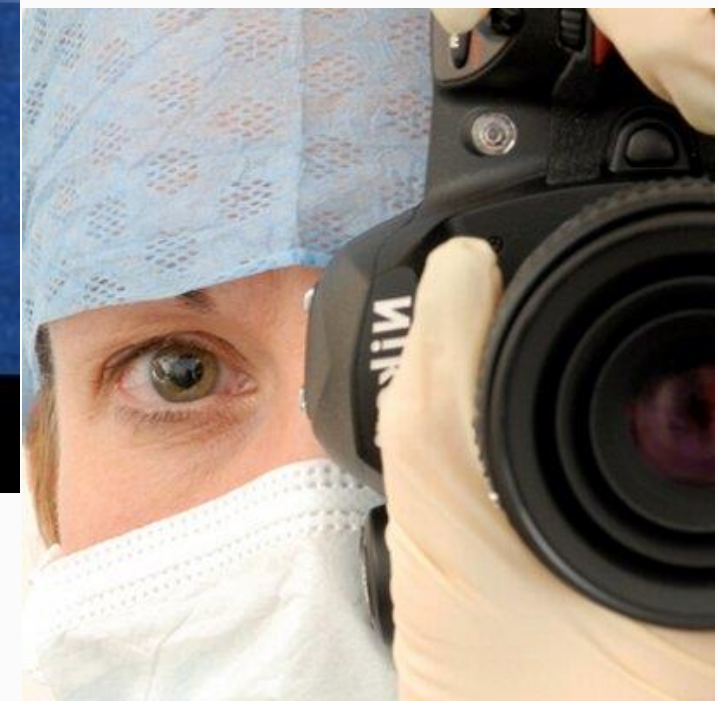Elementi da specificare per una corretta **descrizione** delle lesioni:

1. distretto corporeo specifico
2. tipo di lesione
3. colore
4. forma (aspecifica, specifica)
5. margini (netti, irregolari)
6. orientamento
(longitudinale, trasversale, obliquo)
7. dimensioni



Forensic Photography: Overview of Basic Principles for Health Care Professionals

William M. Green, MD, FACEP



Utility of Forensic Photography

- “A good photograph is tantamount to stopping the clock” ←
- When injuries have healed, photographs in the medical/forensic record provide visual documentation of the injuries
- Forensic photographs document visible evidence findings before they are disturbed or collected

Forensic Imaging for Non-Professional Photographers

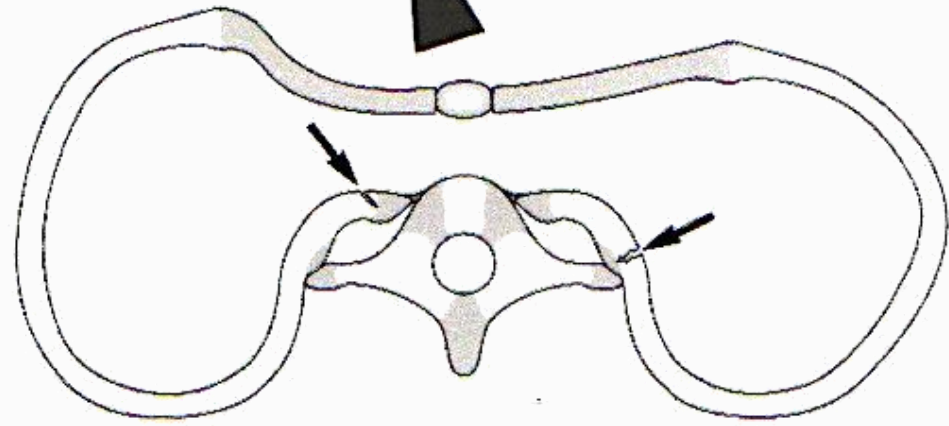
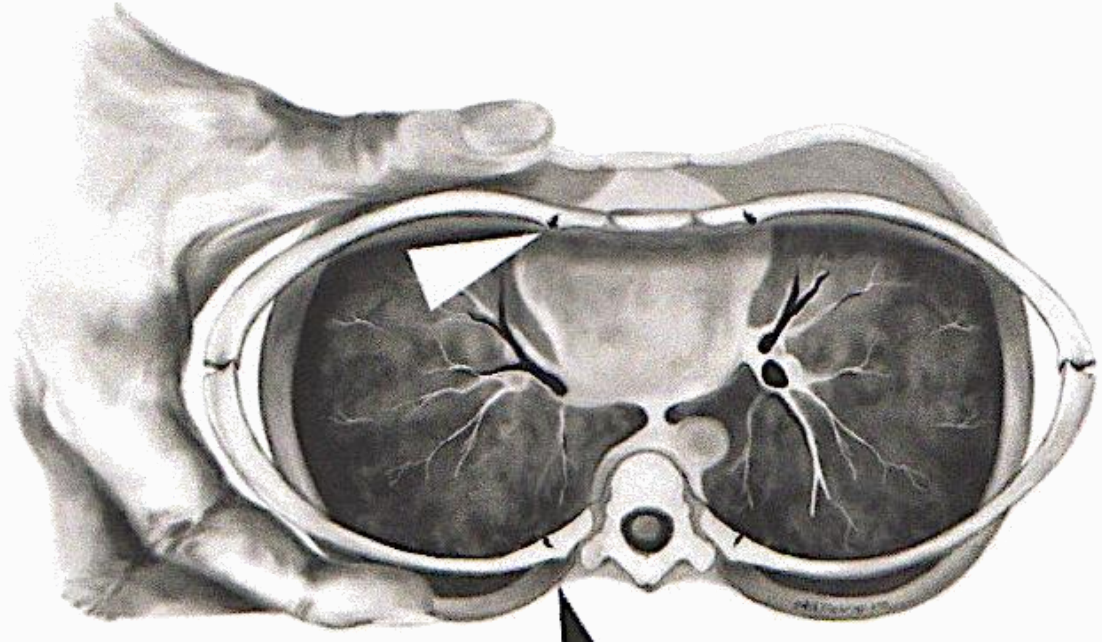
- Excellent quality forensic images are obtainable with a basic digital camera
- The more images, the better ←
- Basic equipment, skills and techniques will address most forensic photographic situations
- Practicing forensic photographic skills and techniques with mentoring and feedback is more productive than lectures about photographic theory and philosophy
- Equipment
- Camera

Sentinel injuries suggesting physical child abuse in infants and young children

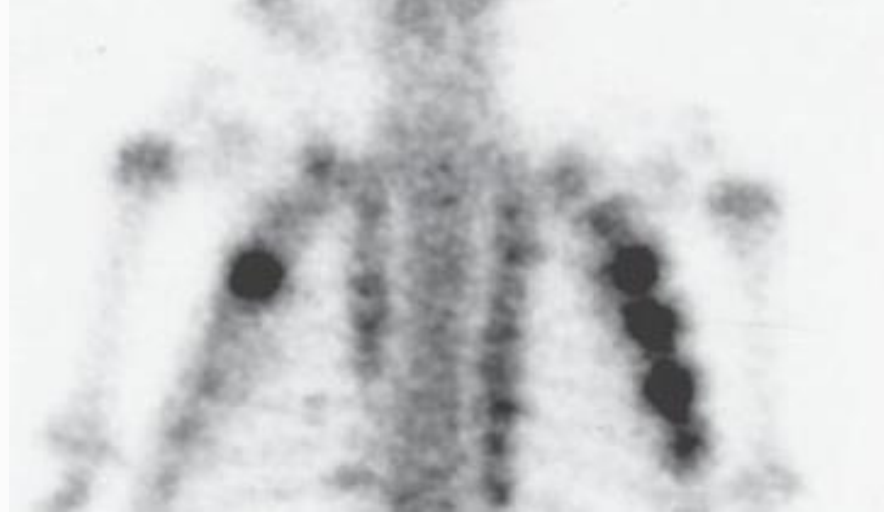
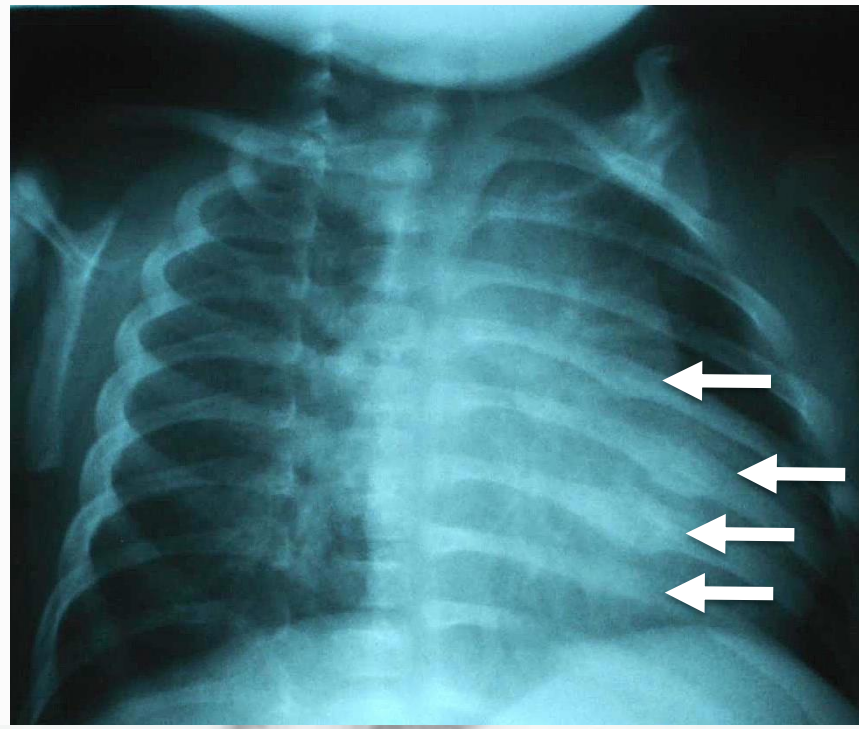
Injury	Patient age			
	<6 months	6 to 12 months	1 year old	2 to 3 years old
Fractures	Multiple fractures in different stages of healing	Multiple fractures in different stages of healing	Multiple fractures in different stages of healing	Multiple fractures in different stages of healing
	Any fracture other than skull or clavicle fractures in the newborn period	Any fracture other than skull fracture Skull fractures without history or other than simple linear parietal type	Any rib fracture Humerus fracture, other than supracondylar Fractures of other long bones Fracture without trauma history or presenting with evidence of healing	Fracture without trauma history or presenting with evidence of healing

Bambini ≤ 2 anni: fratture *highly specific*

costali (soprattutto posteriori)

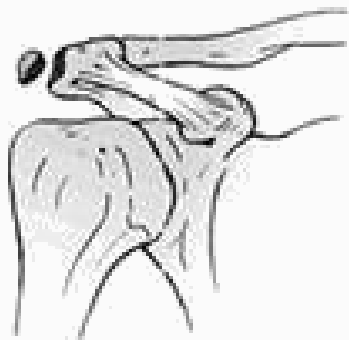

Kleinman et al., 1997, Lonergan et al., 2003

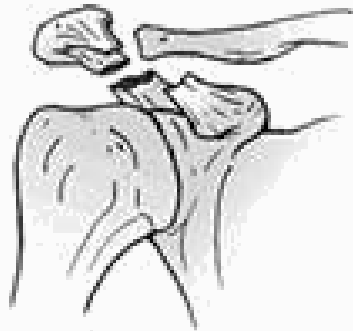

Bambini ≤ 2 anni: fratture *highly specific*

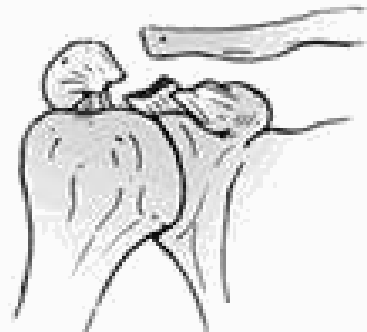distacchi avulsivi dell'acromion



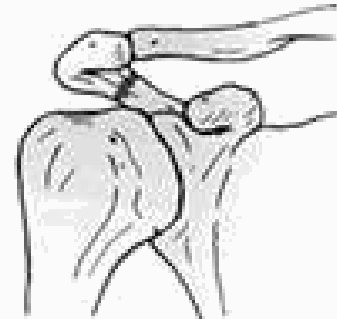Type IA



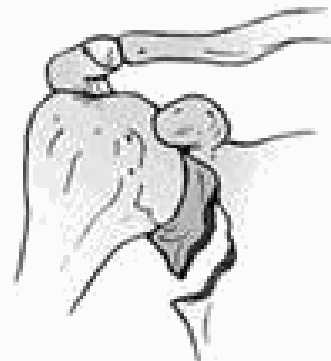Type II



Type III



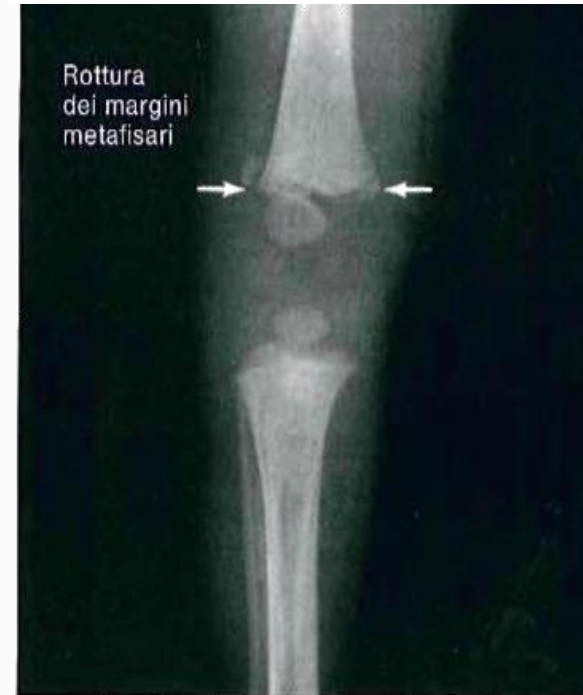Type IB



Type III

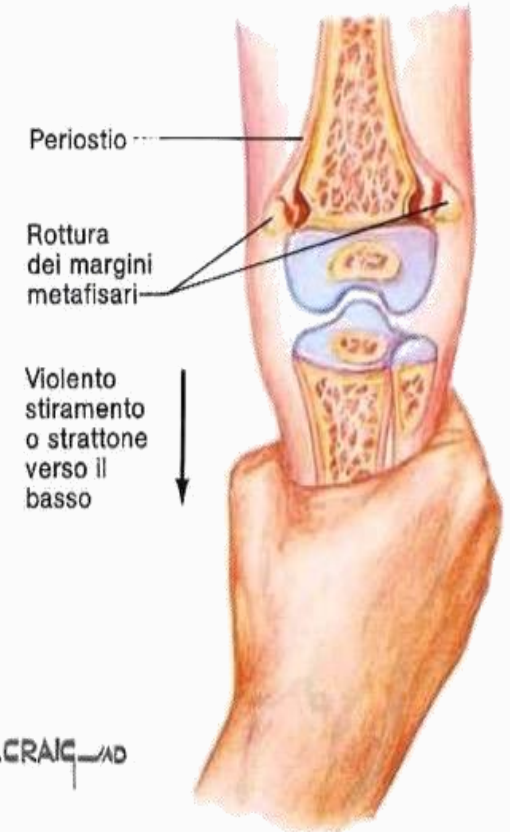fratture meta-epifisarie

Nei bambini ai primi passi possono verificarsi delle fratture a spirale nelle estremità inferiori; nei bambini che ancora non camminano tali lesioni sono rare e suggeriscono una violenza



Lesione metafisaria provocata da uno strappo all'estremità

Lesione metafisaria



Avulsione dei margini metafisari
opera delle connessioni periosteali erenti

JOHN A. CRAIG, MD
© CIBA

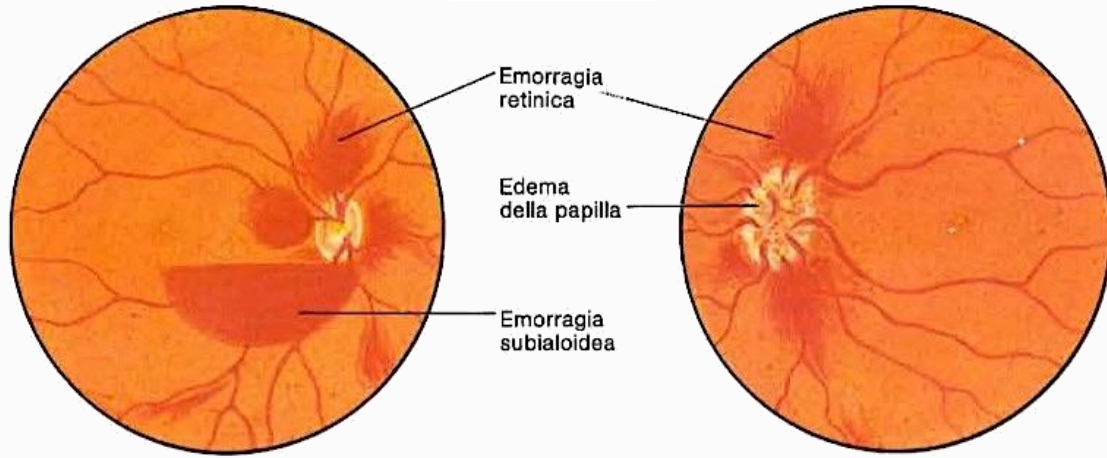
Sentinel injuries suggesting physical child abuse in infants and young children

Injury	Patient age			
	<6 months	6 to 12 months	1 year old	2 to 3 years old
Intracranial	Any subdural hemorrhage/hygroma	Any subdural hemorrhage/hygroma	Unexplained subdural hematoma without history of high-energy trauma (eg, motor vehicle collision, long-distance fall)	
Visceral injury	Any visceral injury	Any visceral injury	Traumatic visceral injury unexplained by motor vehicle collision or verified history of accidental high-energy blow to the abdomen*	

In the absence of significant, independently verified trauma mechanisms like motor vehicle collisions, the listed injuries by age should prompt further evaluation for physical child abuse. Other injuries not listed may also warrant further investigation. Refer to UpToDate content on recognition of physical child abuse.

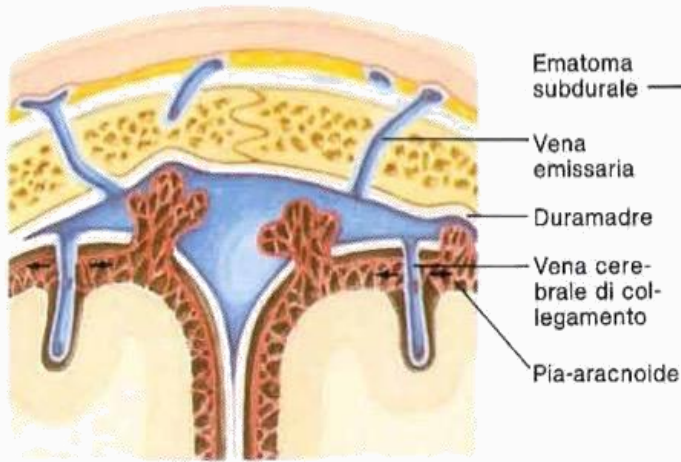
* Proximal hollow-viscus and pancreatic injuries are more common in abuse than accidental trauma in young children and justify additional scrutiny of the given history.

Visione fundoscopica

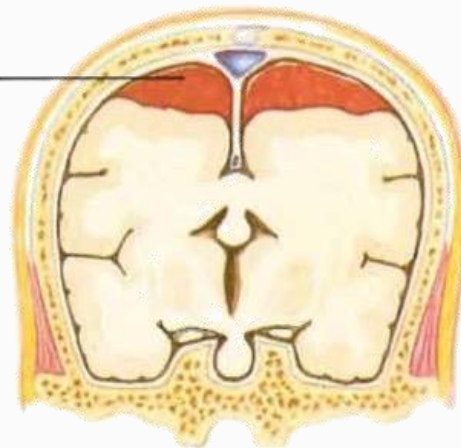


Nei bambini piccoli, le emorragie retiniche e subialoidi accompagnano il sanguinamento subdurale

Nei bambini più grandi, un chiaro edema della papilla può accompagnare una aumentata pressione intra-cranica a causa di sanguinamento subdurale



Nei bambini, le vene cerebrali di collegamento sono poco protette quando passano attraverso lo spazio subdurale. Uno scuotimento violento può provocare la rottura di vene vulnerabili, creando un ematoma subdurale

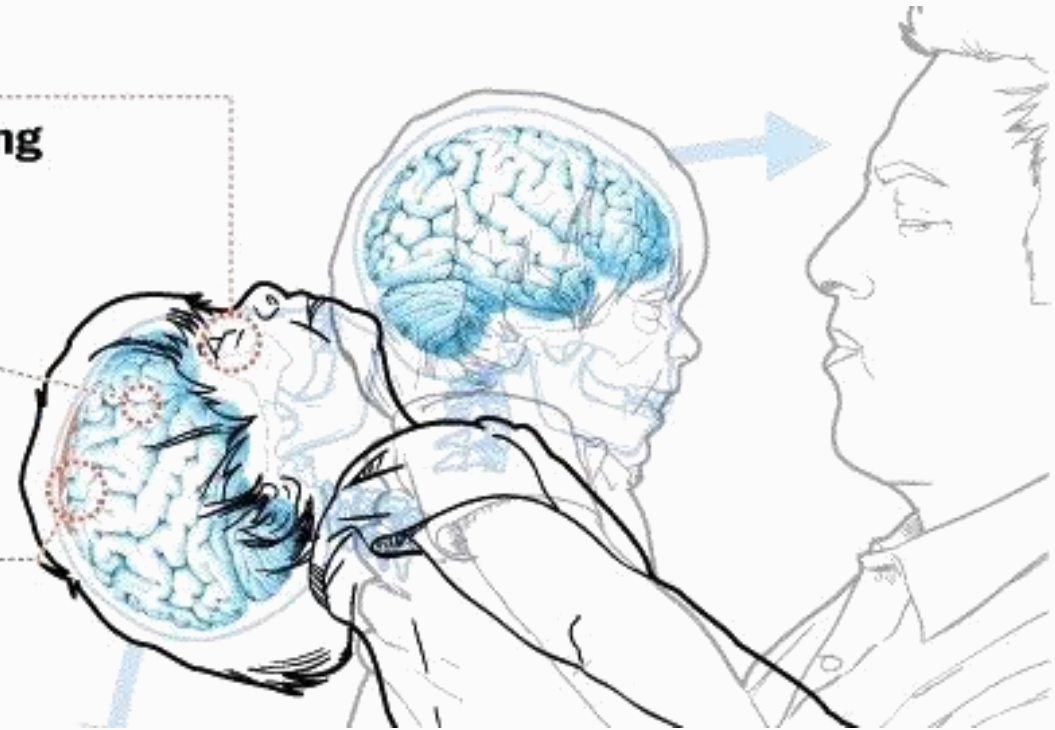


Un ematoma bilaterale subdurale, con o senza frattura cranica, può essere la conseguenza di lesioni craniche. Convulsioni o coma possono essere i primi segni clinici

Retinal hemorrhaging

Brain swelling

Subdural hematoma



Anogenital findings specific for trauma in the evaluation of child sexual abuse*

Moderate specificity for abuse

Acute lacerations or extensive bruising of the labia, peri-hymenal tissues, scrotum, or perineum (may be from unwitnessed accidental trauma)

Scar of posterior fourchette (the assessment of scars is difficult unless there was documentation of acute injury at the same site)

Fresh laceration of the posterior fourchette, not involving the hymen (must be differentiated from dehisced labial adhesion or failure of midline fusion; may be caused by accidental injury)

Perianal scar not in the midline (the assessment of scars is difficult unless there was documentation of acute injury at the same site; may be due to other medical conditions such as Crohn's disease, or previous medical procedures)

High specificity for abuse

Acute laceration of the hymen (partial or complete) ←

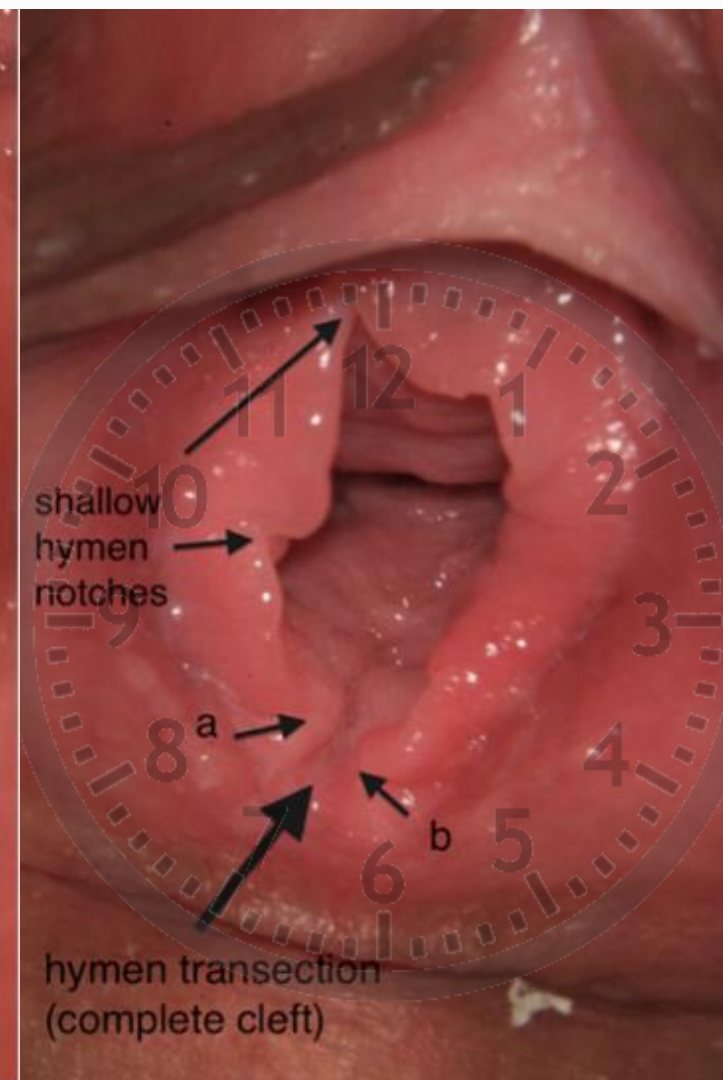
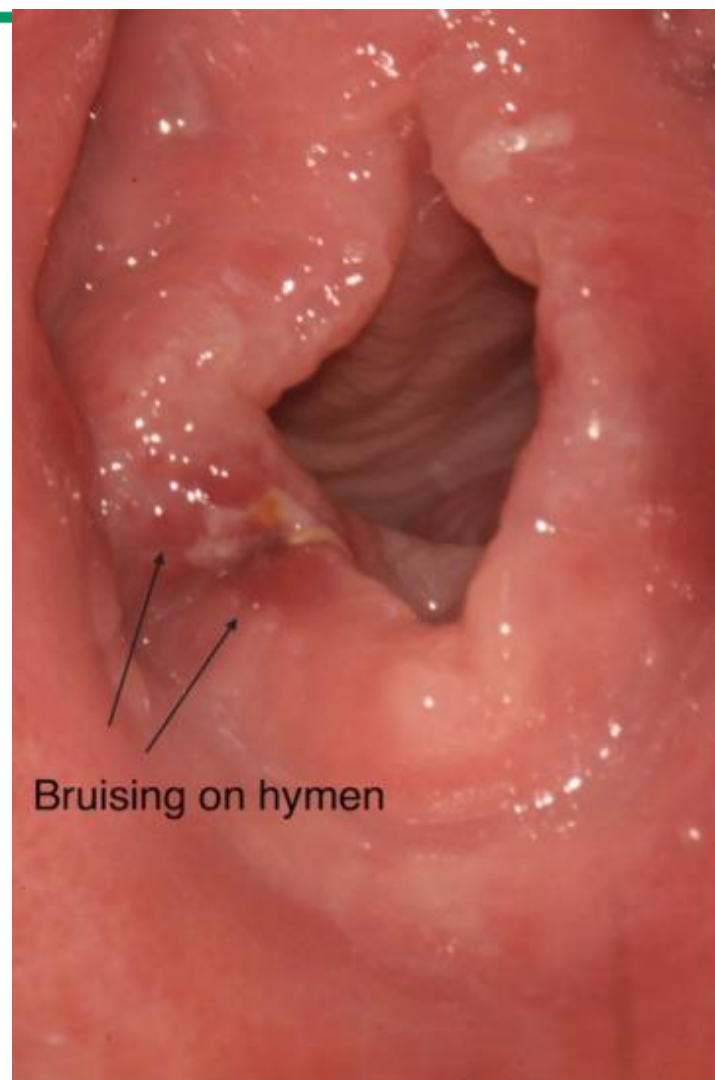
Echymosis (bruising) of the hymen ←

Perianal lacerations extending deep to the external anal sphincter (not to be confused with partial failure of midline fusion) ←

Hymenal transection (healed) (ie, an area where there is no hymenal tissue remaining between the vaginal wall and the fossa or vestibular wall [also called a complete cleft]. The finding should be confirmed using additional examination techniques such as a swab, prone knee-chest position, Foley catheter, water to float the edge of the hymen)

Absence of hymenal tissue (wide areas in the posterior/inferior half of the hymenal rim with an absence of hymenal tissue, extending to the base of the hymen, which is confirmed using additional positioning or other methods)

NB: segni **assenti** in ~90% dei casi!



*Findings which, in the absence of a clear, timely, plausible history of accidental injury, should be reported to child protective services.

Adapted from Adams, JA. Medical evaluation of suspected child sexual abuse. *J Pediatr Adolesc Gynecol* 2004; 17:191.



Un atto intenzionale
o una mancanza di azione

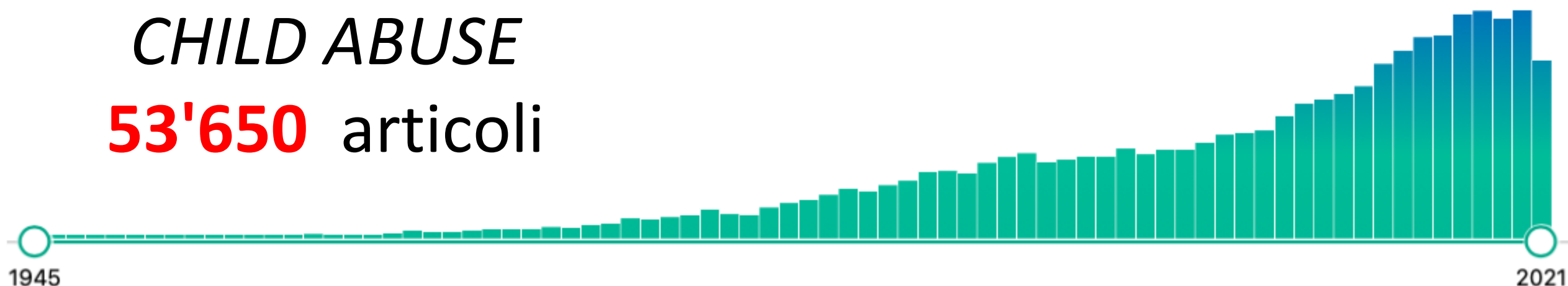
da parte di un *caregiver*
o di un'altra persona
in una relazione che implica
un'aspettativa di fiducia,

che crea un rischio o causa
un danno a un anziano

Hall J, Karch DL, Crosby A. Elder abuse surveillance:
Uniform definitions and recommended core data elements.
National Center for Injury Prevention and Control,
Division of Violence Prevention. 2016

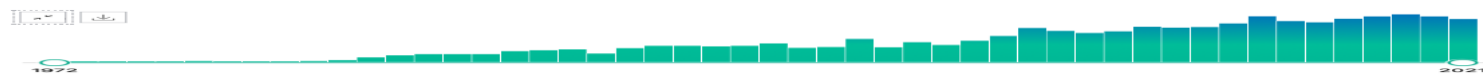CHILD ABUSE

53'650 articoli



ELDER ABUSE

3'275 articoli



History and warning signs for elder mistreatment/abuse

History

Advanced age (>80 years)

Disability in self-care

Dementia ←

Depression

History of hip fracture

History of stroke

Social isolation

Poor socioeconomic status ←

External family stressors

Unfavorable caretaker characteristics*

Indicators of financial exploitation ¶

Institutional staffing shortages

Inappropriate or excessive medications; failure to get needed medications; lack of appropriate monitoring of medications and their effects

Substance abuse



* Unfavorable caretaker characteristics: mental illness, substance abuse, history of violent or antisocial behavior, depression, or financial dependency on the victim.[1,2]

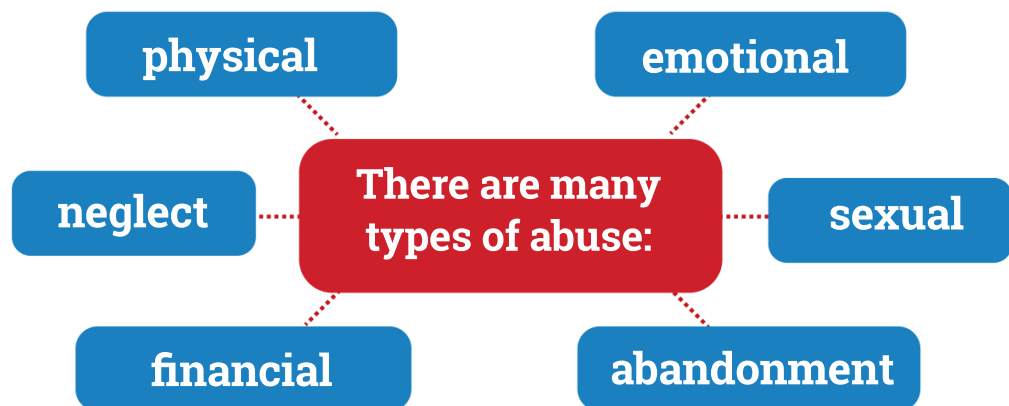
¶ Indicators of financial exploitation: inability to pay for services (utilities, rent, medications, food) that the older adult was previously able to pay for. Transfers of property when the older adult lacks the capacity to consent.[3]

References:

1. Lachs MS, Pillemer K. Elder abuse. *Lancet* 2004; 364:1265.
2. Lachs MS, Pillemer K. Abuse and neglect of elderly persons. *N Engl J Med* 1995; 332:437.
3. Reed K. When elders lose their cents: Financial abuse of the elderly. *Clin Geriatr Med* 2005; 21:365.

SPOTTING THE SIGNS OF ELDER ABUSE

Abuse can happen to any older person, by a loved one, a hired caregiver, or a stranger. Abuse can happen at home, at a relative's home, or in an eldercare facility.



Watch for these signs of abuse:



- ▶ Seems **depressed, confused, or withdrawn**



- ▶ **Isolated** from friends and family



- ▶ Has **unexplained bruises, burns, or scars**



- ▶ Appears **dirty, underfed, dehydrated, over- or undermedicated**, or not receiving needed care for medical problems



- ▶ Has **bed sores** or other preventable conditions



- ▶ Recent **changes in banking or spending** patterns

Physical/mental status examination

Indicators of sexual abuse: pain, bruises, lacerations, bleeding in anal-genital areas; bruised breasts or abdomen; signs of venereal diseases

Lacerations (including large skin tears, abrasions, burns, and bruises) without adequate explanation, especially on the trunk or other unusual locations

Suspicious fractures in sites other than those seen in osteoporotic fractures, ie, wrist, hip, or vertebral body

Malnutrition

Focal findings on neurologic examination

Signs of dehydration

Pressure ulcers

Dementia, psychiatric disorders, lack of mental capacity



CONSULTO / INVIO

Quando?

- Caso dubbio/sospetto

Perché?

Valutazione

multi-professionale (!)

Diagnostica per immagini,
laboratorio, ...

Valutazione sociale,
attivazione serv. territoriali



Grandi ospedali

Servizi Assistenza Sociale

(valutazioni su minore e famiglia)

SEGNALAZIONE

Quando?

- Situazione di pregiudizio per il minore
- Necessità di provvedimenti giudiziari sulla responsabilità genitoriale.

Come?

Per iscritto

A chi?

Procura presso il Tribunale per i MINORENNI.



**Tribunale per i Minorenni
(Brescia)**

(provvedimenti per il minore)

DENUNCIA

Quando?

- Reato procedibile d'ufficio.

Come?

Per iscritto.

A chi?

Forze dell'Ordine

Procura presso il Tribunale ORDINARIO (maggiorenni).



**Tribunale Ordinario
(Bergamo)**

(provvedimenti verso gli abusanti)

Casi *clinici* → studio/aggiornamento

**No domande intrusive
o suggestive**

**Precisione e dettaglio nelle
rilevazioni e registrazioni**

**Approccio collegiale
sanitario-sociale-giudiziario**