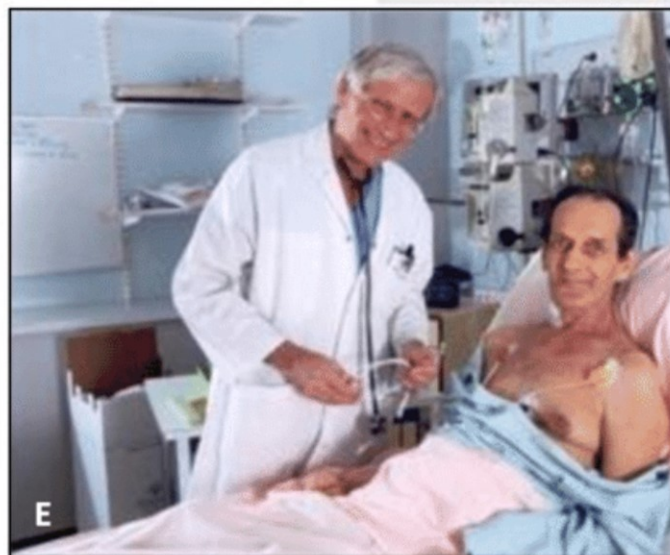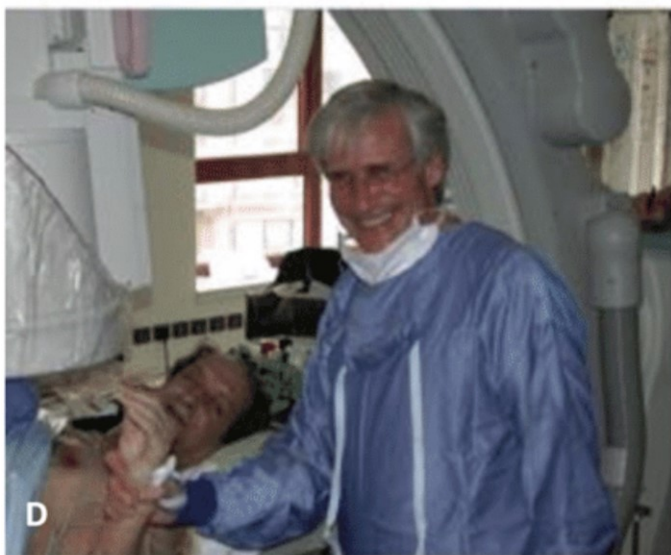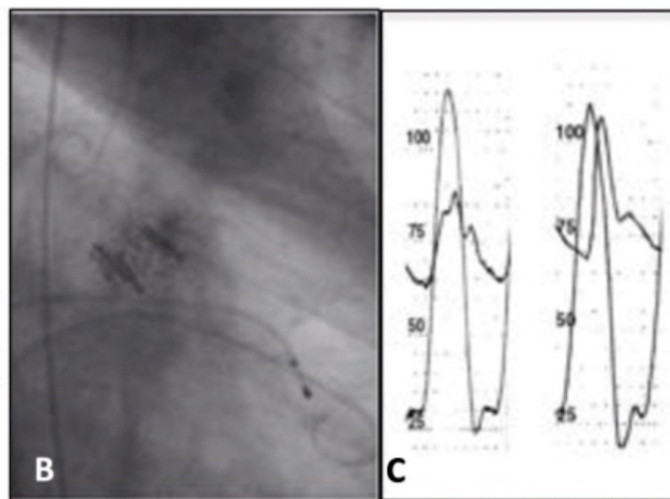


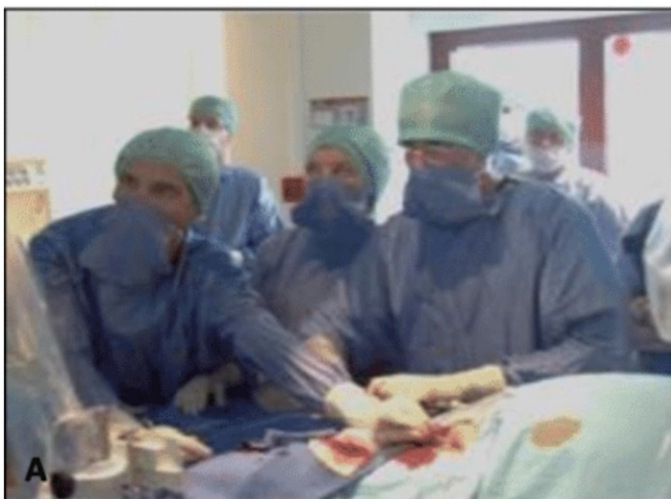

Procedura TAVI: Dalla teoria alla pratica

Dott.ssa Alessia Azzano

First-in-Man implantation (Rouen, April 16th, 2002)

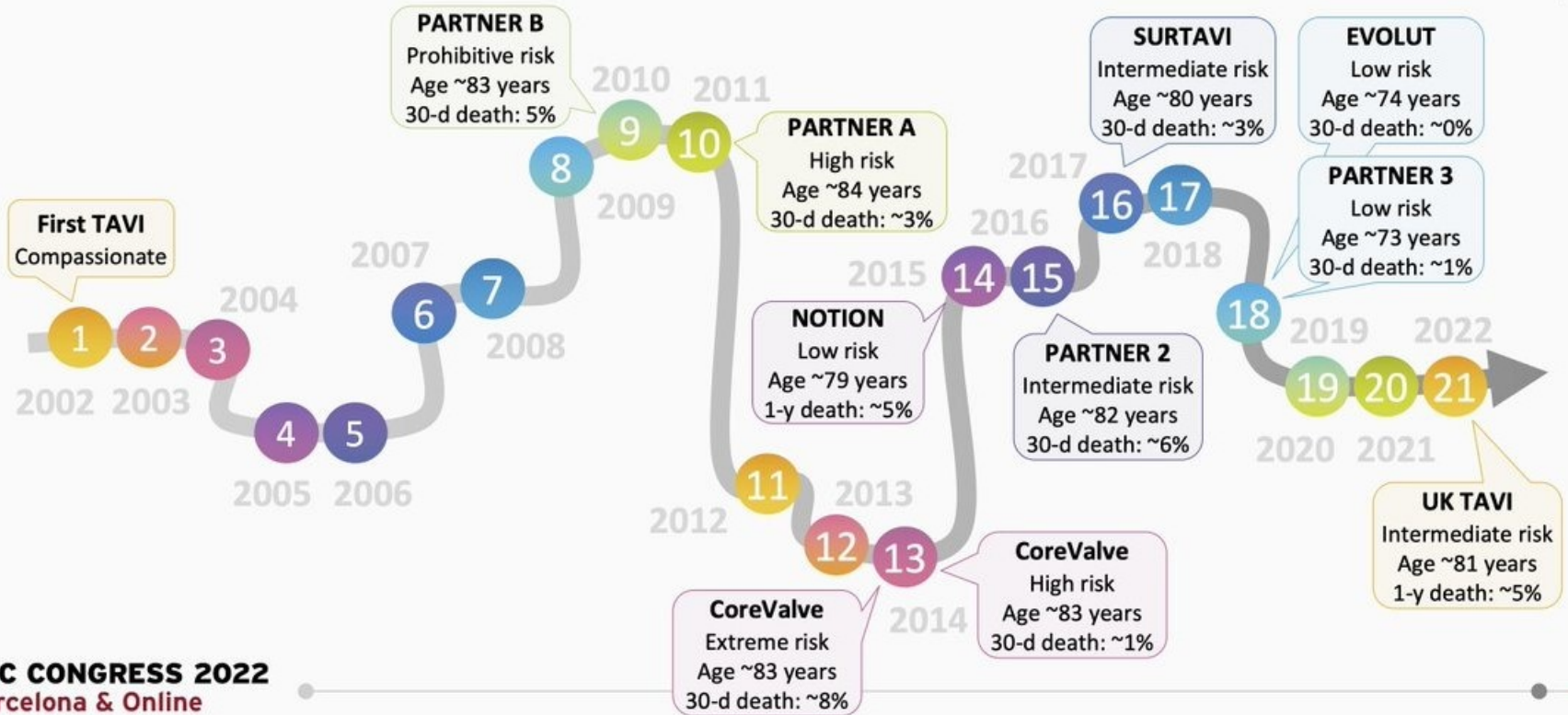


Twenty years of TAVI (2002-2022)

First cases

Focus on procedural complications

Focus on long-term outcomes



ESC CONGRESS 2022
Barcelona & Online

TAVI vs SAVR: META-ANALYSIS OF 7 RCT (N=8020 PTS)

SIONTIS ET AL. EUR HEART J 2019

2-year
All-cause
mortality

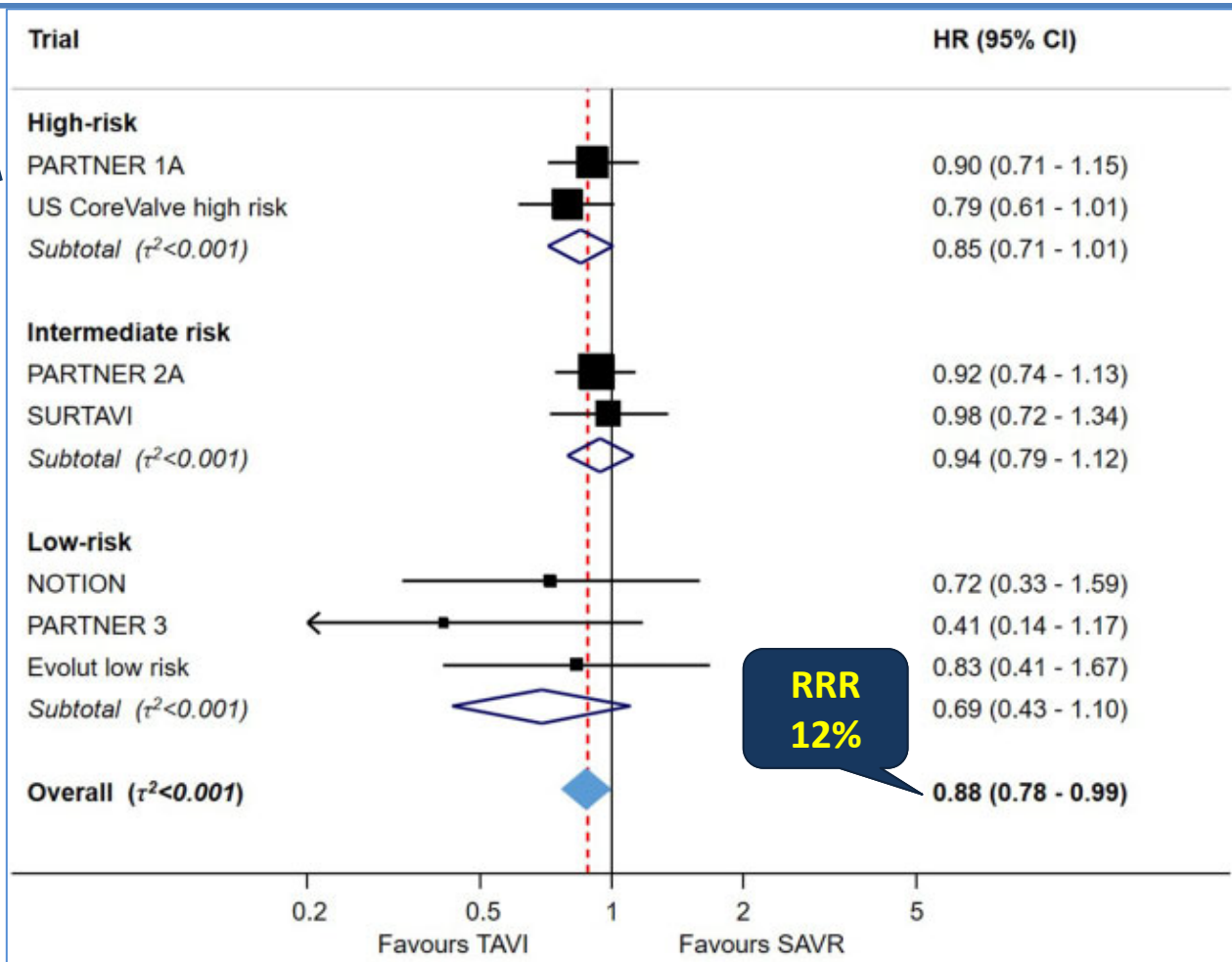
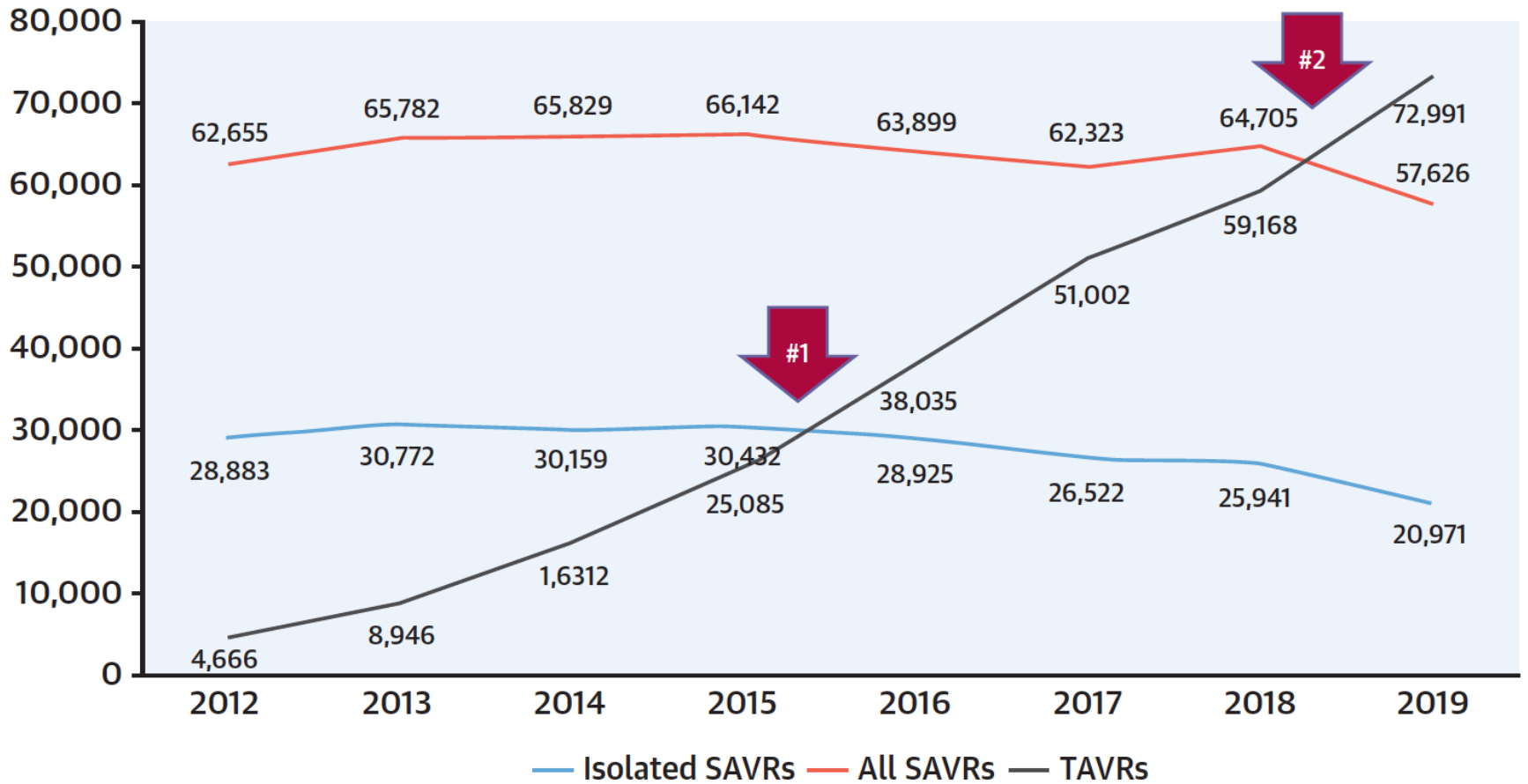


FIGURE 2 Annual Volumes of TAVR and SAVR

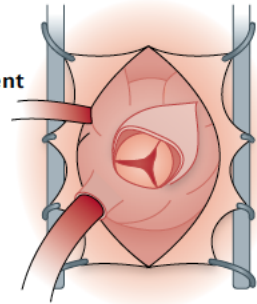


Carroll et al. JACC 2020 Nov 24;76(21):2492-2516

Evoluzione delle opzioni di AVR

Surgical aortic valve replacement

- Established in 1952
- Gold standard
- Requires open-heart surgery
- For mechanical and bioprosthetic valves



Transcatheter aortic valve replacement

- Established in 2002
- Minimally invasive
- Fast recovery
- For bioprosthetic valves

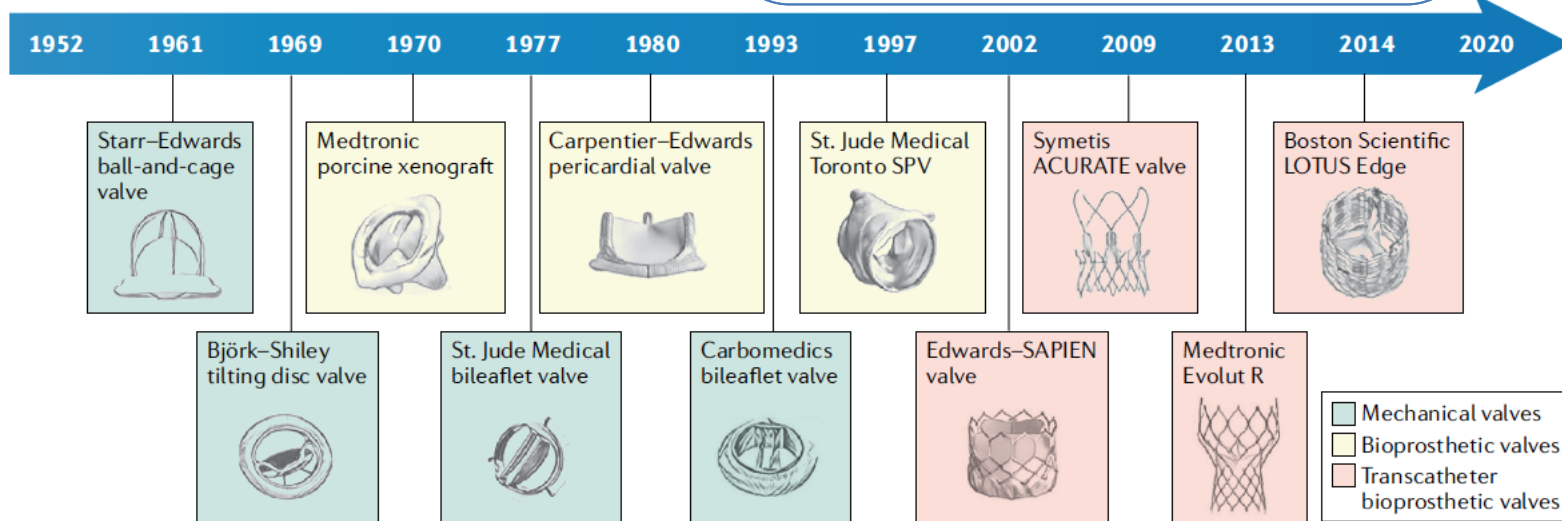
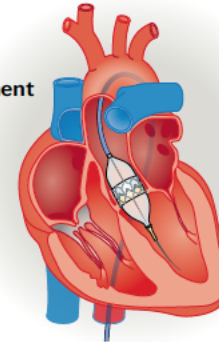
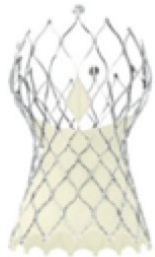

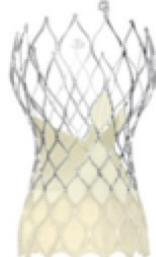Fig. 1 | **Evolution of heart valve replacement options.** Timeline of the introduction of mechanical and (transcatheter) bioprosthetic aortic valves. SPV, stentless porcine valve. Adapted with permission from REF.²⁴, EMH Swiss Medical Publishers Ltd.

Fioretta et al., Nature reviews Feb 2021

THV bioprotesi



Evolut R



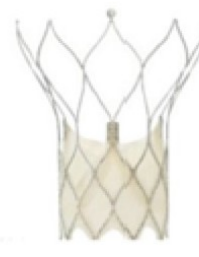Evolut Pro



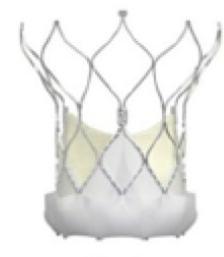ACURATE neo



ACURATE neo 2



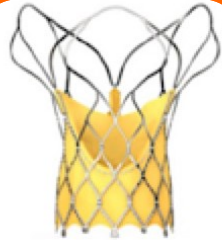Portico



Navitor



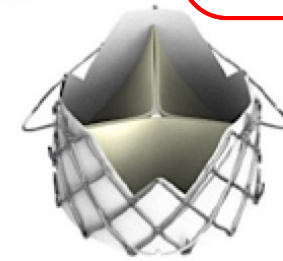
Myval



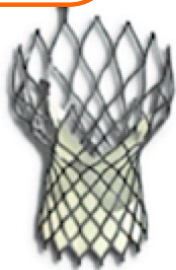Hydra



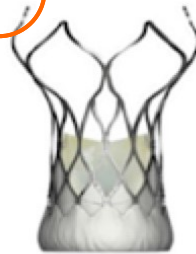Jena Valve



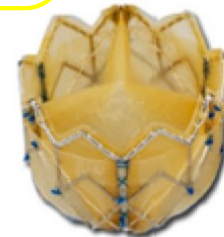J-Valve



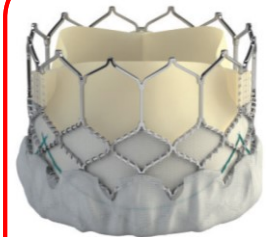
Venus-A Valve



wVR VitaFlow

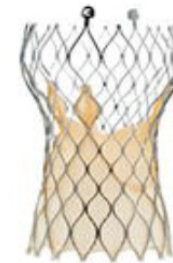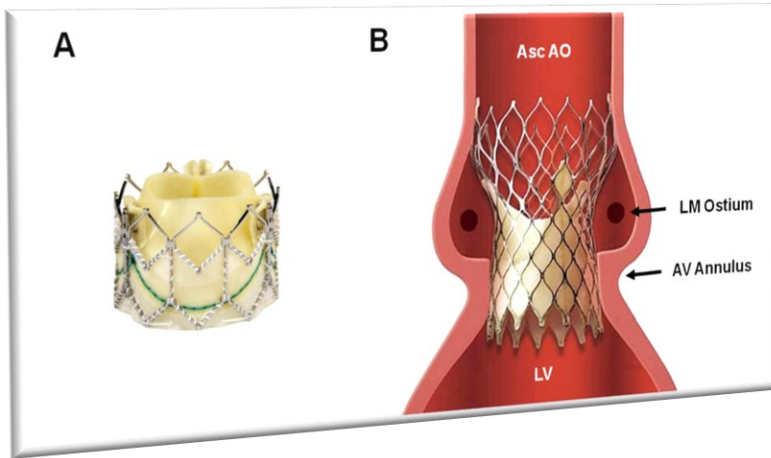


Colibri



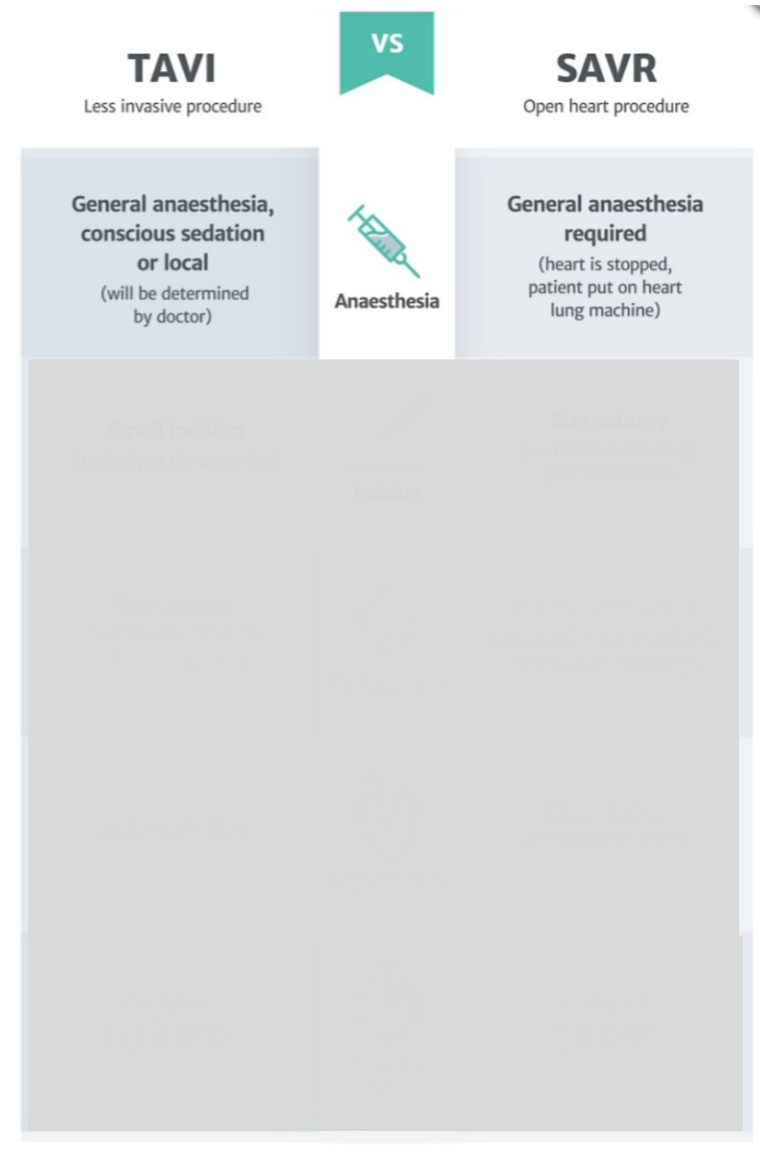
Sapien 3

THV bioprotesi: balloon vs self-expanding



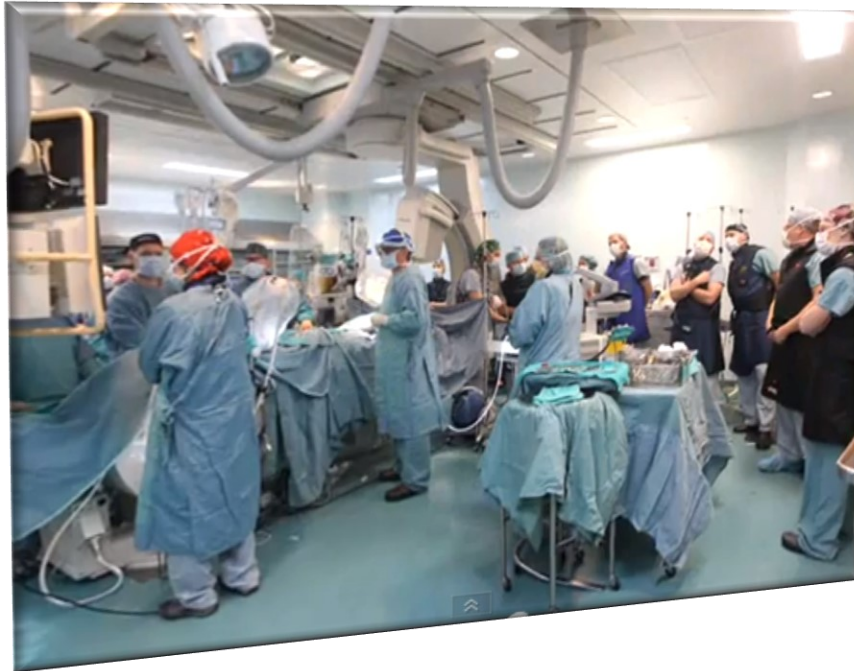| | SAPIEN 3 | Evolut Pro | Acurate Neo2 |
|------------------------------|--|------------------------|-------------------------|
| Frame/Deployment | Balloon expandable cobalt chromium alloy | Self expanding nitinol | Self expanding nitinol |
| Valve | Bovine pericardium | Porcine pericardium | Porcine pericardium |
| Seal/skirt/cuff | Yes | Yes | Yes (Active PV sealing) |
| Access | TF - TA - Tao | TF | TF - TA |
| Anti calcification treatment | Thermafix Process | Alpha-amino Oleic Acid | Biofix |

Procedure a confronto TAVI vs SAVR

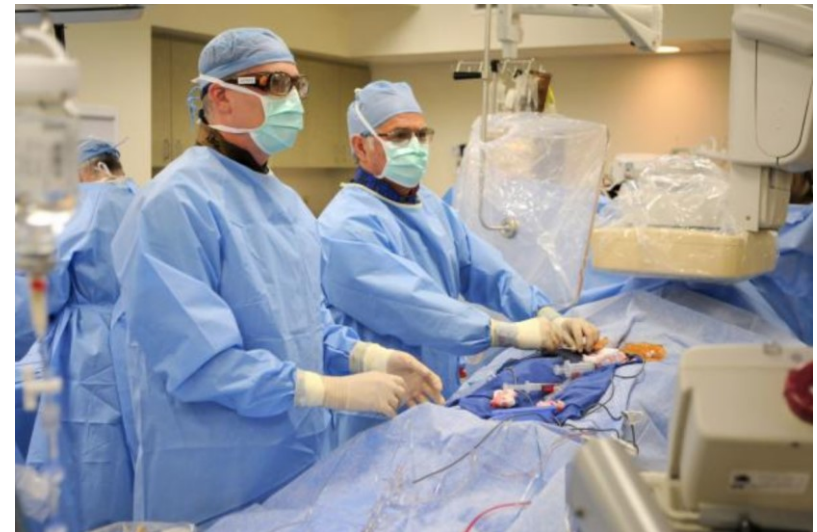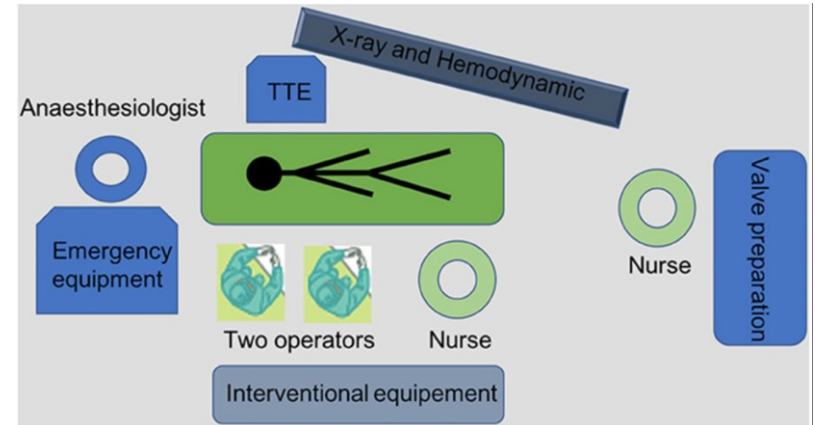


Setting procedurale

2012...



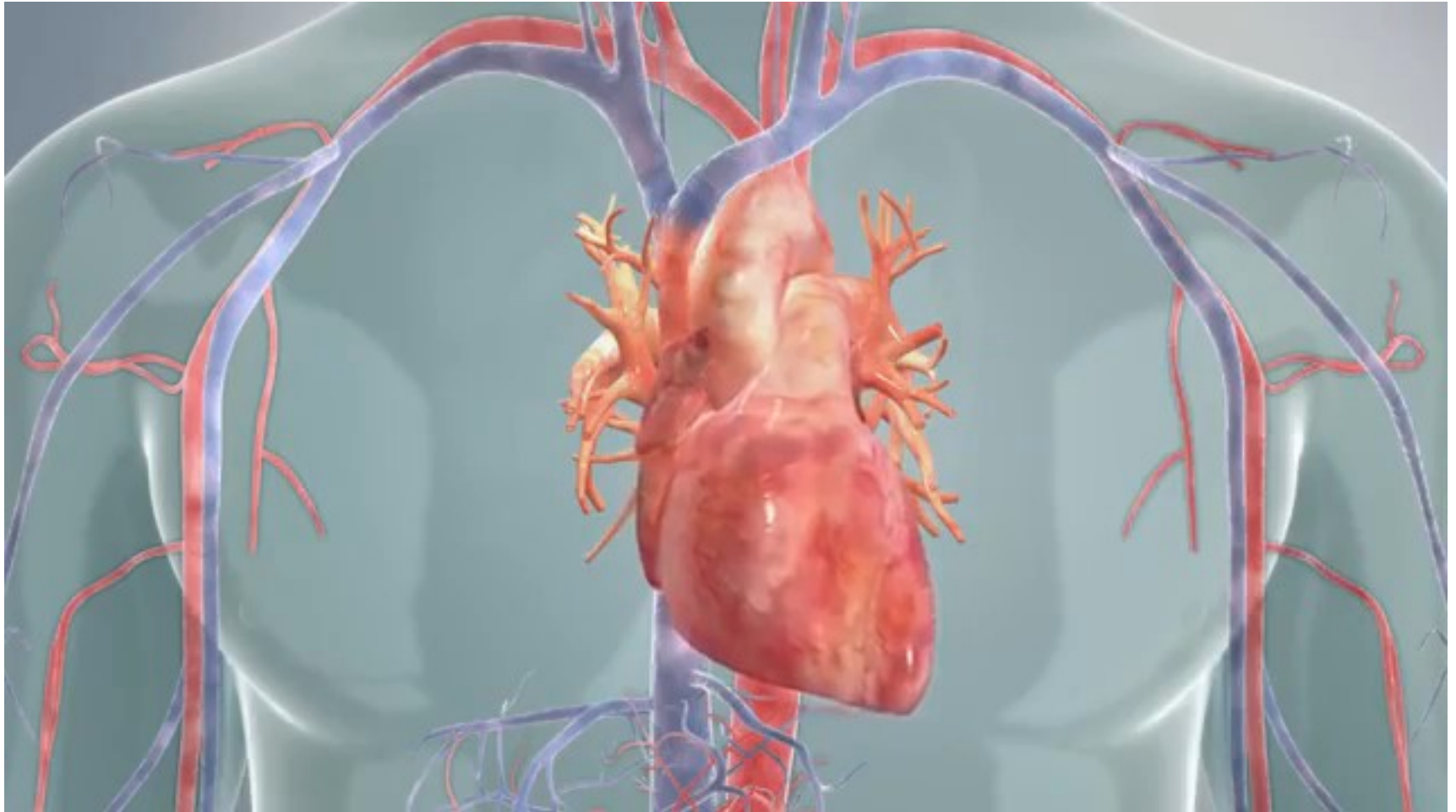...2022



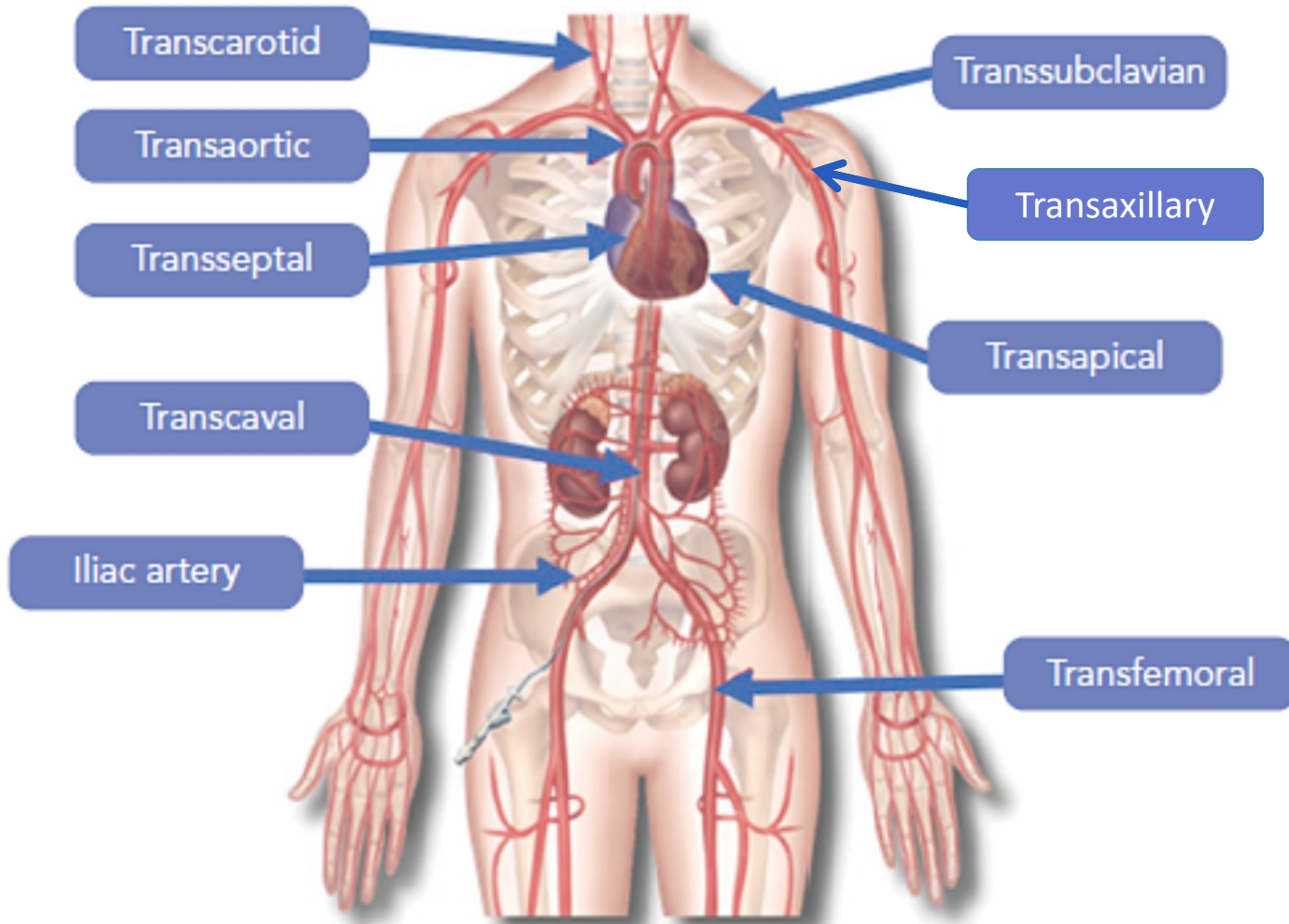
Pathway TAVI

1. TC pre-procedurale per pianificazione della procedura
2. Scelta del THV device
3. Accesso Vascolare
4. Crossing della valvola
5. Valvuloplastica aortica
6. Inserzione del sistema di delivery ed eventuale allineamento commissurale
7. Impianto della bioprotesi
8. Valutazione emodinamica/TTE post-impianto
9. Ricattura del sistema di rilascio
10. Emostasi vascolare

Procedura TAVI



Accessi per TAVI

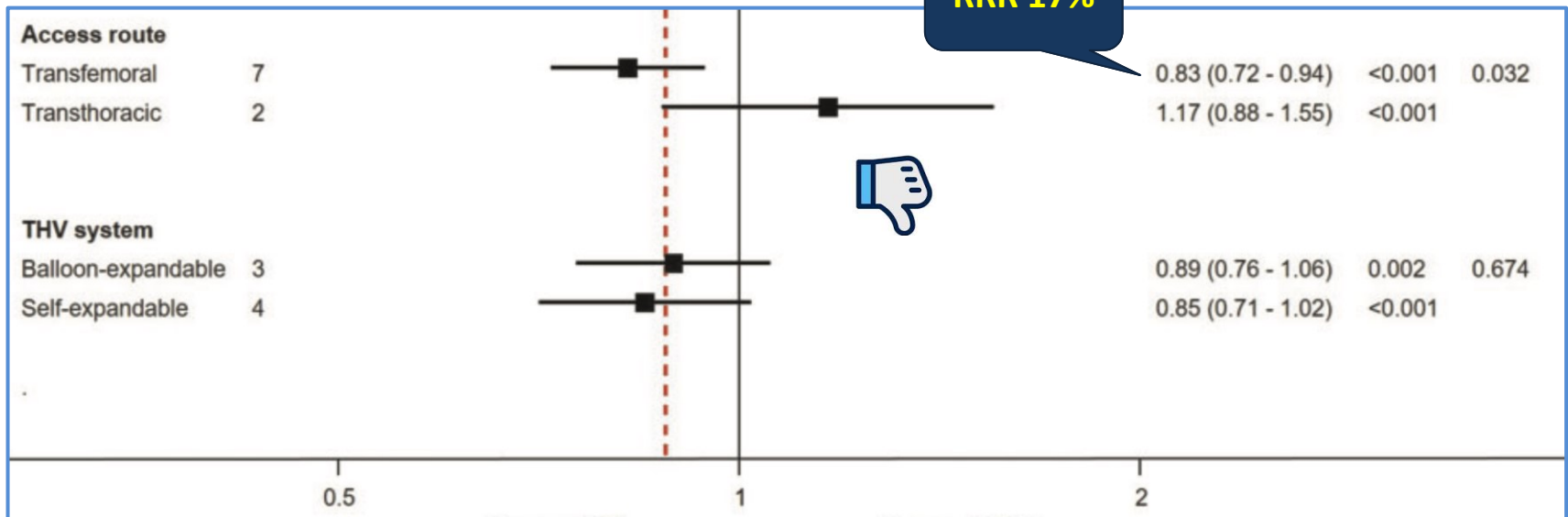


TAVI vs SAVR: META-ANALYSIS OF 7 RCT (N=8020 PTS)

SIONTIS ET AL. EUR HEART J 2019

2-year
All-cause
mortality

| Subgroup | n° of trials | HR (95%CI) | t ² | P _{inter} |
|----------|--------------|------------|----------------|--------------------|
|----------|--------------|------------|----------------|--------------------|



Accesso preferenziale per TAVI


Table 6 Clinical, anatomical and procedural factors that influence the choice of treatment modality for an individual patient

| | Favours TAVI | Favours SAVR |
|---|----------------|--------------|
| Clinical characteristics | | |
| Lower surgical risk | - | + |
| Higher surgical risk | + | - |
| Younger age ^a | - | + |
| Older age ^a | + | - |
| Previous cardiac surgery (particularly intact coronary artery bypass grafts at risk of injury during repeat sternotomy) | + | - |
| Severe frailty ^b | + | - |
| Active or suspected endocarditis | - | + |
| Anatomical and procedural factors | | |
| TAVI feasible via transfemoral approach | + | - |
| Transfemoral access challenging or impossible and SAVR feasible | - | + |
| Transfemoral access challenging or impossible and SAVR inadvisable | + ^c | - |
| Sequelae of chest radiation | + | - |
| Porcelain aorta | + | - |
| High likelihood of severe patient–prosthesis mismatch (AVA <0.65 cm ² /m ² BSA) | + | - |
| Severe chest deformation or scoliosis | + | - |
| Aortic annular dimensions unsuitable for available TAVI devices | - | + |
| Bicuspid aortic valve | - | + |
| Valve morphology unfavourable for TAVI (e.g. high risk of coronary obstruction due to low coronary ostia or heavy leaflet/LVOT calcification) | - | + |
| Thrombus in aorta or LV | - | + |
| Concomitant cardiac conditions requiring intervention | | |
| Significant multi-vessel CAD requiring surgical revascularization ^d | - | + |
| Severe primary mitral valve disease | - | + |
| Severe tricuspid valve disease | - | + |
| Significant dilatation/aneurysm of the aortic root and/or ascending aorta | - | + |
| Septal hypertrophy requiring myectomy | - | + |

Anatomical and procedural factors

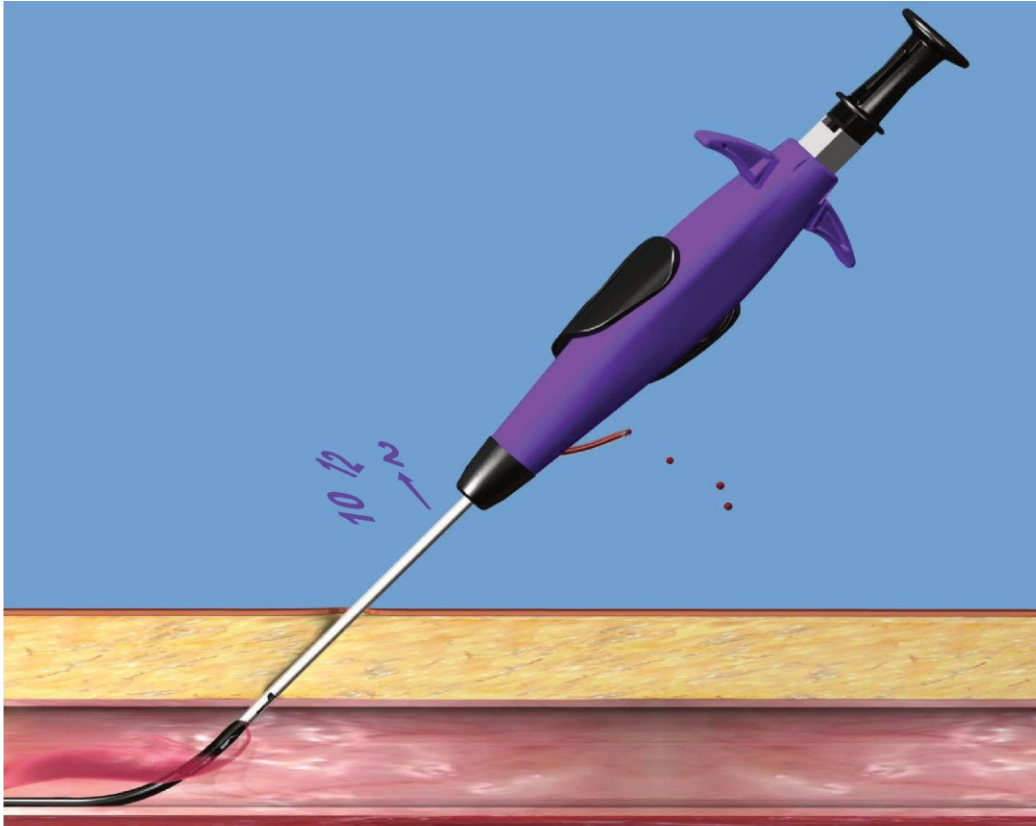
| | + | - |
|---|----------------|---|
| TAVI feasible via transfemoral approach | + | - |
| Transfemoral access challenging or impossible and SAVR feasible | - | + |
| Transfemoral access challenging or impossible and SAVR inadvisable | + ^c | - |
| Sequelae of chest radiation | + | - |
| Porcelain aorta | + | - |
| High likelihood of severe patient–prosthesis mismatch (AVA <0.65 cm ² /m ² BSA) | + | - |
| Severe chest deformation or scoliosis | + | - |
| Aortic annular dimensions unsuitable for available TAVI devices | - | + |
| Bicuspid aortic valve | - | + |
| Valve morphology unfavourable for TAVI (e.g. high risk of coronary obstruction due to low coronary ostia or heavy leaflet/LVOT calcification) | - | + |
| Thrombus in aorta or LV | - | + |

SAVR is recommended in younger patients who are low risk for surgery (<75 years^e and STS-PROM/EuroSCORE II <4%)^{e,f}, or in patients who are operable and unsuitable for transfemoral TAVI.²⁴⁴

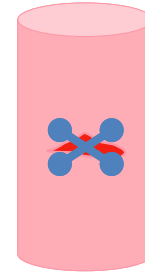


ESC HeartValve Guidelines 2021

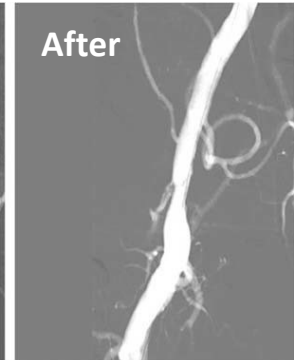
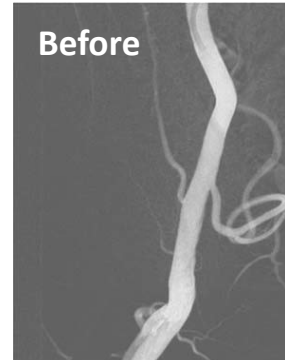Emostasi



Standard "preclose" technique



Stenosis



Adapted from Shoeib et al; Catheter Cardiovasc Interv 2018 Apr 1;91 (5): 938-944

Monitorizzazione post-TAVI in UCC

- Parametri vitali

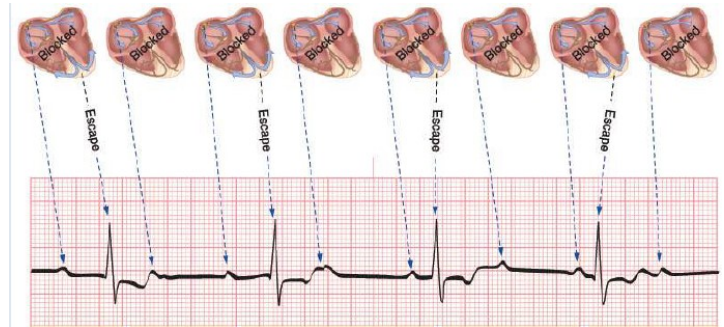


- Sanguinamento da accessi

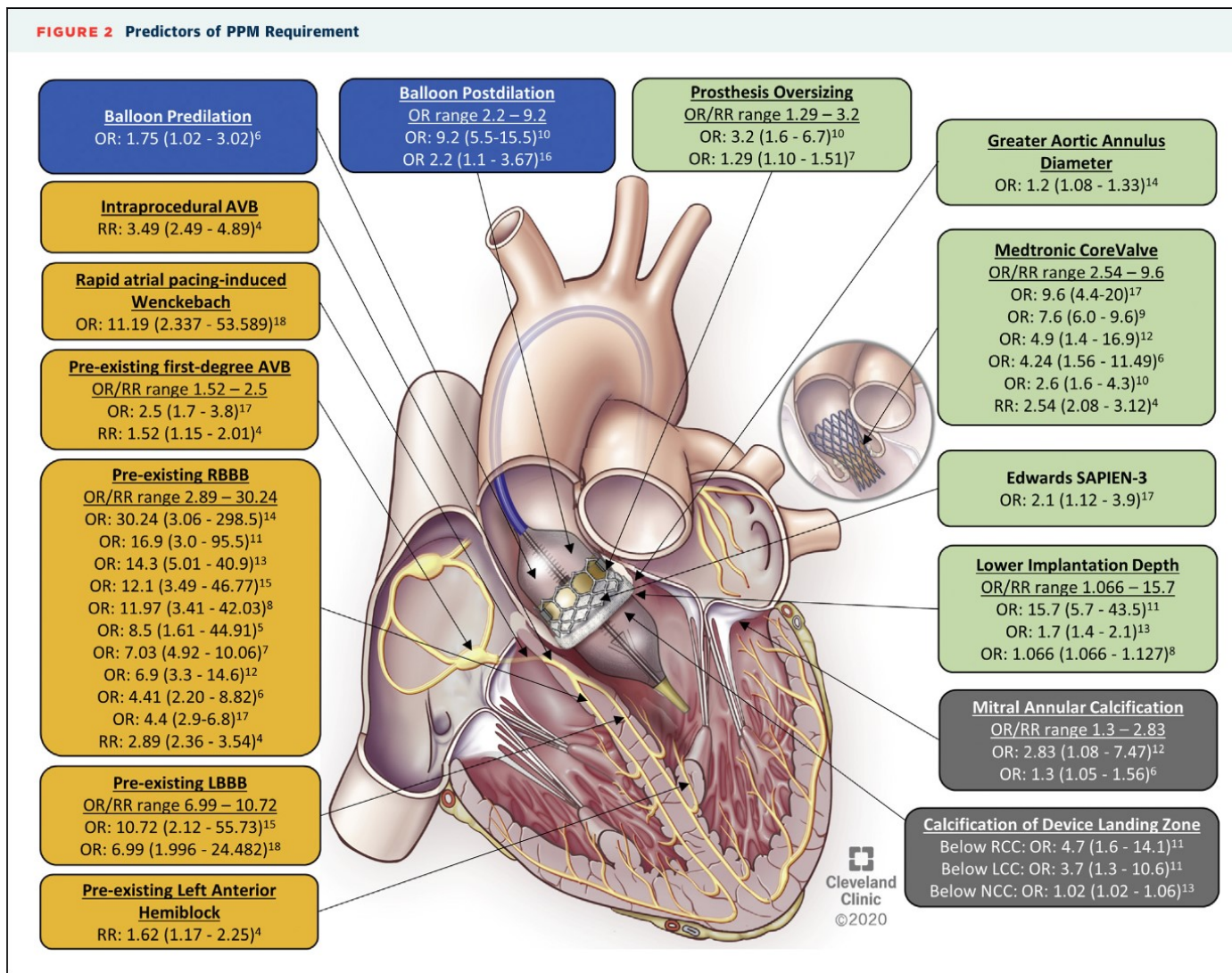


- Ritmo (BBsn? BAV avanzato?)

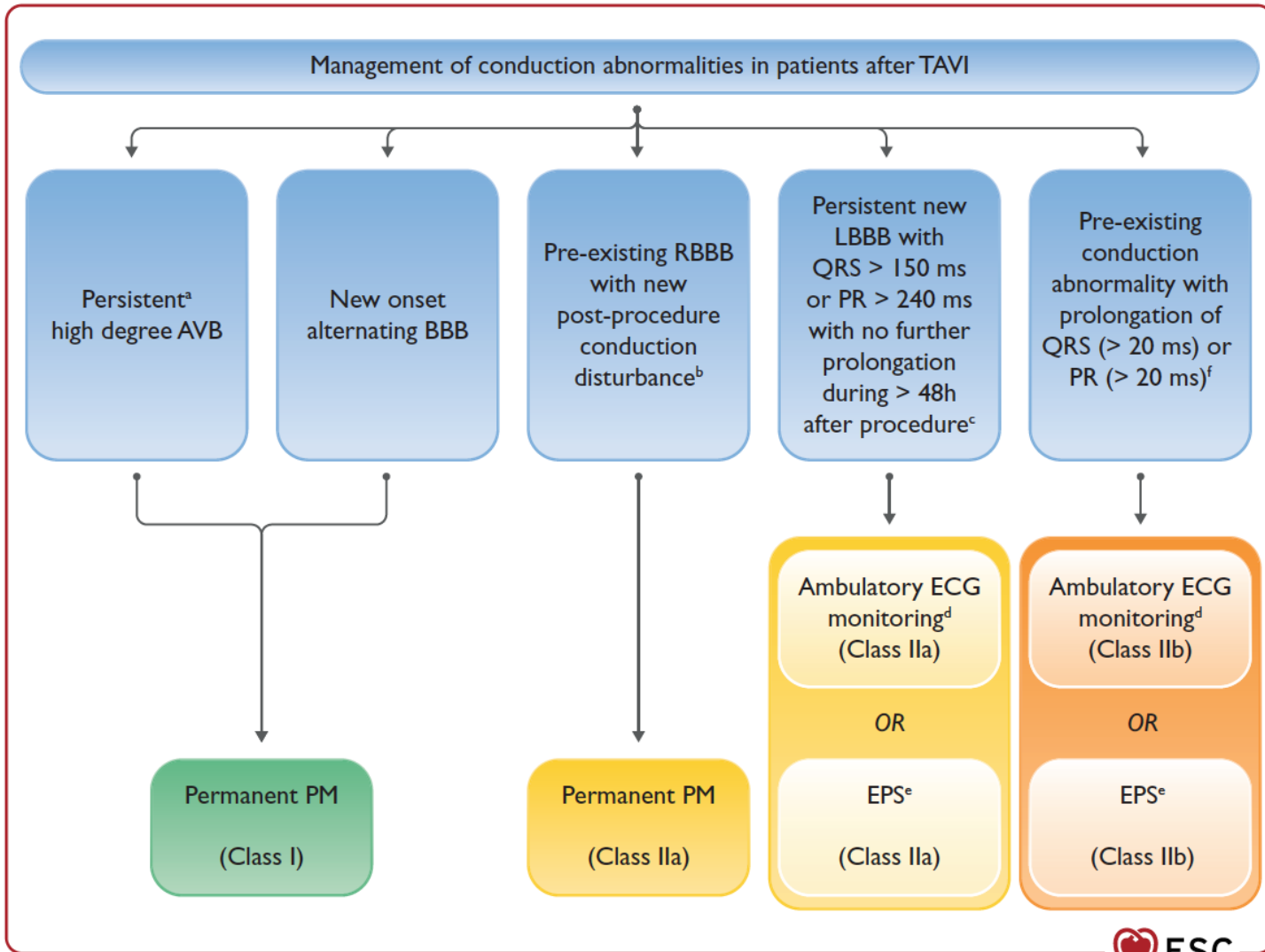
- Se presenza di PM pre-procedurale, pz potenzialmente dimissibile in reparto



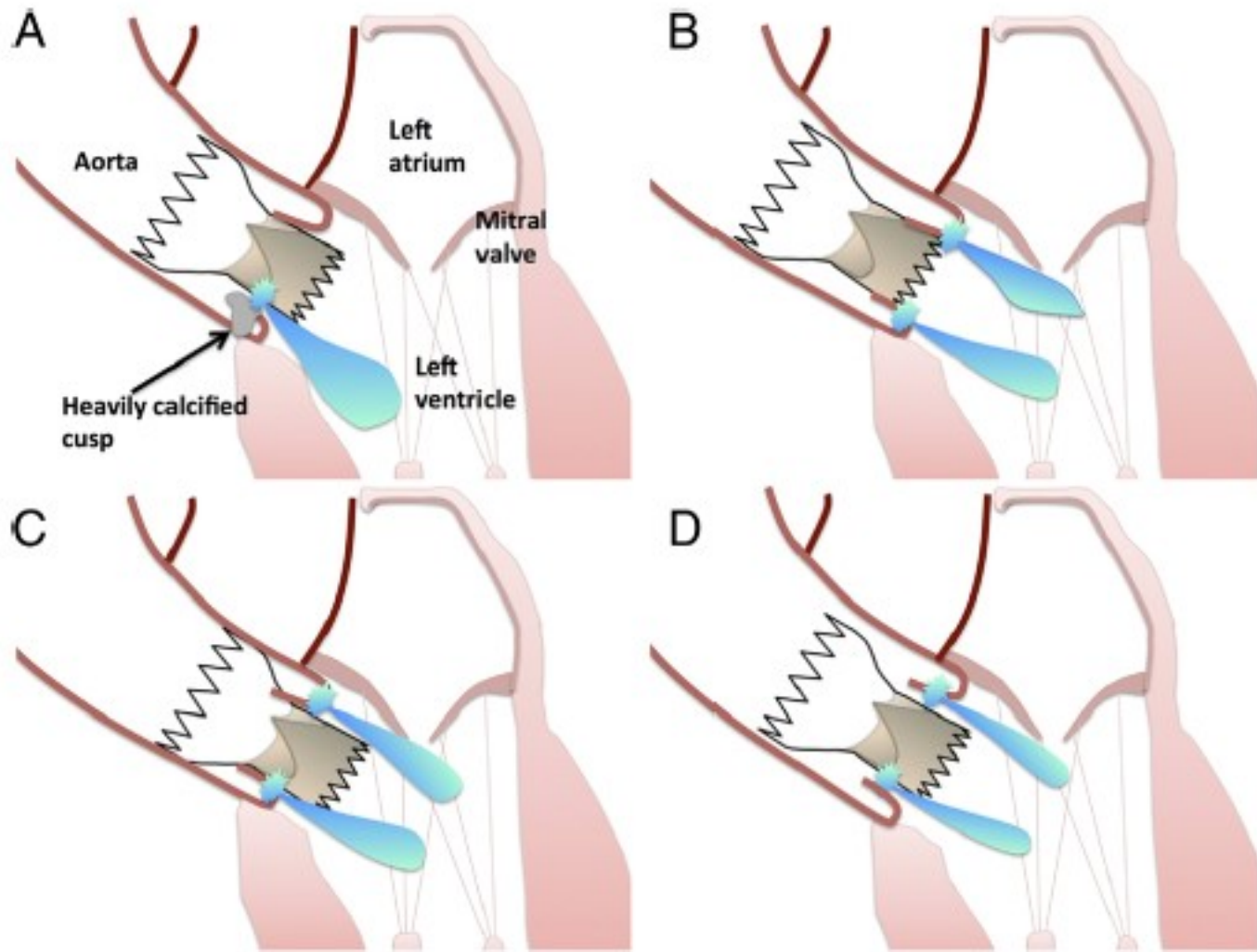
Predittori di impianto PaceMaker post-TAVI



ESC Guidelines 2021

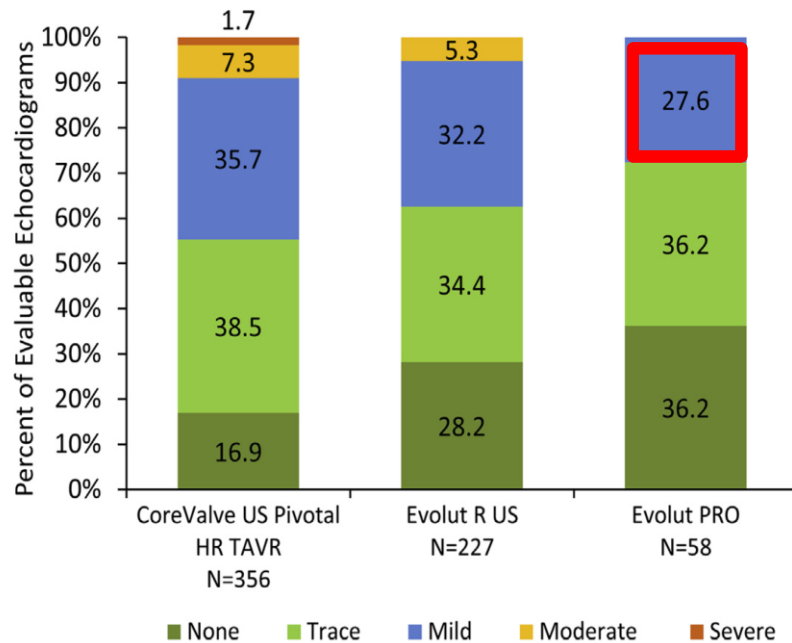


Paravalvular Leak



Early Outcomes With the Evolut PRO Repositionable Self-Expanding Transcatheter Aortic Valve With Pericardial Wrap

FIGURE 2 Paravalvular Leak at 30 Days



Echocardiographic core laboratory paravalvular leak at 30 days for patients treated with CoreValve bioprosthesis (1), the Evolut R valve (13), and the Evolut PRO valve.



Conclusioni

- La procedura TAVI ha rivoluzionato il trattamento della stenosi valvolare aortica
- La procedura TAVI ha mostrato un beneficio in termini di sopravvivenza a breve-medio termine, indipendentemente dal rischio chirurgico di base (procedura eseguita per via transfemorale)
- L'evoluzione delle bio-tecnologie/bio-ingegneria contribuiranno sempre più a semplificare la procedura TAVI, ridurre le complicanze, incrementare la durabilità delle valvole ed estenderne le indicazioni