

Il trattamento mini invasivo del dolore lombare: dove il farmaco si è rivelato inadeguato

Matteo L.G. Leoni

Interventional and Surgical Pain management, Piacenza
Department of Medical and Surgical Science and Translational Medicine,
Sapienza University of Rome
matteolg.leoni@gmail.com



- 25% of LBP patients seek medical attention
- One of top 3 reasons to go to family practitioner (FP)
- FP see more LBP than Ortho + Neurosurgeons

Time is.....therapy

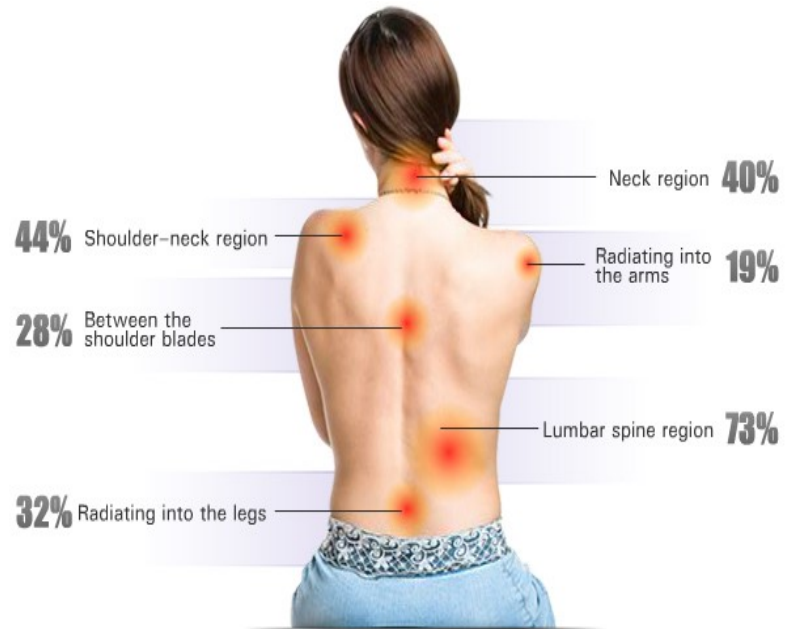
- Episodes of back pain are self-limited:

70% improve within 2 weeks

90% improve within 6 weeks

3% DO NOT improve in 6-12 weeks





Non-specific (90%)

- Functional disorder through incorrect weight-bearing and wear (mechanical)

Specific (10%)

- Nerve root irritation and compression syndrome
- Prolonged pain (extravertebral or visceral)
- Intervertebral disc prolapse
- Metabolic (osteoporosis, fracture)
- Somatoform pain disorders/fibromyalgia
- Malignant (primary tumours/metastasis)
- Inflammatory (rheumatic, infections)

Red flags



- Trauma
- Unexplained weight loss, insidious onset
- Age > 50 yrs, especially women, and males with osteoporosis or compression fracture
- Unexplained fever, history of infection
- Immunosuppression, diabetes mellitus
- History of cancer
- Intravenous (IV) drug use
- Prolonged use of corticosteroids, osteoporosis
- Age > 70 yrs
- Focal neurologic deficit(s) with progressive or disabling symptoms, cauda equina syndrome
- Duration longer than 6 weeks
- Prior surgery

Differential

97%

Mechanical

- Lumbar spondylosis
- Disk herniation
- Spondylolisthesis
- Spinal stenosis
- Fractures (mostly osteoporotic)
- Nonspecific (idiopathic)

Neoplastic

- Primary
- Metastatic

Inflammatory

- Spondyloarthritides

Infectious

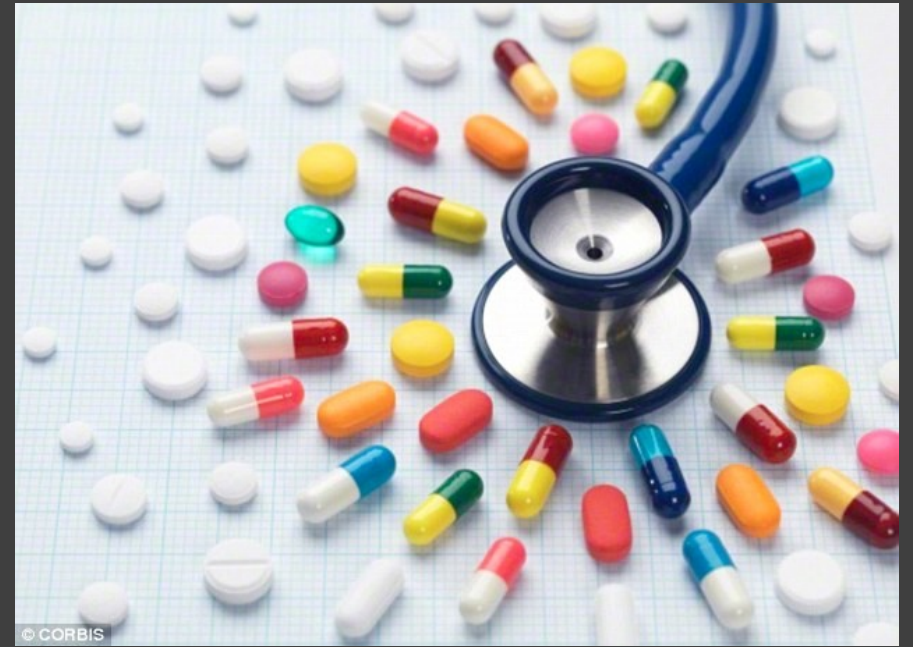- Vertebral osteomyelitis
- Epidural abscess
- Septic diskitis
- Herpes zoster

Metabolic

- Osteoporotic compression fractures
- Paget's disease

Referred Pain to Spine

- From major viscera, retroperitoneal structures, **urogenital system, aorta**, or hip



Drug notes

NICE National Institute for
Health and Care Excellence

Managing low back pain and sciatica

NICE Pathway last updated: 07 April 2021

Pharmacological treatments



- NSAIDs for LBP (lowest effective dose for the shortest possible period of time)
- Weak opioids \pm paracetamol for **acute** LBP **only** if an NSAID is contraindicated
- Do not offer paracetamol alone
- **Opioids**
 - Do not routinely offer opioids for managing **acute** LBP
 - Do not offer opioids for managing **chronic** LBP
- Do not offer SSRI, SNRI or gabapentinoids for LBP



Opioids

GEDI
VISUAL

RepL

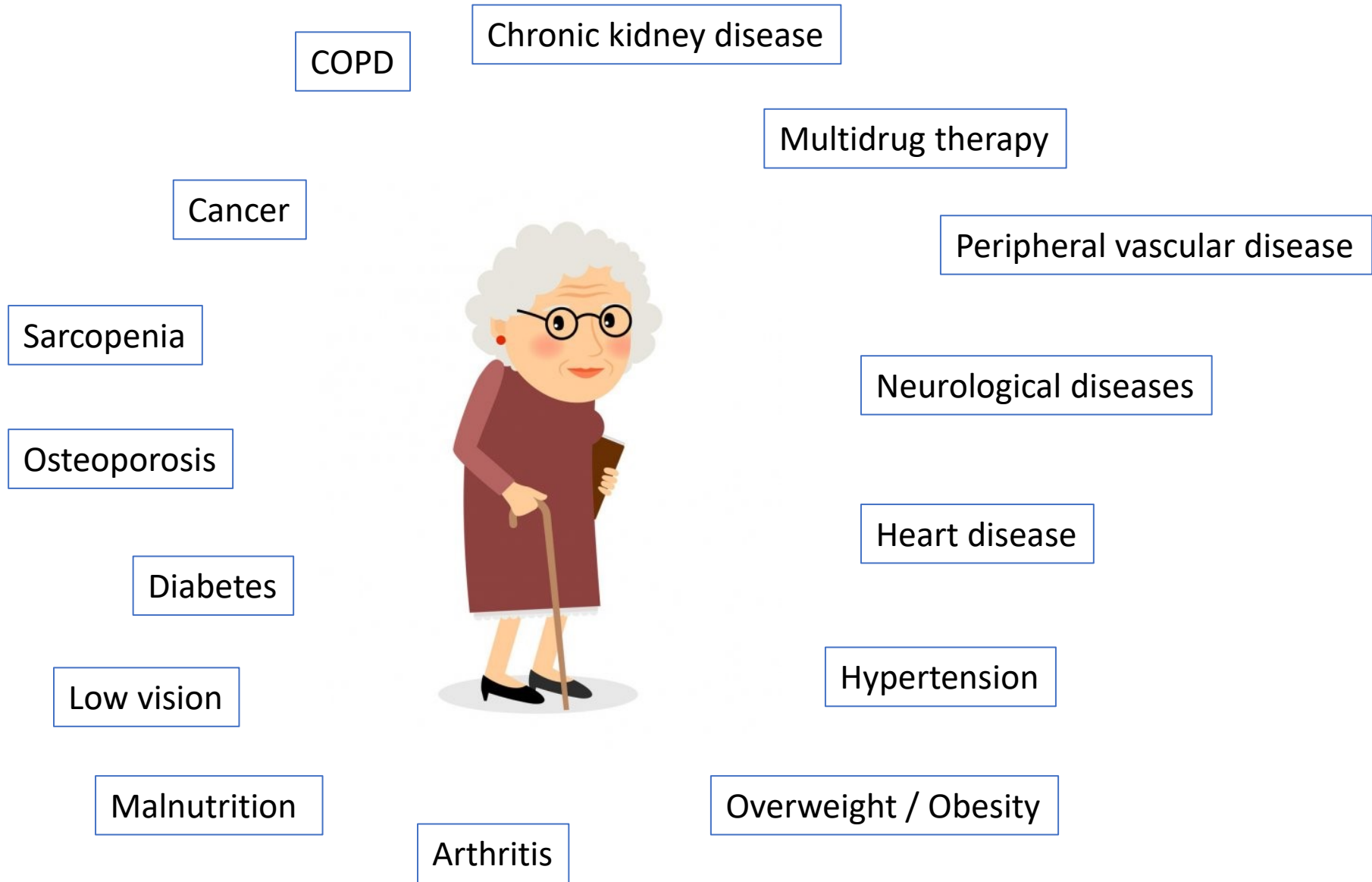




START LOW. GO SLOW.

www.cdc.gov

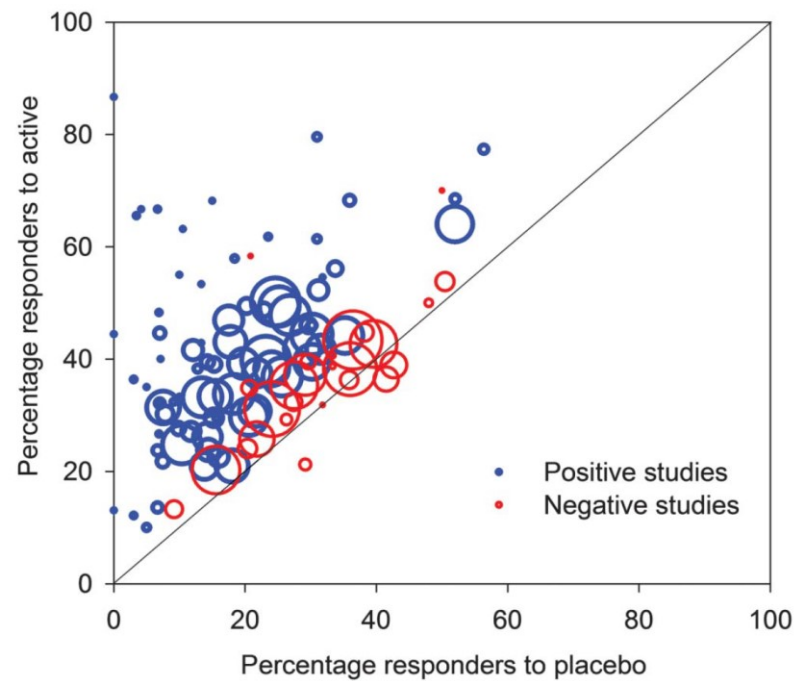
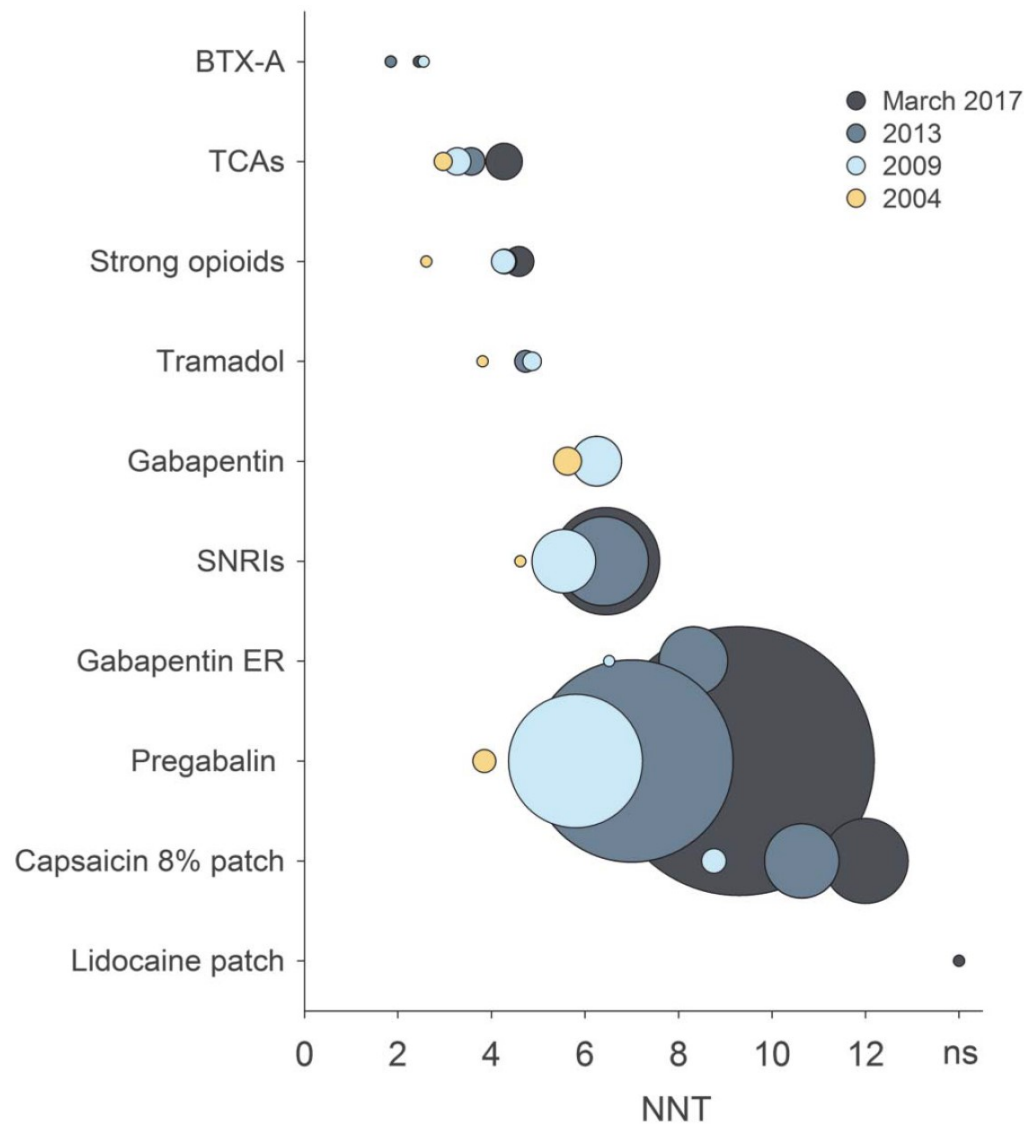
GUIDELINE FOR PRESCRIBING
OPIOIDS FOR CHRONIC PAIN





Neuropathic pain?

	Total daily dose and dose regimen	Recommendations
Strong recommendations for use		
Gapabentin	1200–3600 mg, in three divided doses	First line
Gabapentin extended release or enacarbil	1200–3600 mg, in two divided doses	First line
Pregabalin	300–600 mg, in two divided doses	First line
Serotonin-noradrenaline reuptake inhibitors duloxetine or venlafaxine*	60–120 mg, once a day (duloxetine); 150–225 mg, once a day (venlafaxine extended release)	First line
Tricyclic antidepressants	25–150 mg, once a day or in two divided doses	First line†
Weak recommendations for use		
Capsaicin 8% patches	One to four patches to the painful area for 30–60 min every 3 months	Second line (peripheral neuropathic pain)‡
Lidocaine patches	One to three patches to the region of pain once a day for up to 12 h	Second line (peripheral neuropathic pain)
Tramadol	200–400 mg, in two (tramadol extended release) or three divided doses	Second line
Botulinum toxin A (subcutaneously)	50–200 units to the painful area every 3 months	Third line; specialist use (peripheral neuropathic pain)
Strong opioids	Individual titration	Third line§



What about the efficacy of pharmacotherapy of neuropathic pain ?

...Even first-line treatments are beneficial in **less than 50% of patients**

...Despite the introduction of new and safer drugs and the publication of several randomized controlled trials supporting evidence-based treatment, **many patients still do not obtain sufficient pain** relief or do not tolerate adequate doses because of side effects...

EDITORIAL

For reprint orders, please contact: reprints@futuremedicine.com

Pharmacotherapy of neuropathic pain: time to rewrite the rulebook?



Nanna B Finnerup*¹ & Nadine Attal^{2,3}

“The International Association for the Study of Pain has declared 2014–2015 the Global Year Against Neuropathic Pain, which is an excellent opportunity to draw attention to the recent advances in the treatment of neuropathic pain.”

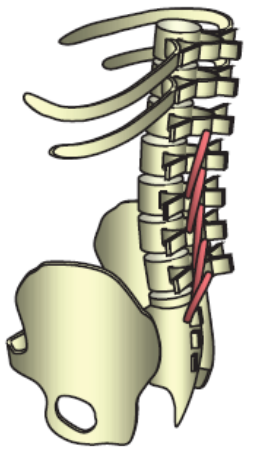
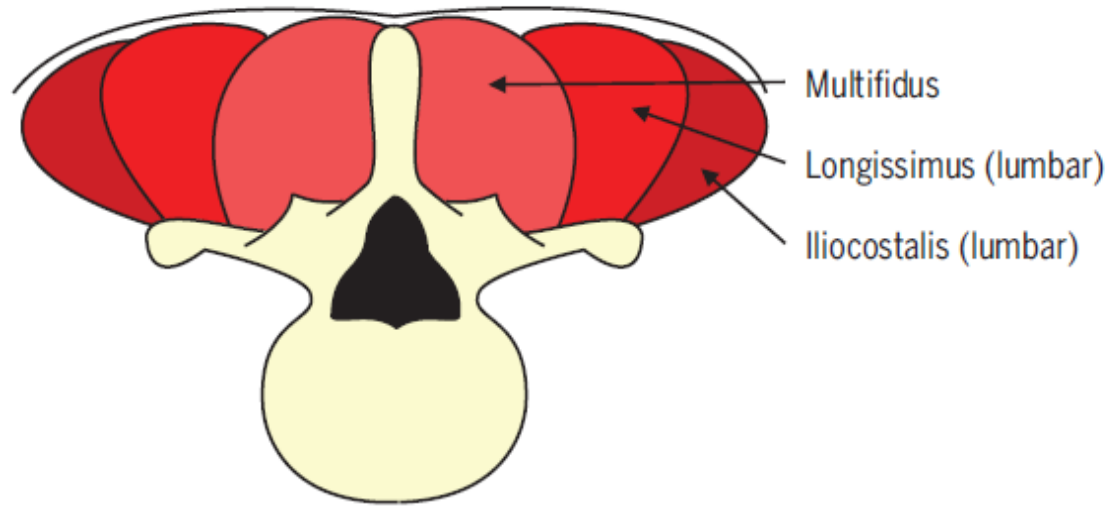
First draft submitted: 24 August 2015; Accepted for publication: 16 September 2015; Published online: 17 December 2015

The fundamentals of treatment

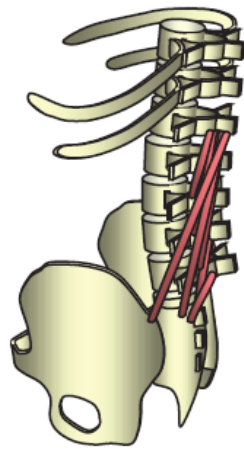
- Drugs can lessen neuropathic pain by **30–50%**
- Complete freedom from pain **often cannot be achieved**
- For all types of drug, **20–40%** of patients experience <30% pain reduction (“**non-responders**”) or have intolerable side-effects

Active physical therapies

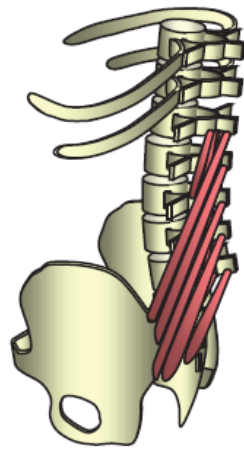
- Increase daily physical activity
- Walking, hydrotherapy, yoga and Tai-Chi



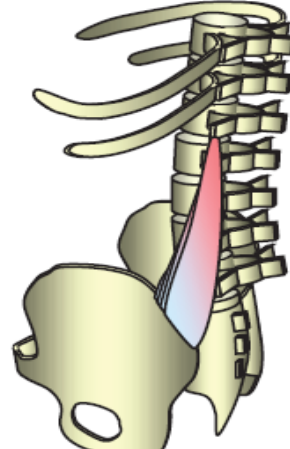
Multifidus (deep fibers)



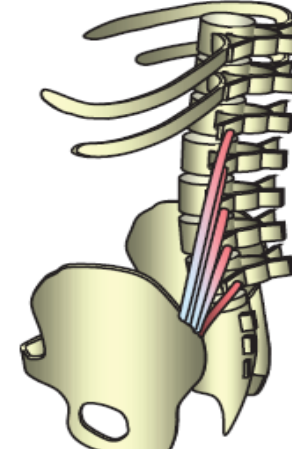
Multifidus (deep to superficial fibers)



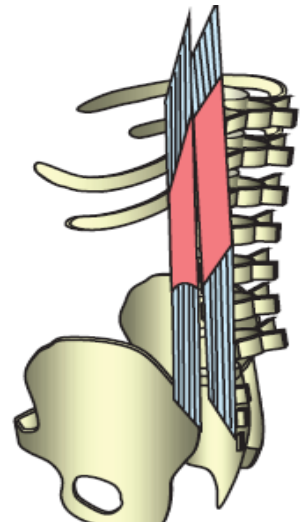
Multifidus (superficial fibers)



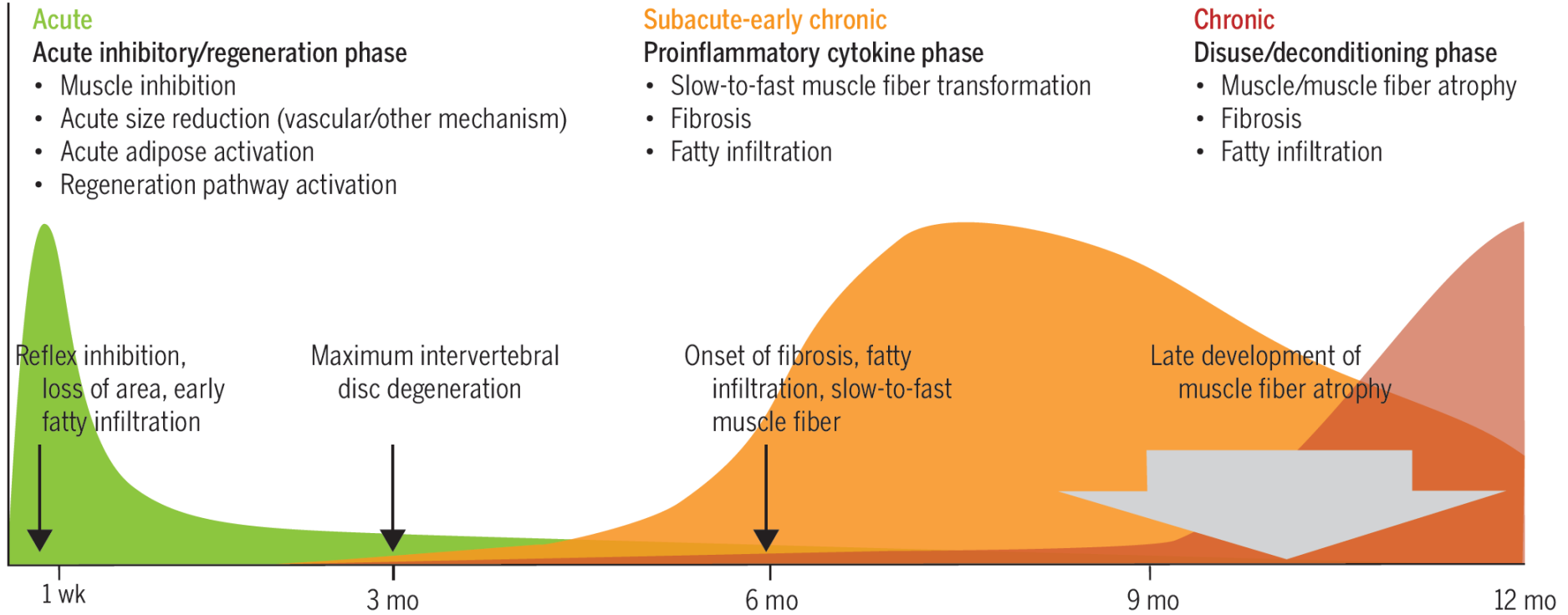
Iliocostalis (lumbar)

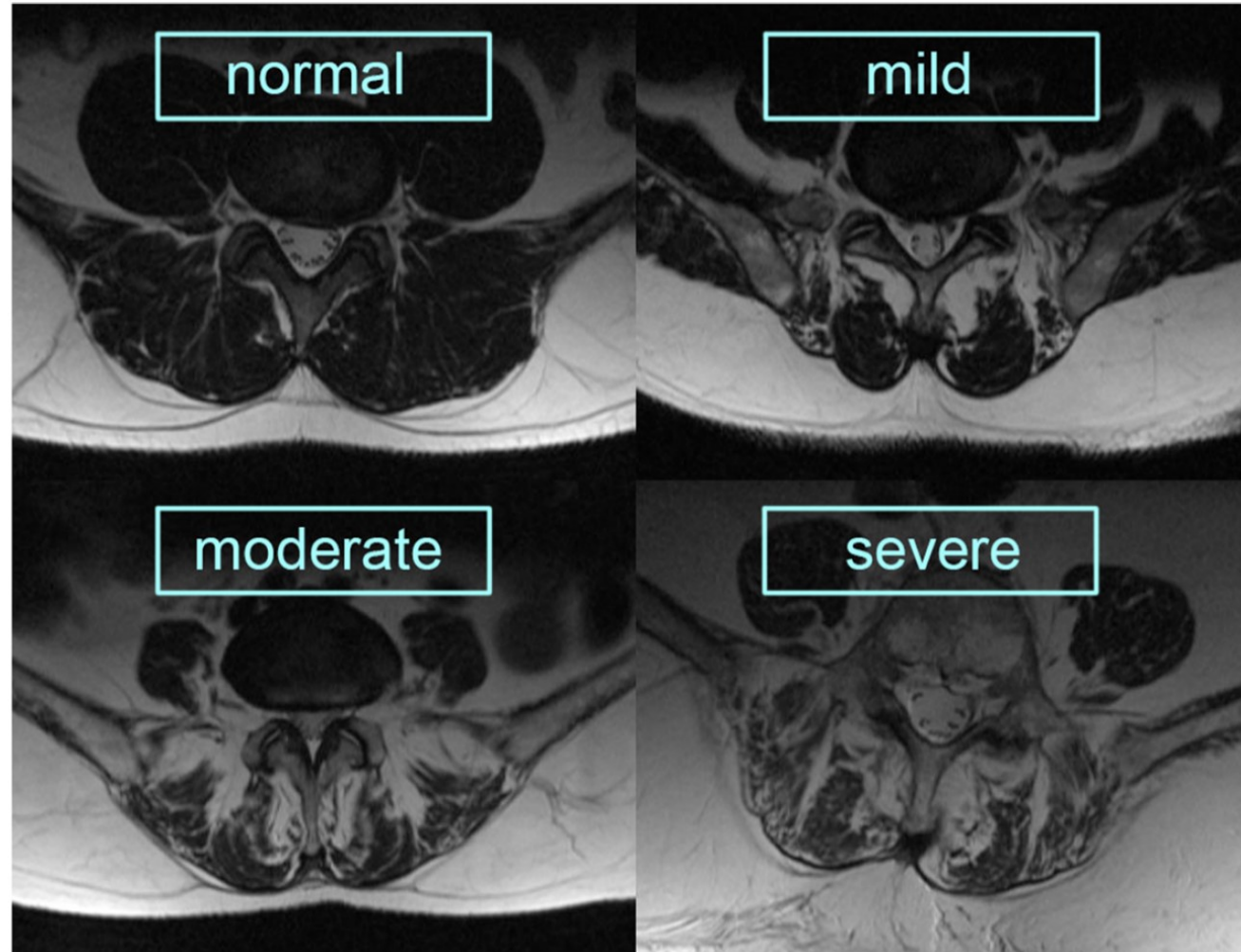


Longissimus (lumbar)



Longissimus/iliocostalis (thoracolumbar)



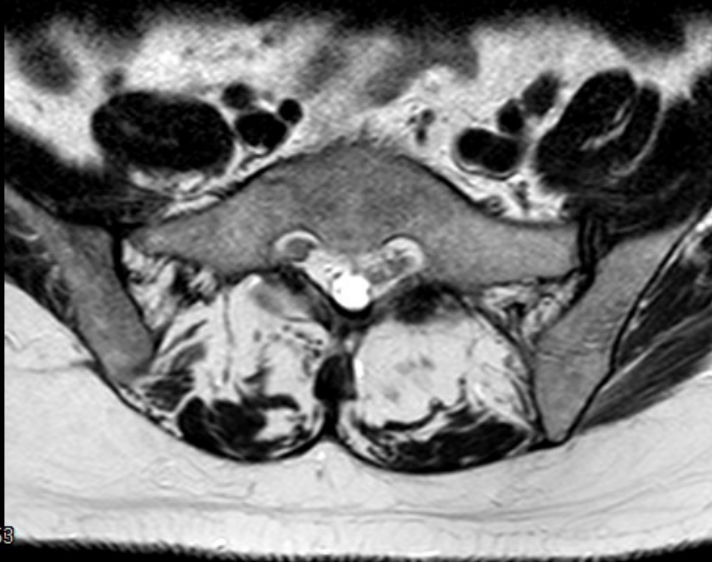

Grade 1: normal muscle, fatty infiltration <10% of the muscle's CSA

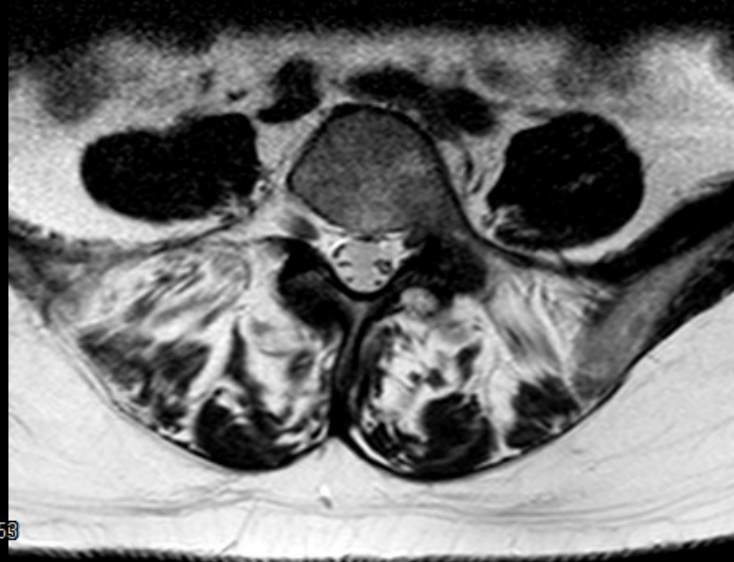
Grade 2: mild muscle degeneration, 10–30% fatty infiltration

Grade 3: moderate, 30–50% fat degeneration

Grade 4: severe muscle atrophy with over >50% fatty infiltration



6.50



5.50





Referring a patient??

- Adherence to treatment
- Adequate drugs titration



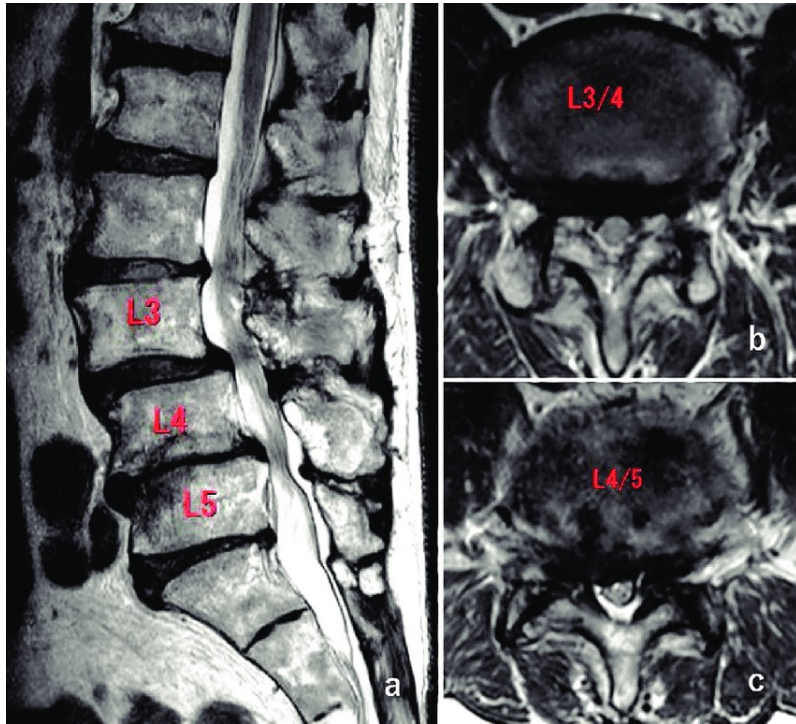
Criteri di priorità all'accesso Piacenza

- Dolore neoplastico
- Zoster acuto
- Nevralgia trigeminale in fase acuta
- Dolore radicolare acuto o riacutizzato **pesantemente invalidante** (costringe il paziente a letto da almeno 15 giorni)

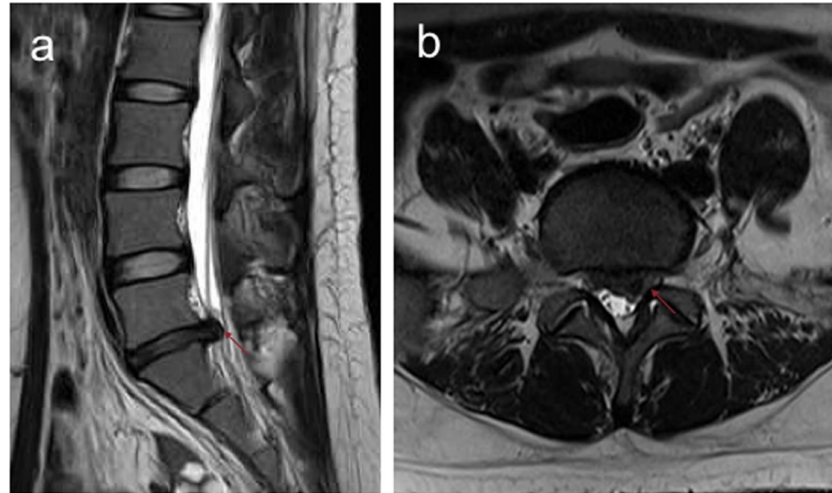


 <p>SERVIZIO SANITARIO REGIONALE EMILIA-ROMAGNA Azienda Unità Sanitaria Locale di Piacenza</p> <p>Dipartimento Anestesia, Rianimazione, Comparto operatorio e Terapia del dolore TERAPIA DEL DOLORE</p>	<p>PERCORSO DIAGNOSTICO TERAPEUTICO</p> <p>PAZIENTE CON DOLORE</p>	<p>Codice Versione 01 Del Pag. 1/34</p>
---	--	---

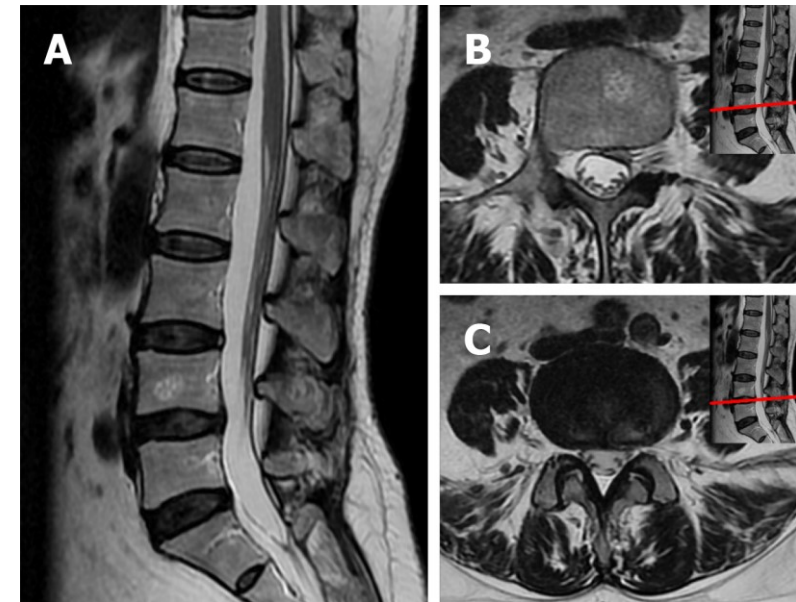
Patient related questions




Patient 1



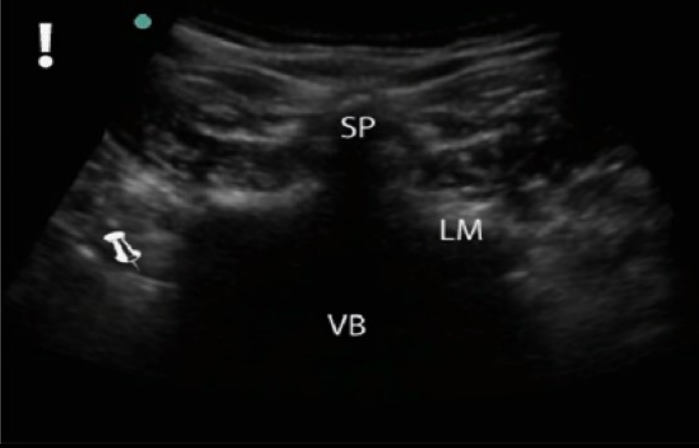
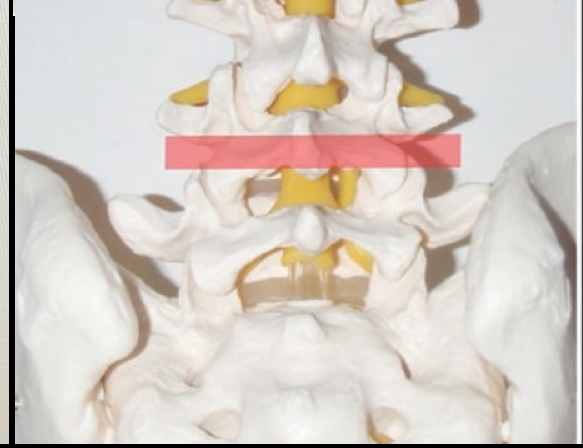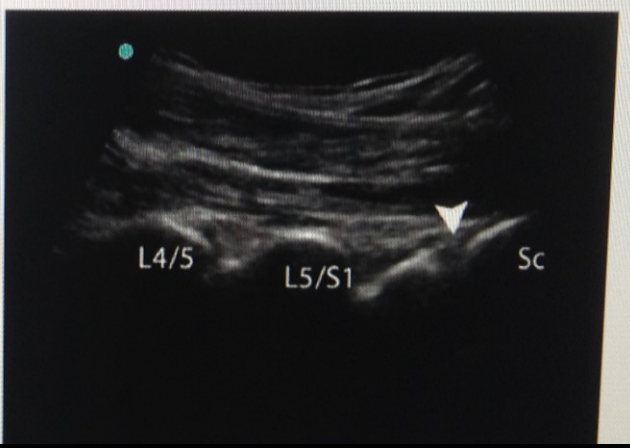
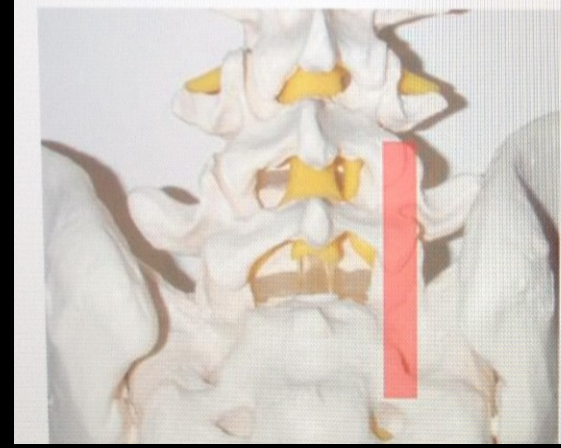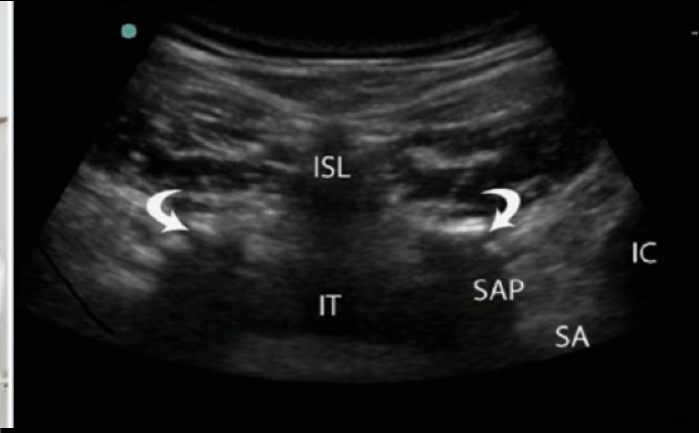
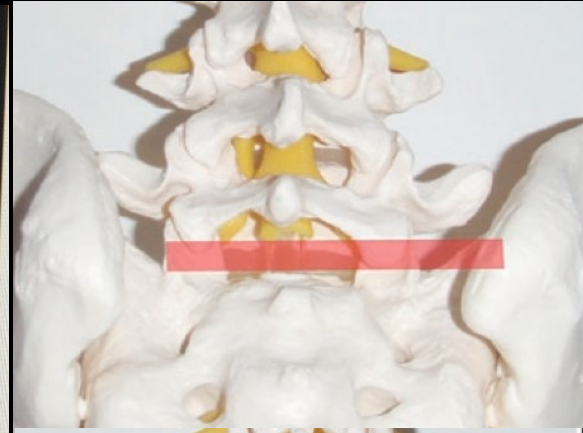
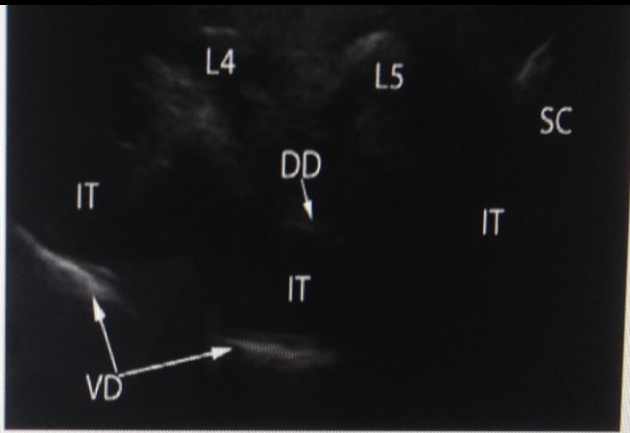
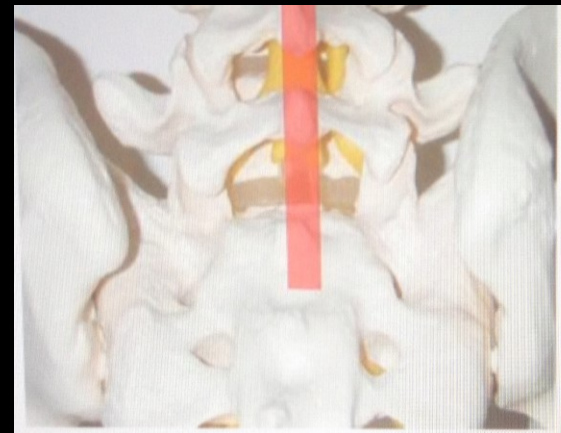Patient 2

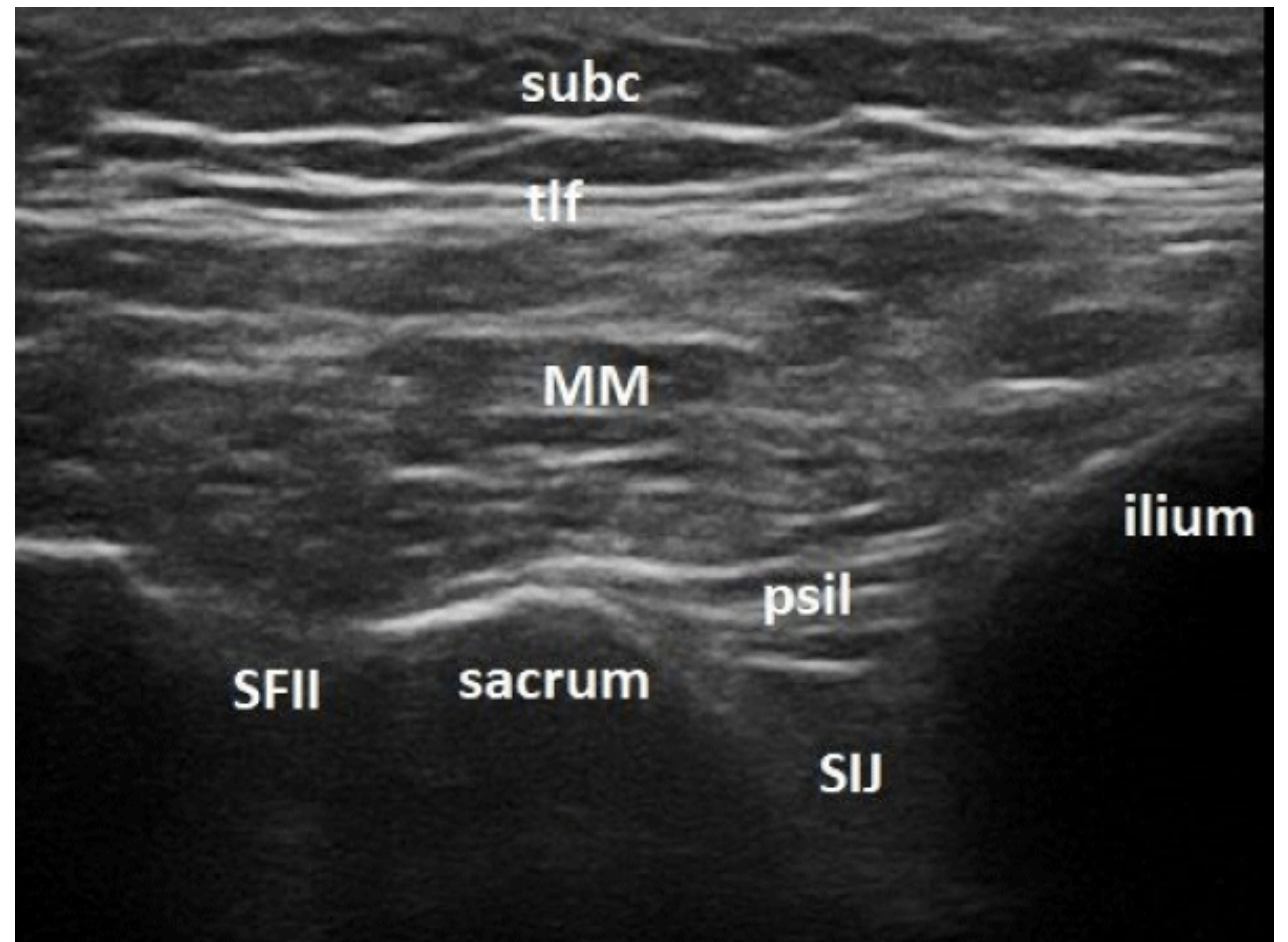
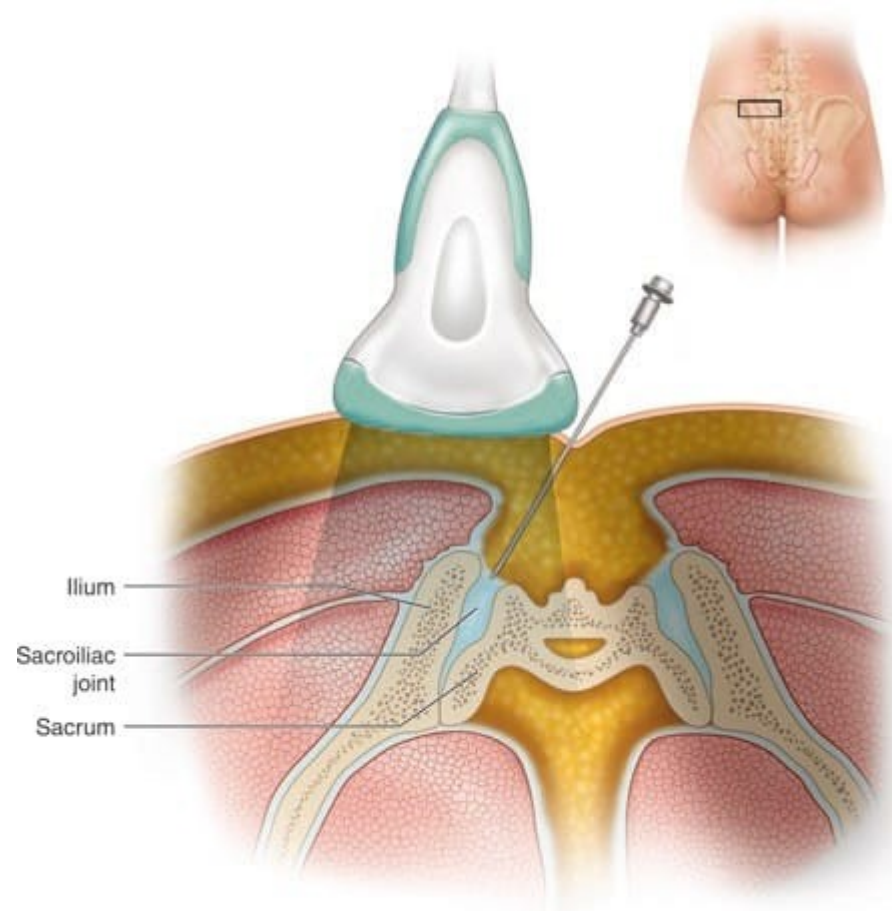


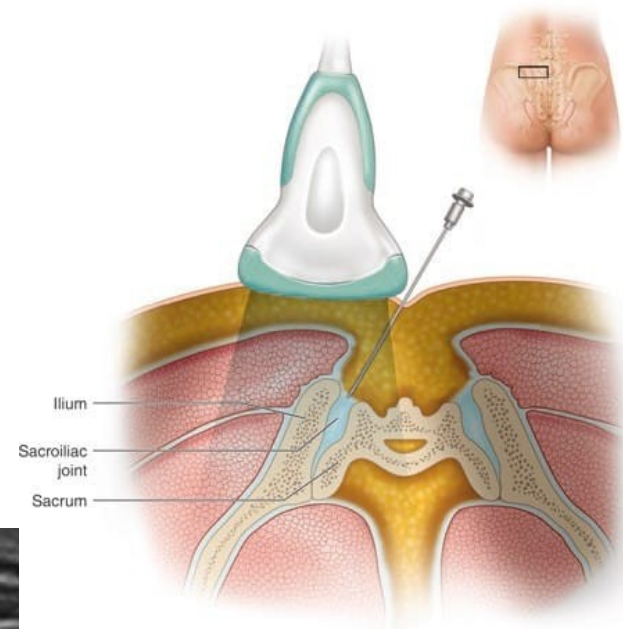
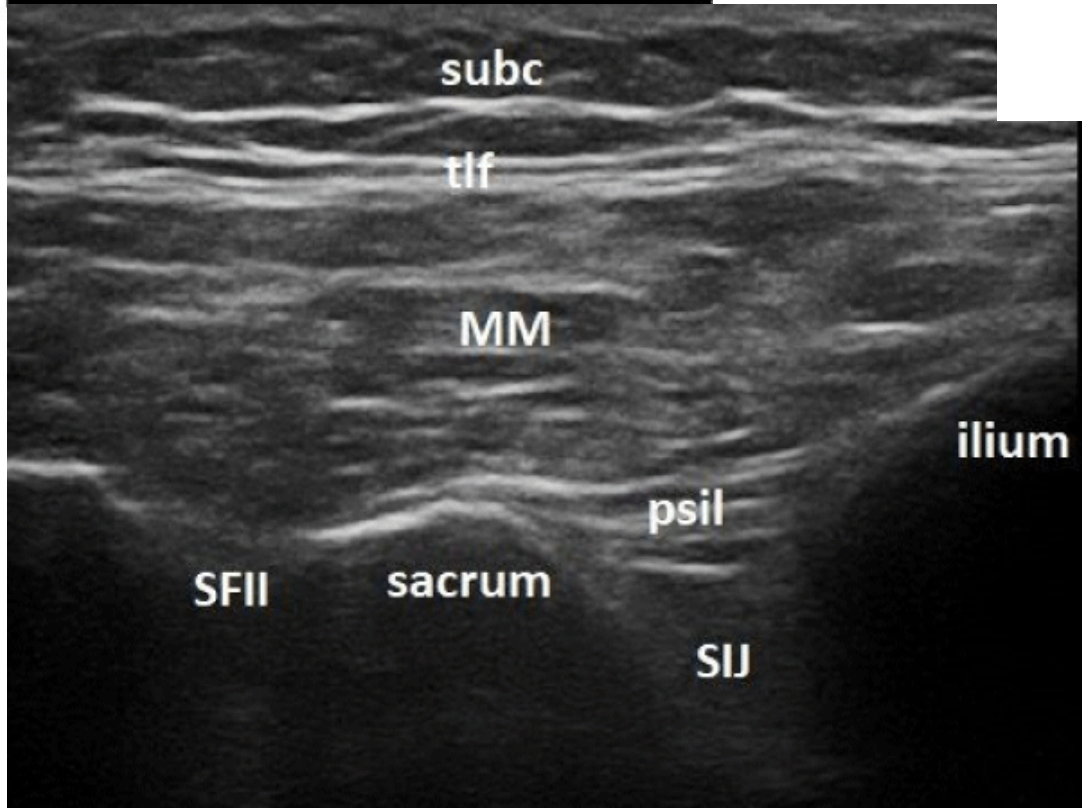
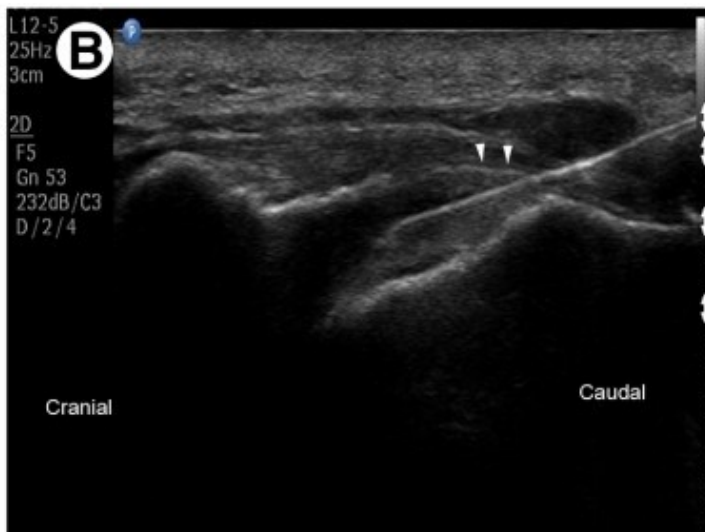
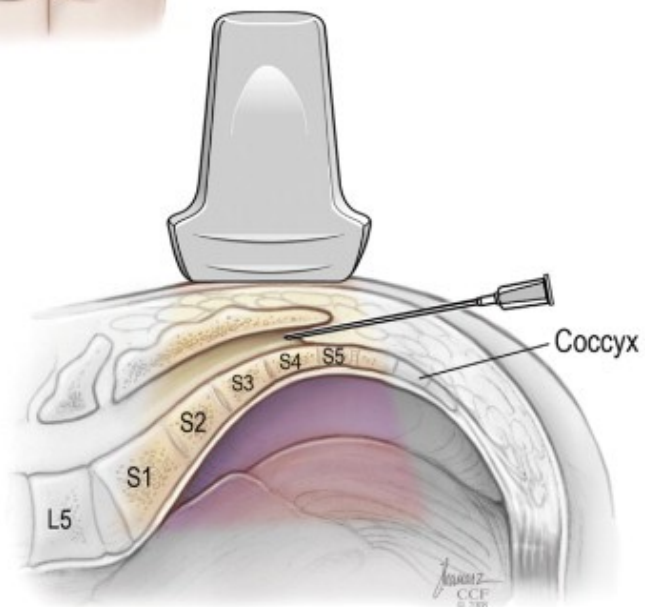
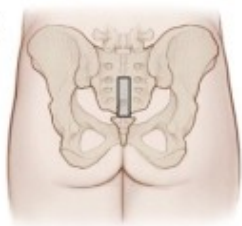Patient 3

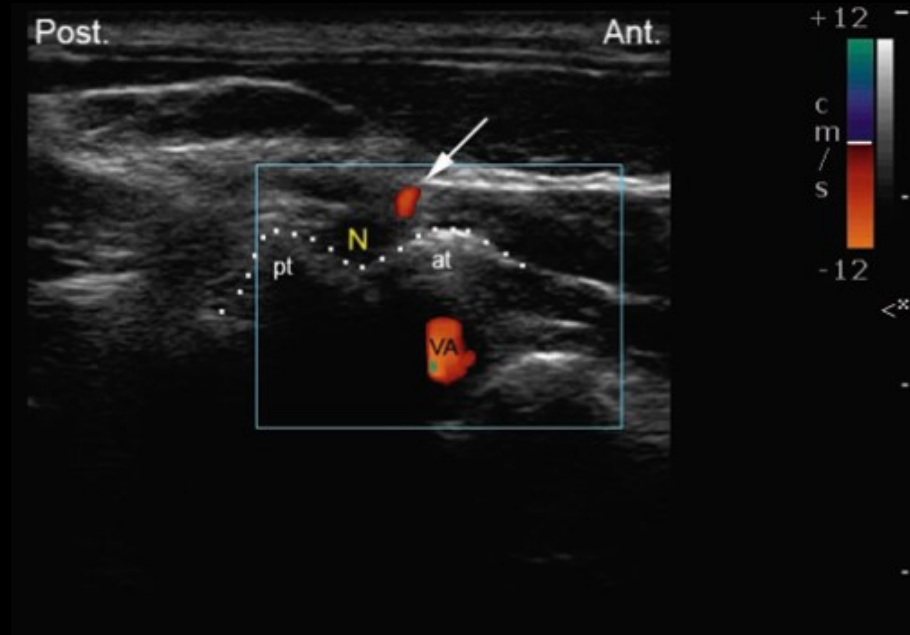
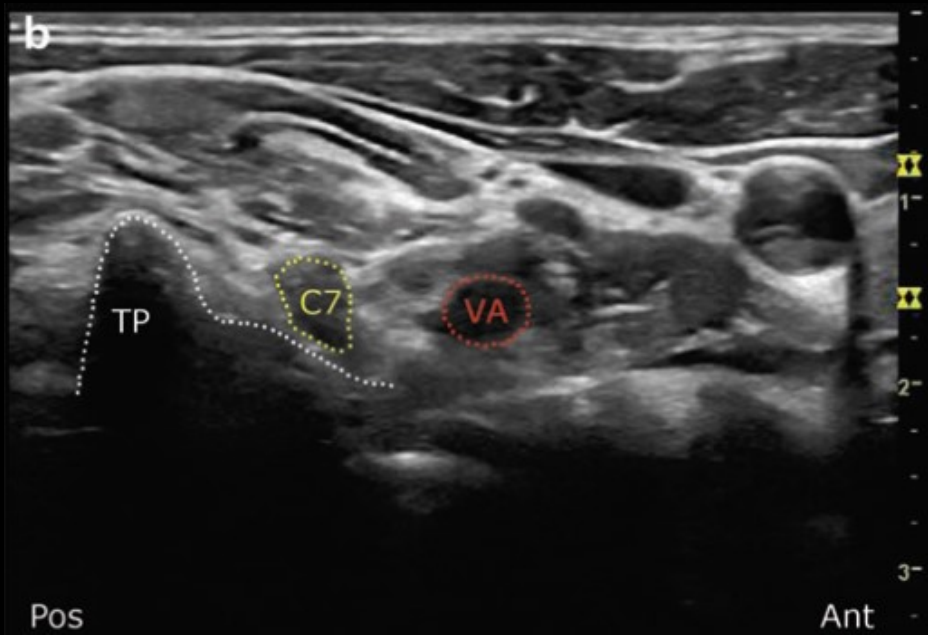
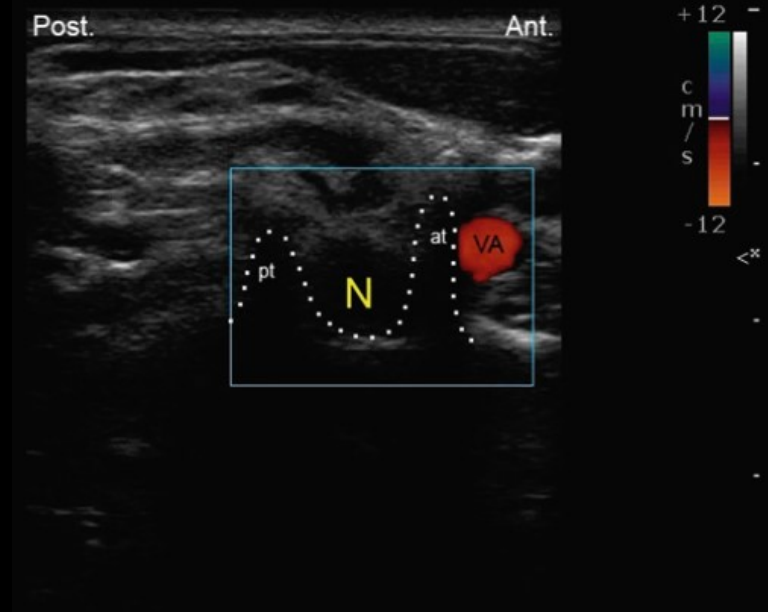
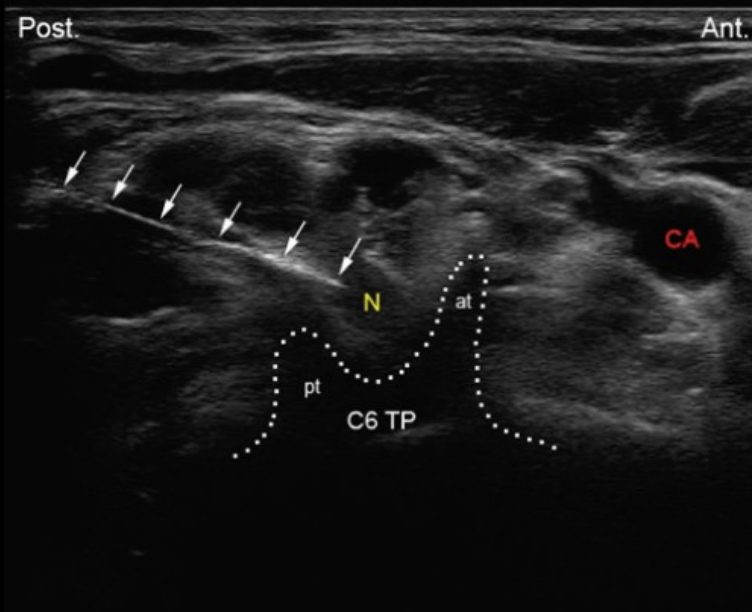
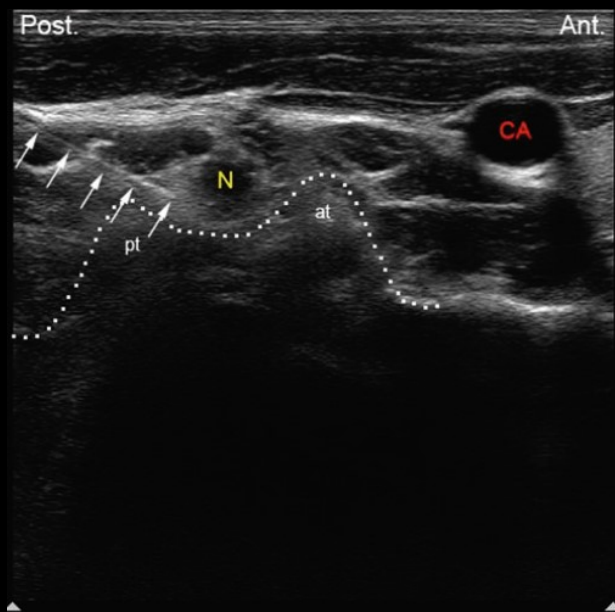


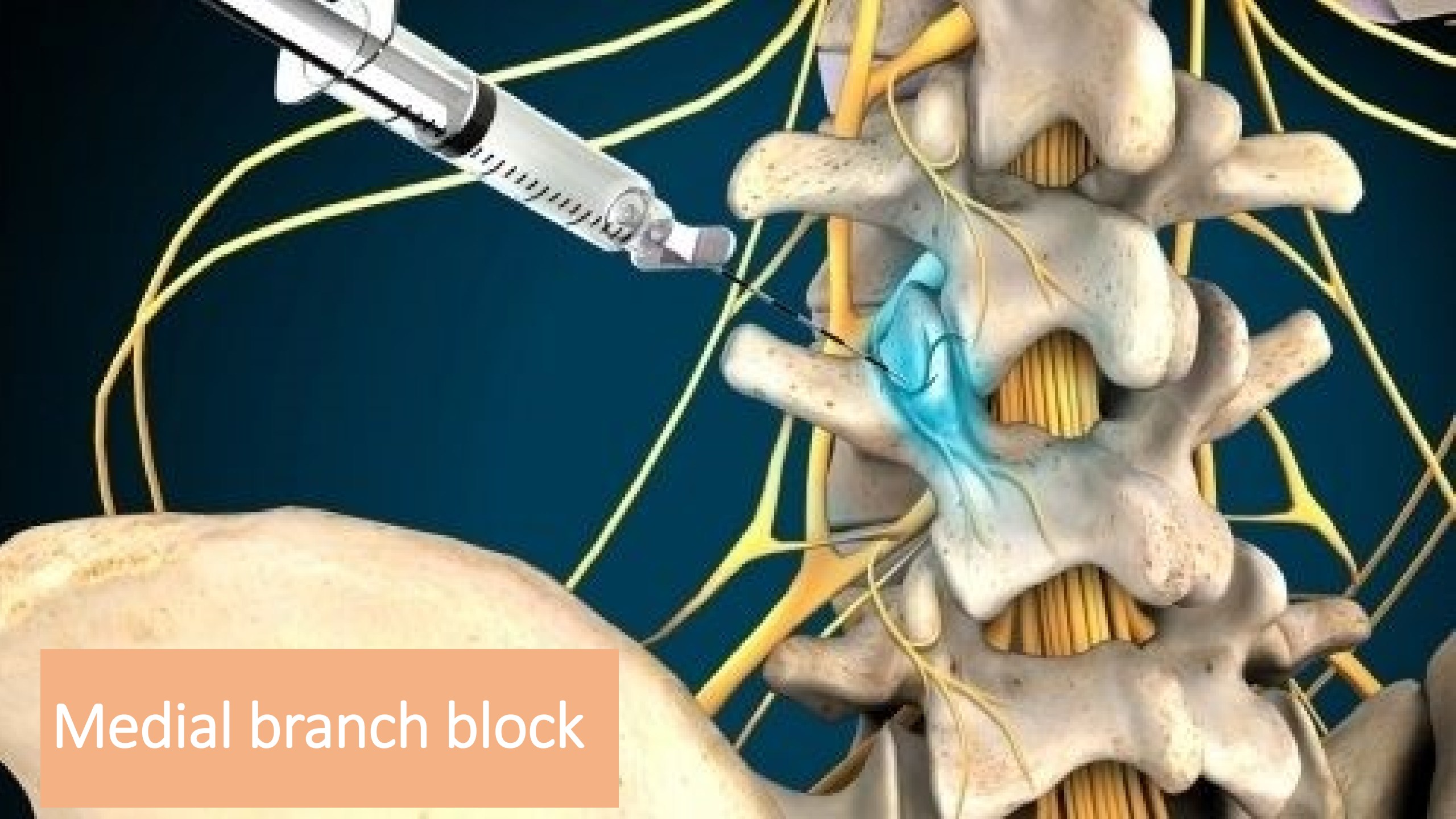
Pain management in the ambulatory setting



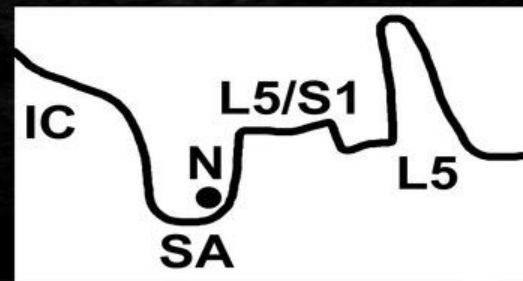
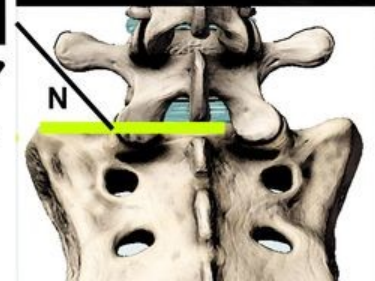
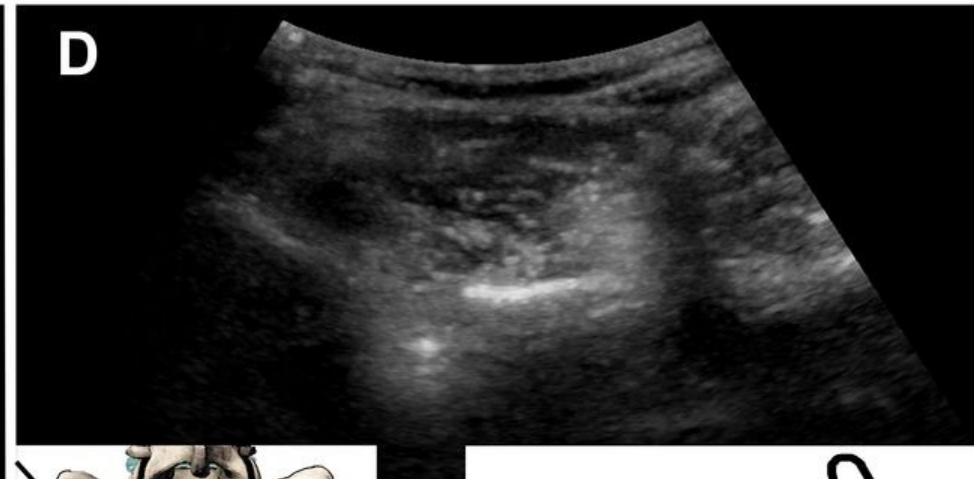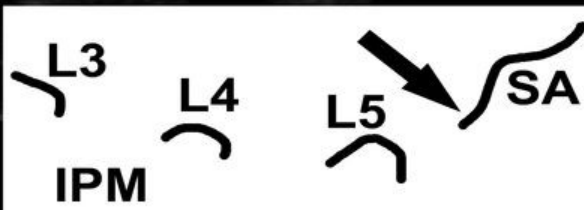
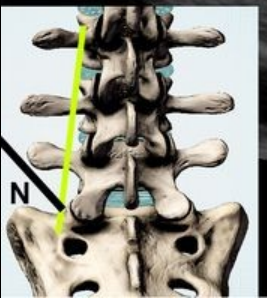
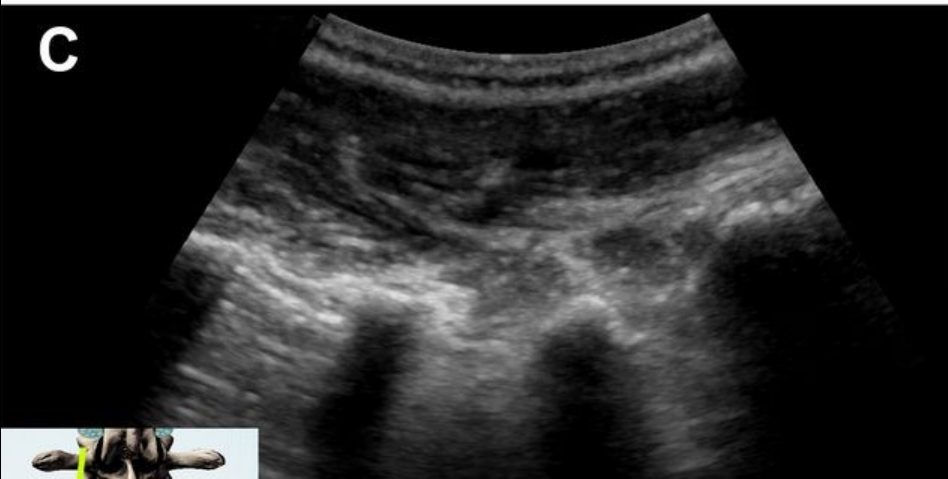
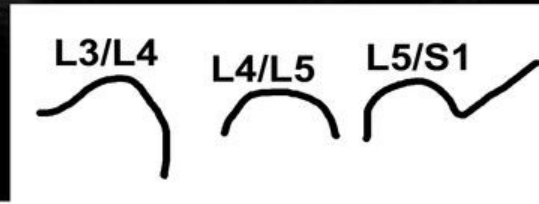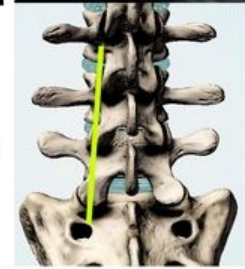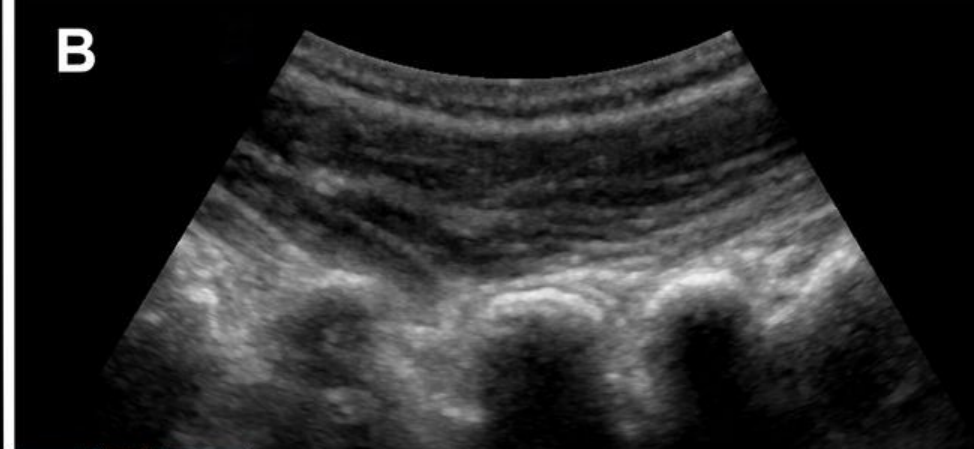
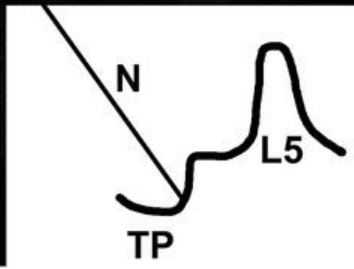
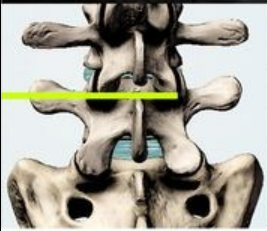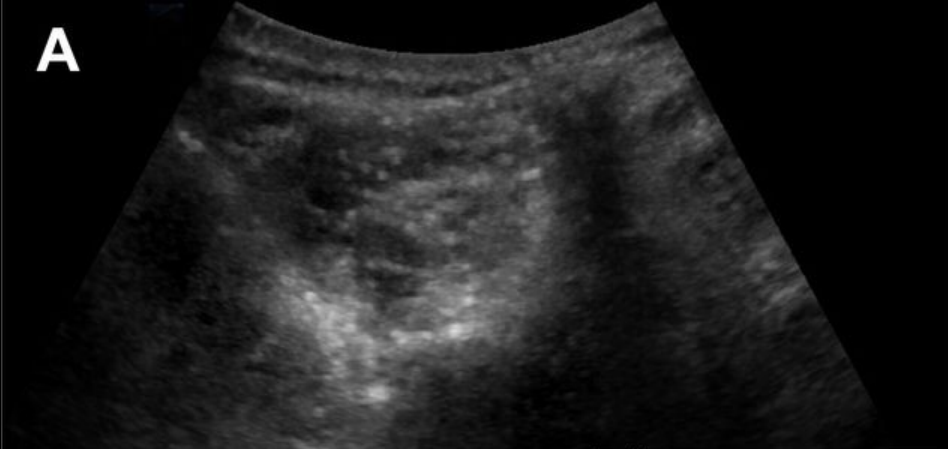


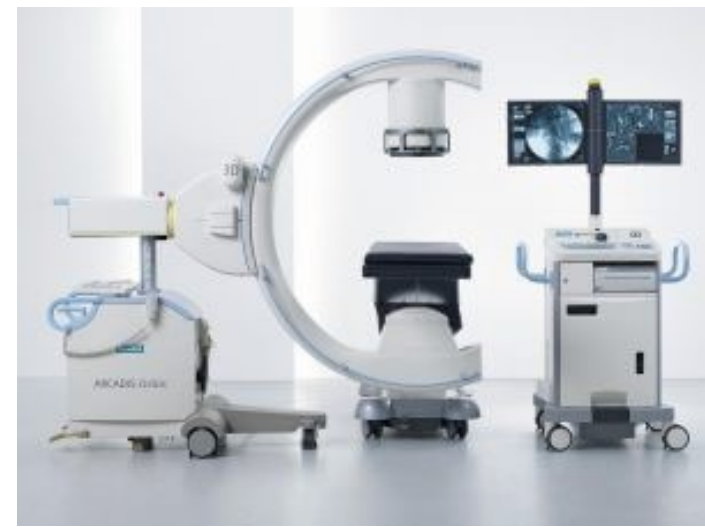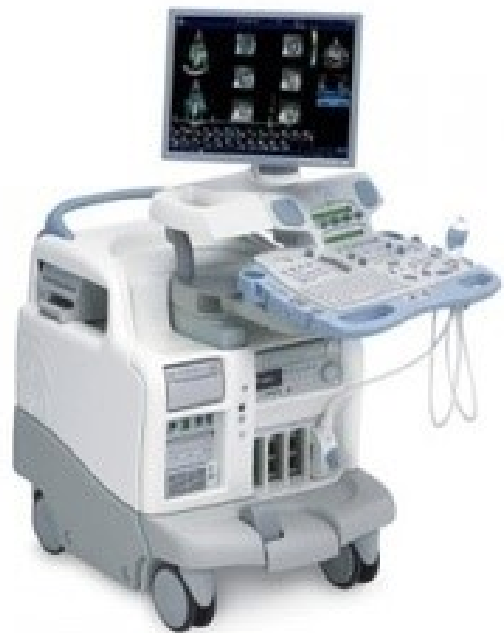A

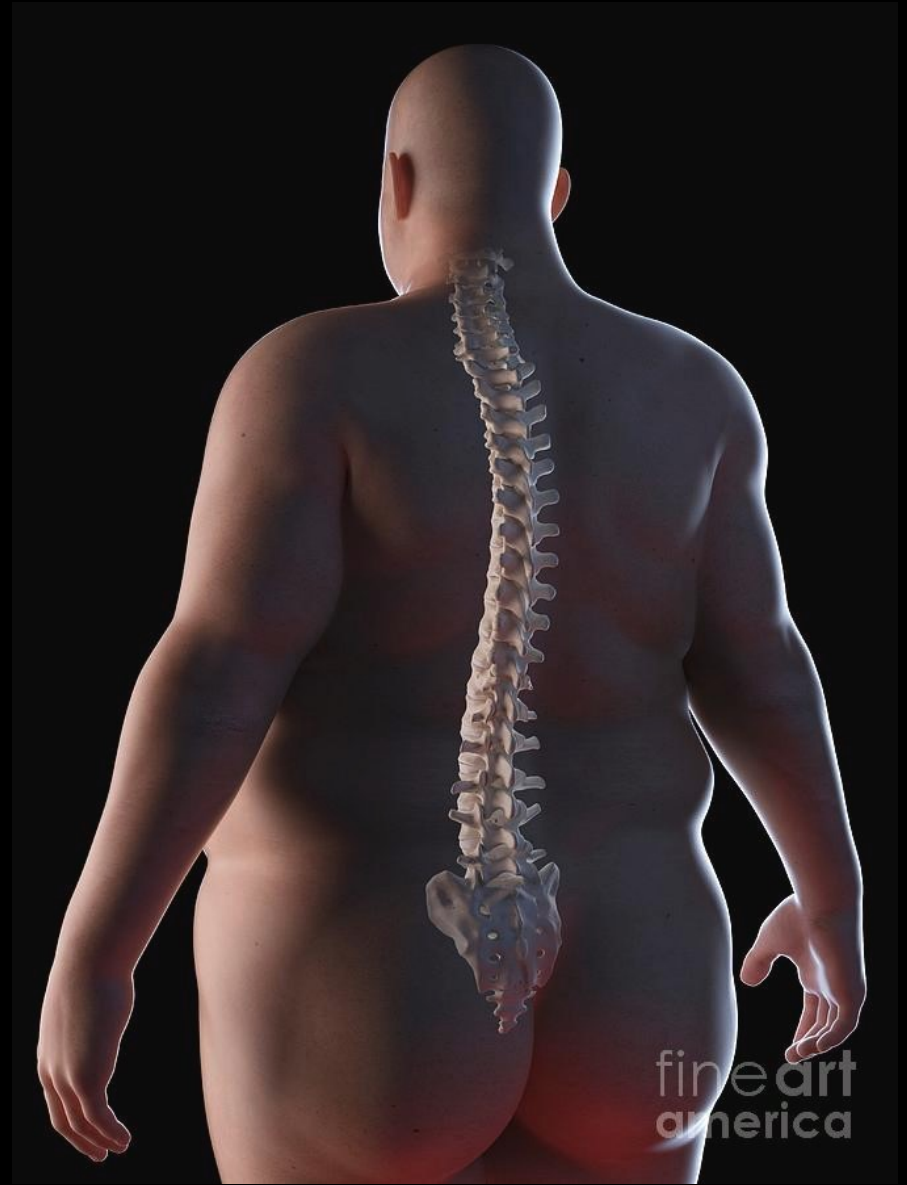
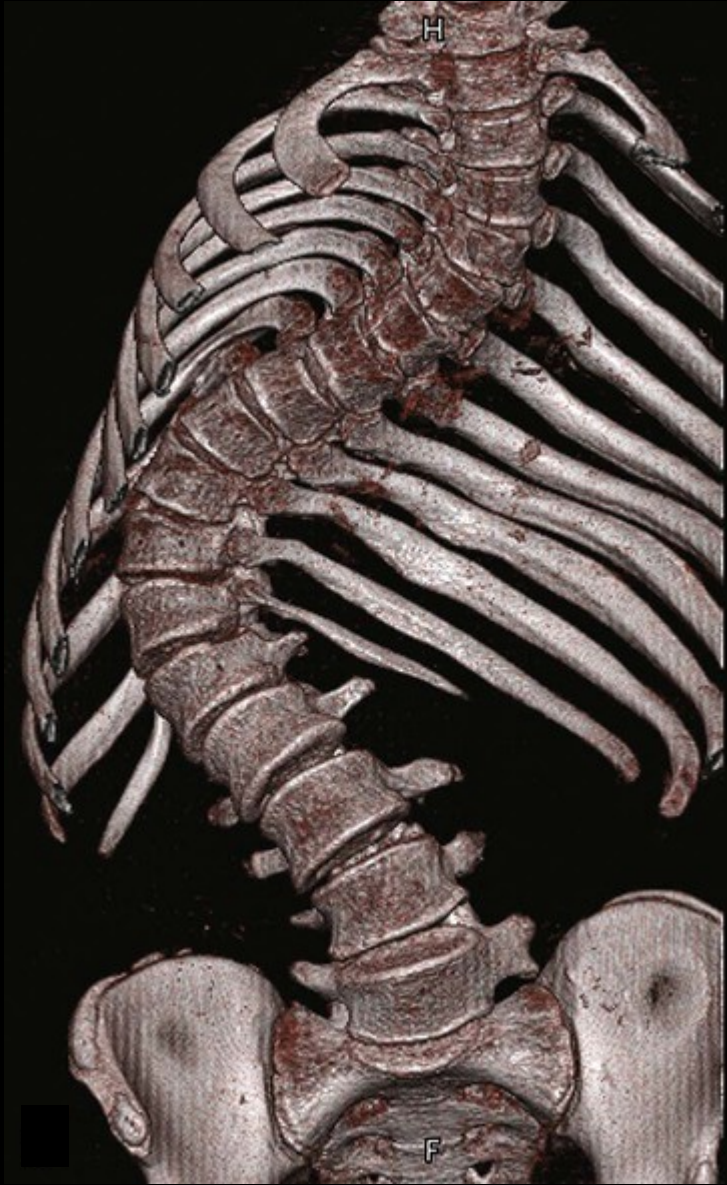
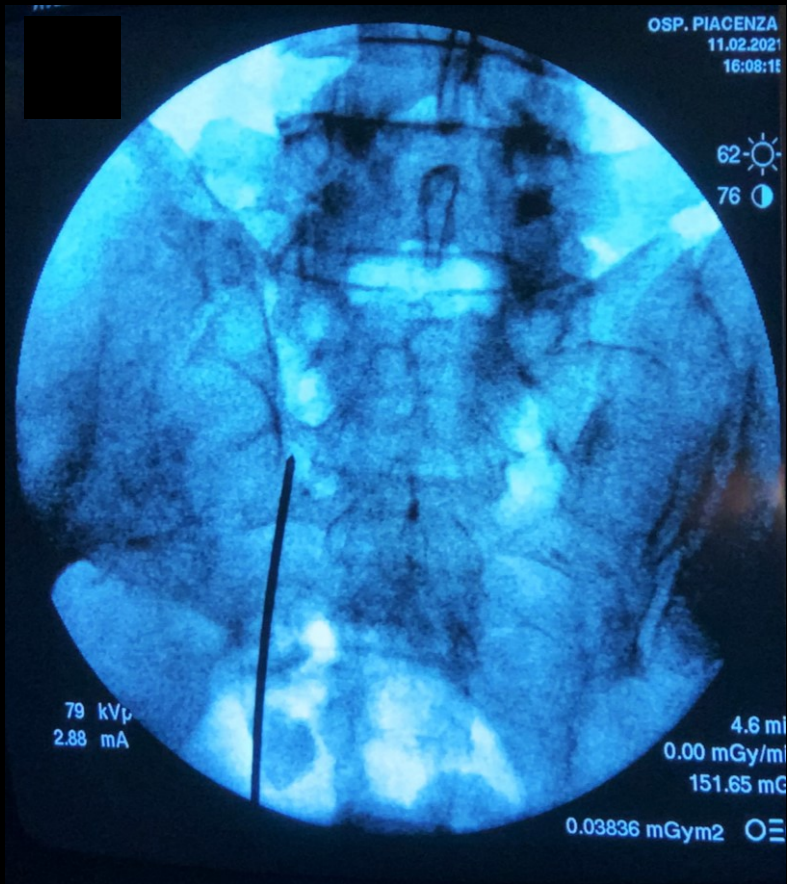


Medial branch block









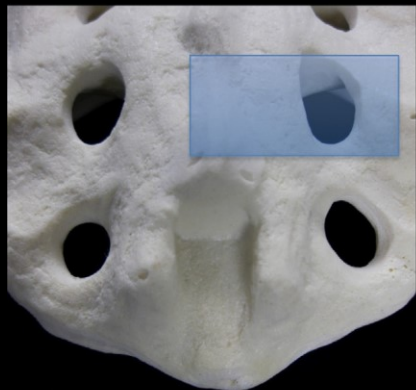
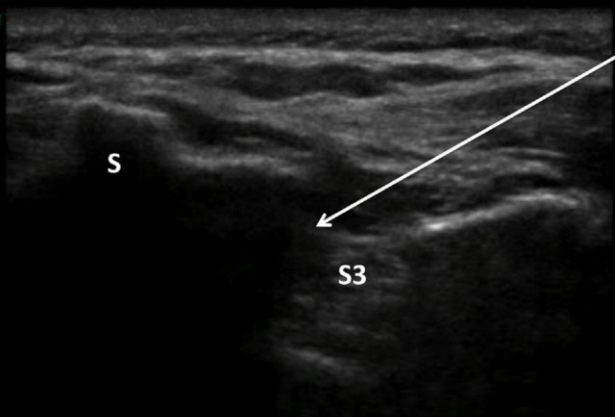
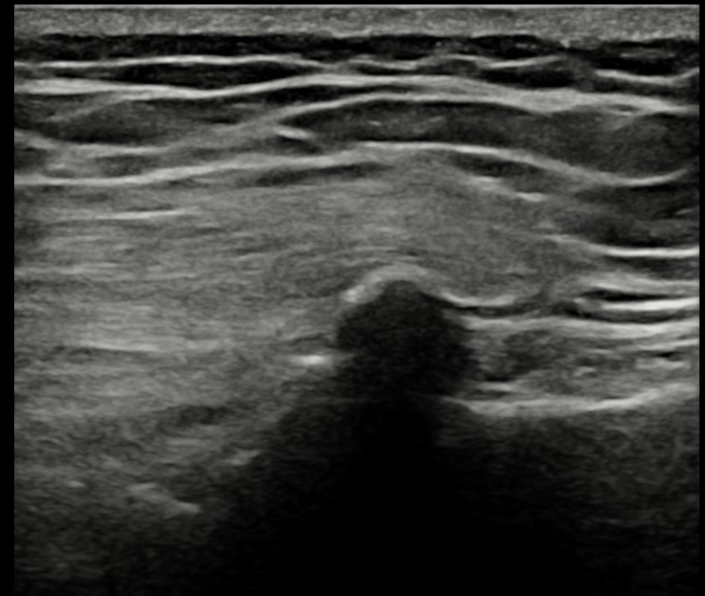
SAMSUNG

TIs 0.41 MI 0.98 11-02-2021
16:24:39

Superficial*
LA3-16AD
3.5 cm
35 Hz

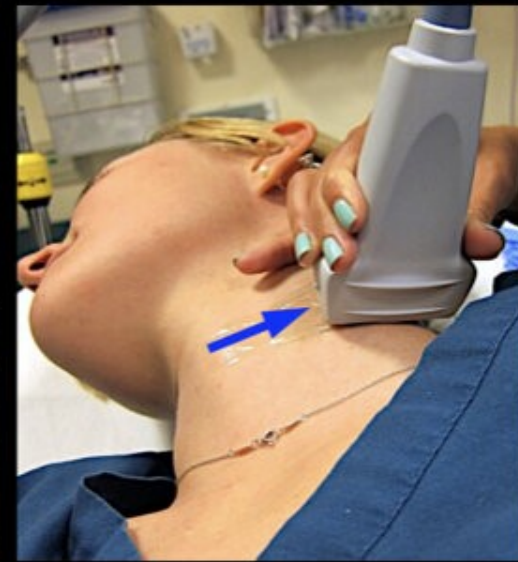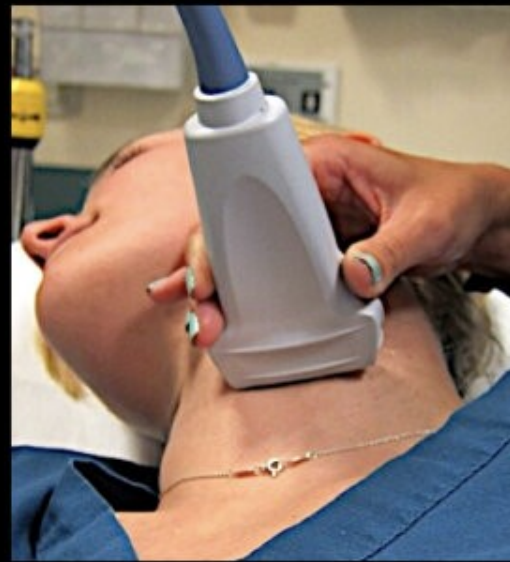SAMSUNG
HS40

[2D]
Res
Gn 48
DR 116
FA 7
P 90%



Interscalene Brachial Plexus Block

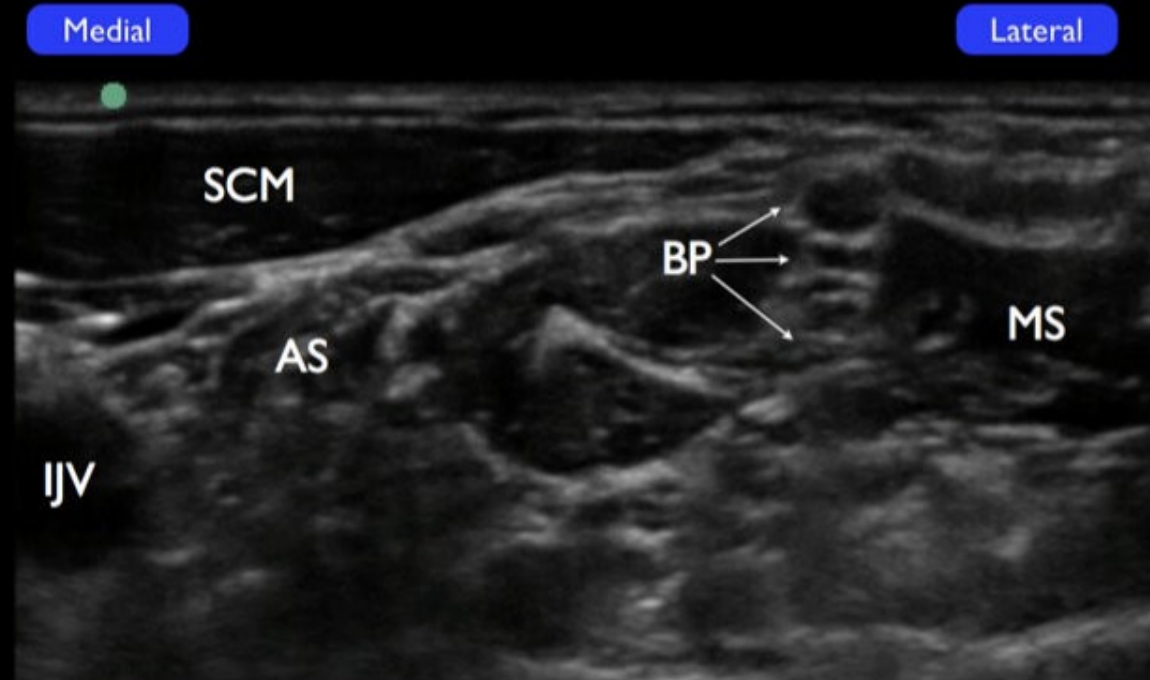
1) Find familiar landmarks (internal jugular vein (IJV) and carotid artery)

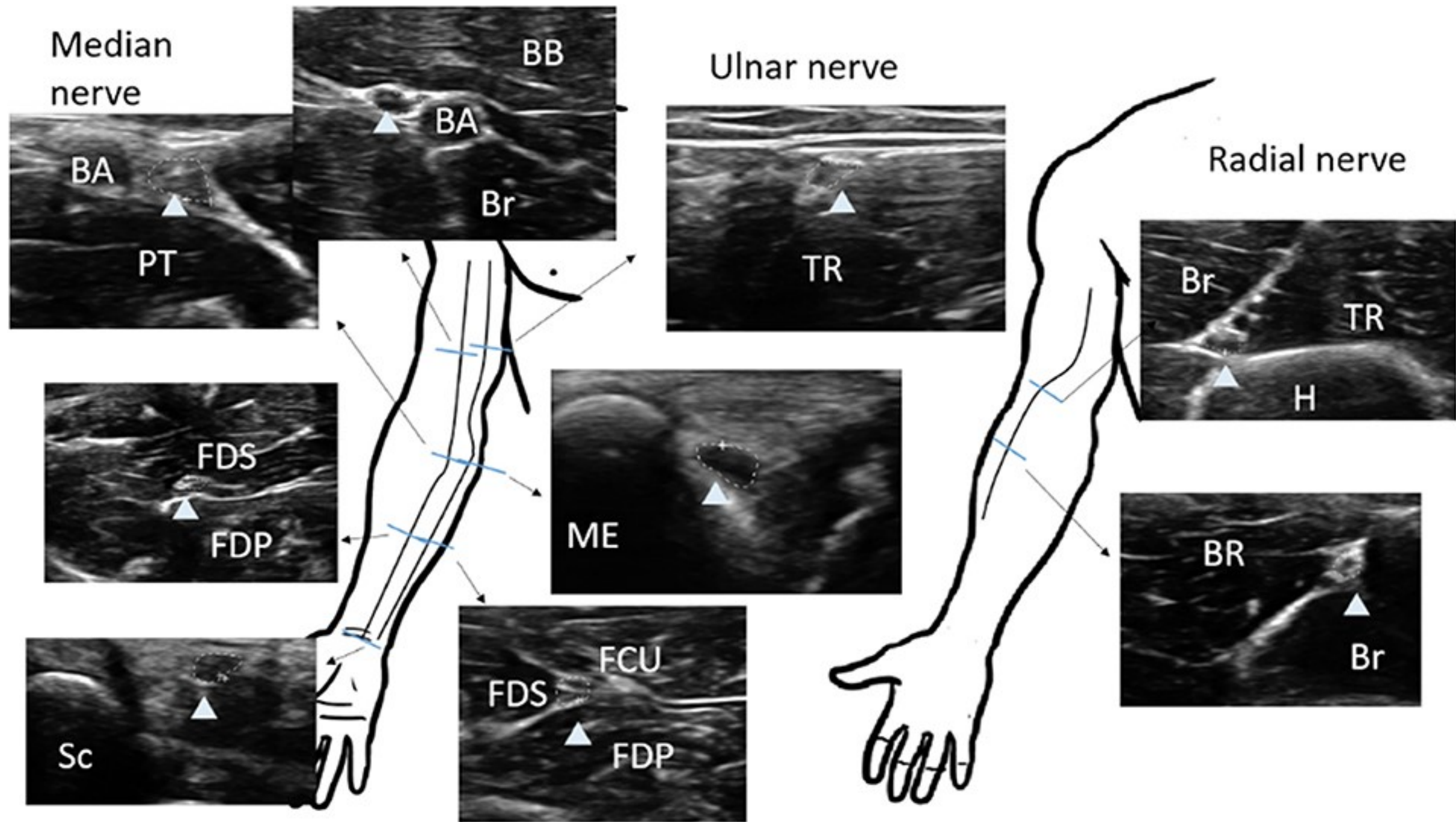


Move probe lateral

2) Approx at level of cricoid cartilage, move the probe lateral

3) Notice tapering sternocleidomastoid (SCM) + visualization of anterior scalene(AS) & middle scalene(MS) muscles

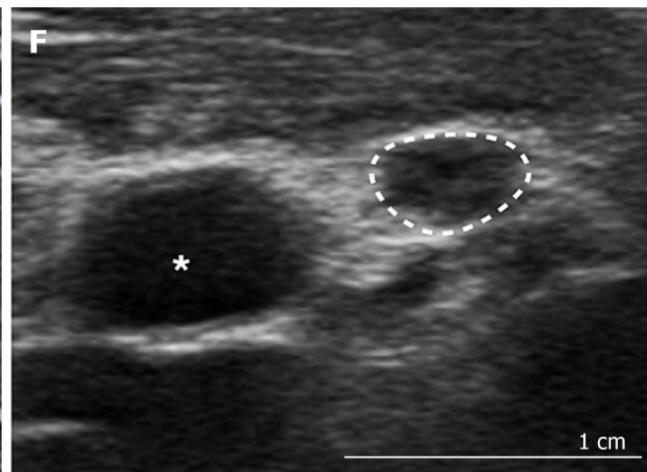
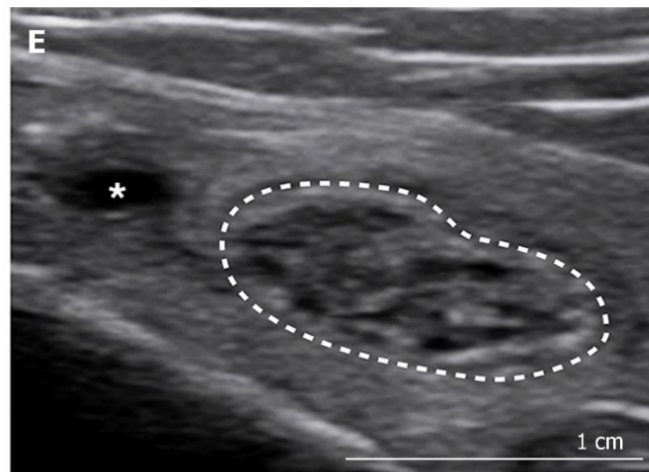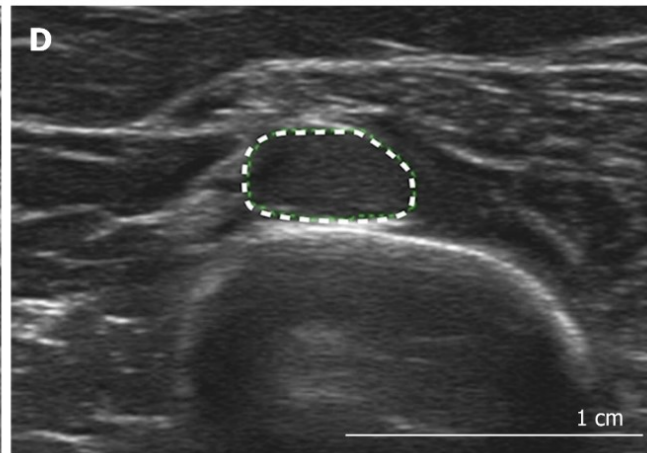
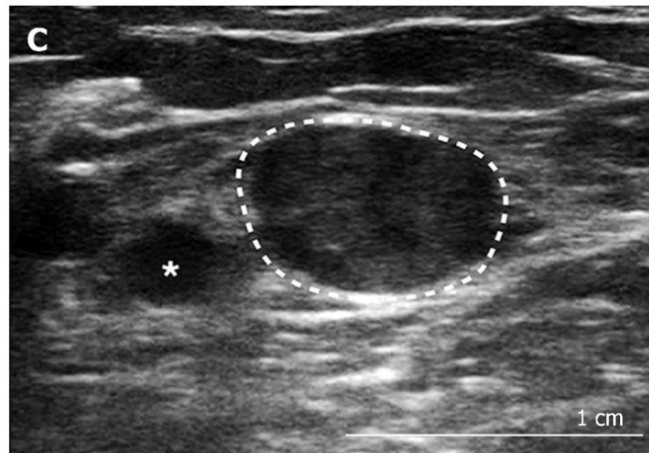
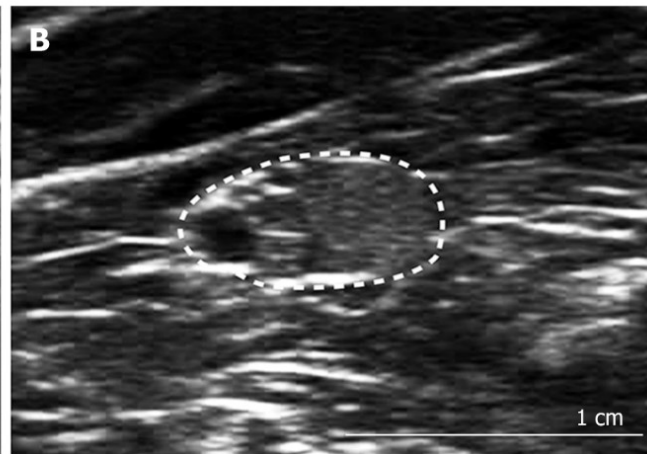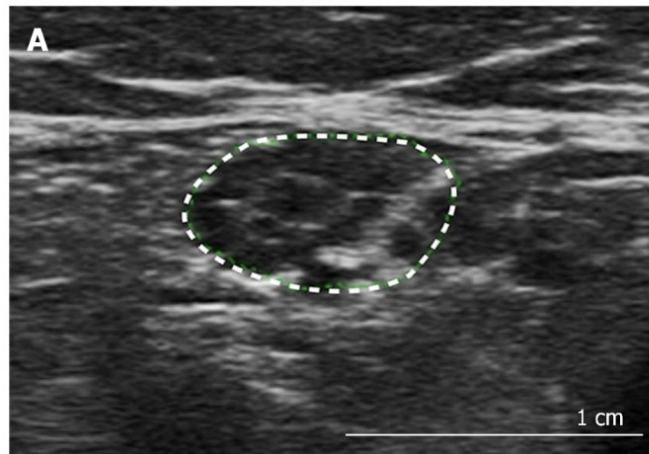


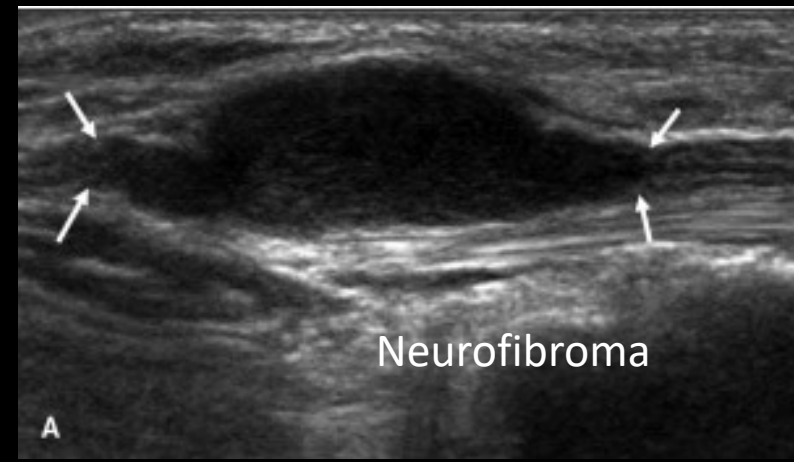
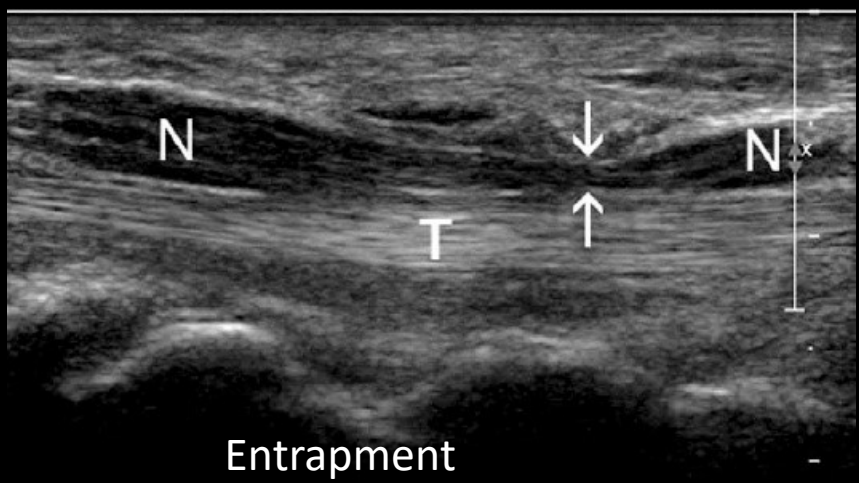
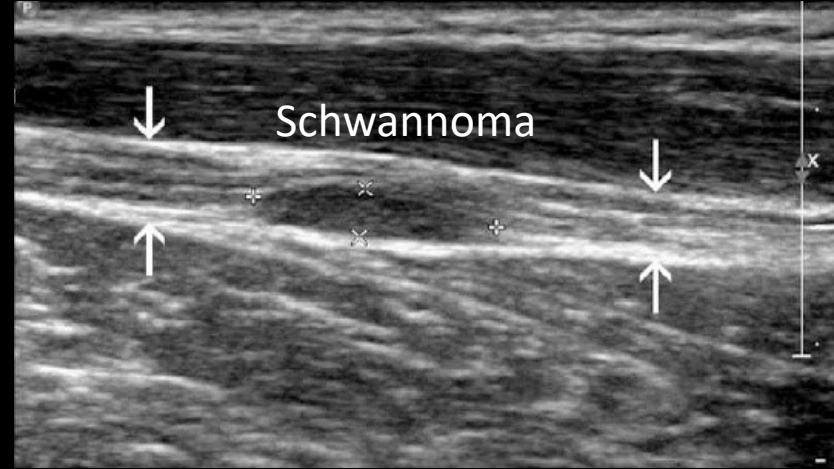
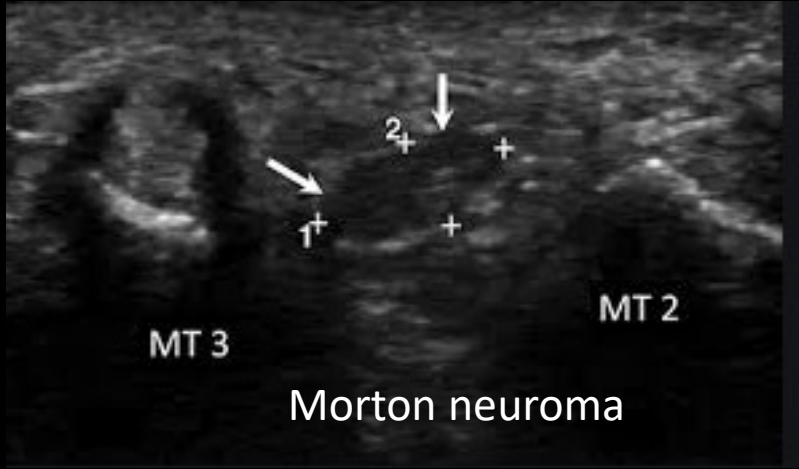


Nerve	Site	Mean	SD	Percentiles	Reference range*
				2.5th, 97.5th	
Median	Wrist	9.33	1.55	7, 13	7–13
	Forearm	6.31	1.49	4, 10	4–10
	Below-elbow	6.85	1.64	4, 11	4–11
	Antecubital fossa	8.96	2.41	4, 14	5–14
	Mid-arm	9.34	2.38	6, 15	6–15
	Axilla	9.88	2.52	6, 16	6–16
	WFR	1.57	2.38	2, 4	1–2.4
Ulnar	Wrist	5.09	1.29	3, 8	3–8
	Arterial split	5.74	1.42	4, 9	4–9
	CT outlet	6.93	1.79	4, 11	4–11
	ME	7.31	1.69	5, 11	5–11
	Proximal 2 cm to ME	7.11	1.64	4, 10	4–10
	Mid-arm	6.37	1.56	4, 11	4–11
	Axilla	6.94	1.97	4, 12	4–12
Radial	Above SG	7.02	1.87	4, 11	4–11
	SG	6.81	1.75	4, 11	4–11
	Antecubital fossa	7.26	1.70	5, 11	5–11
SRS	Proximal forearm	2.50	0.86	1, 4	1–4
PIN	Proximal forearm	2.02	0.69	1, 3	1–3
MACN	Mid-arm	3.30	1.13	2, 7	2–7
LACN	Elbow	3.28	1.29	2, 6	2–6
MC	Axilla	3.81	1.28	2, 7	2–7

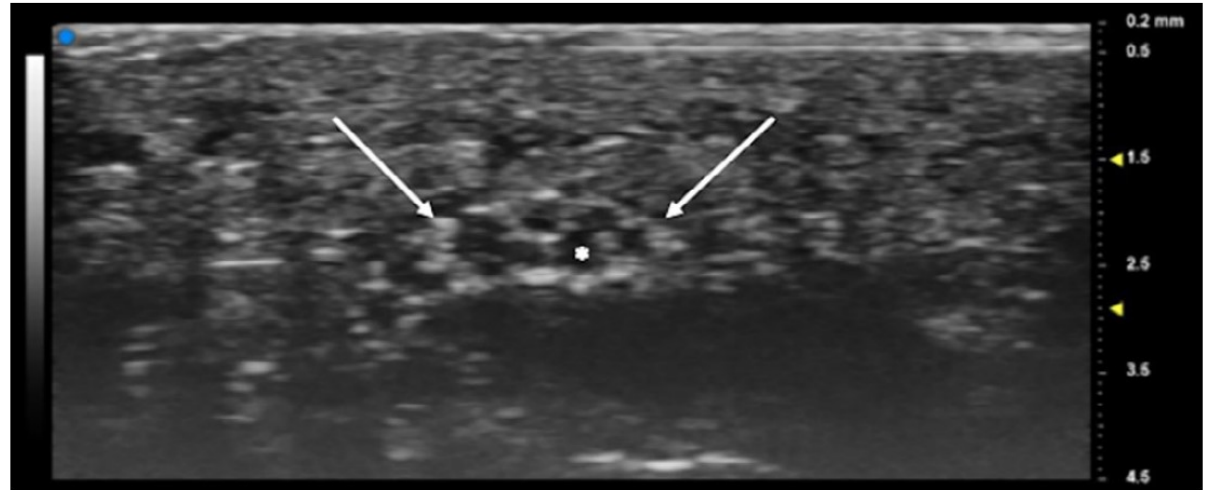
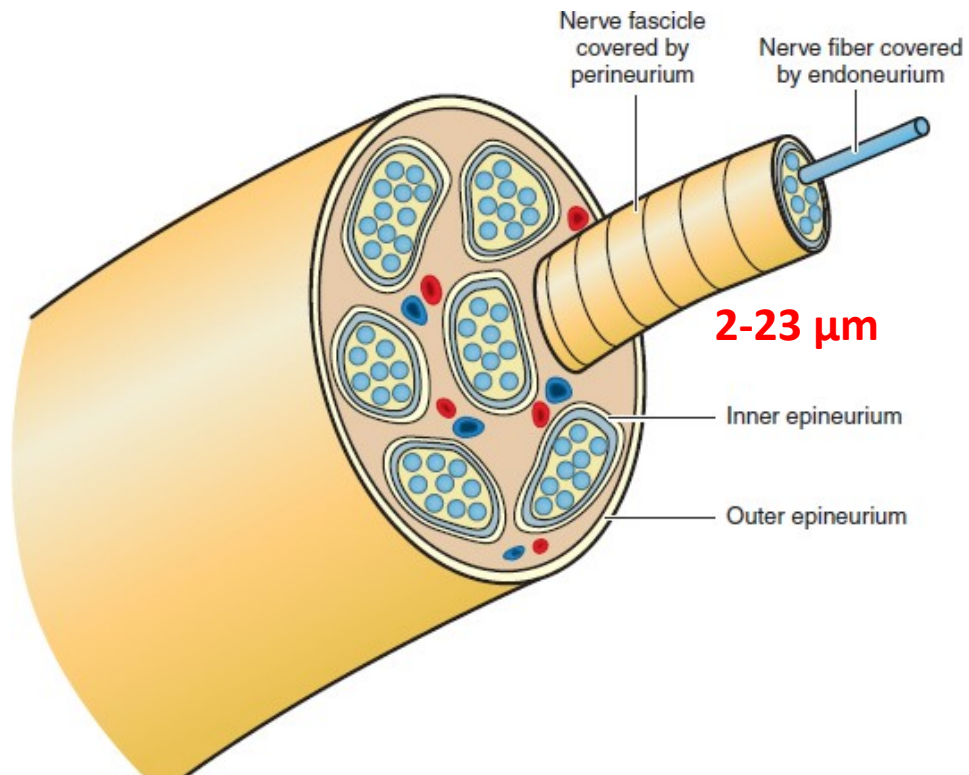
All values are in mm² except WFR. The reference range is determined as the mean \pm 2 SD for normally distributed data and from 97.5th percentile for non-normally distributed data. CSA = cross-sectional area, CT = cubital tunnel, HRUS = high-resolution ultrasonography, LACN = lateral antebrachial cutaneous nerve, MACN = medial antebrachial cutaneous nerve, MC = musculocutaneous nerve, ME = medial epicondyle, PIN = posterior interosseous nerve, SD = standard deviation, SG = spiral groove, SRS = superficial radial sensory, WFR = wrist-to-forearm median nerve CSA ratio.

The reference range* is determined ~





70 MHz linear array transducer

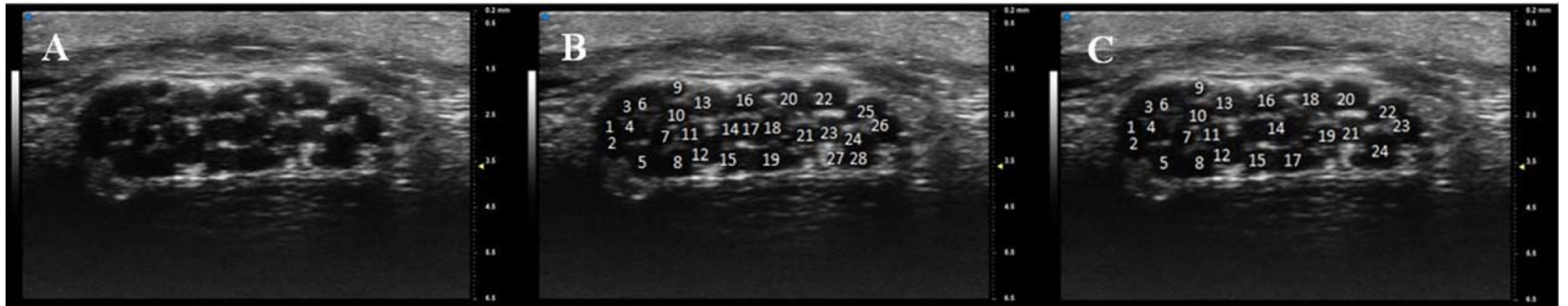


ULTRAHIGH-FREQUENCY ULTRASOUND OF FASCICLES IN THE MEDIAN NERVE AT THE WRIST

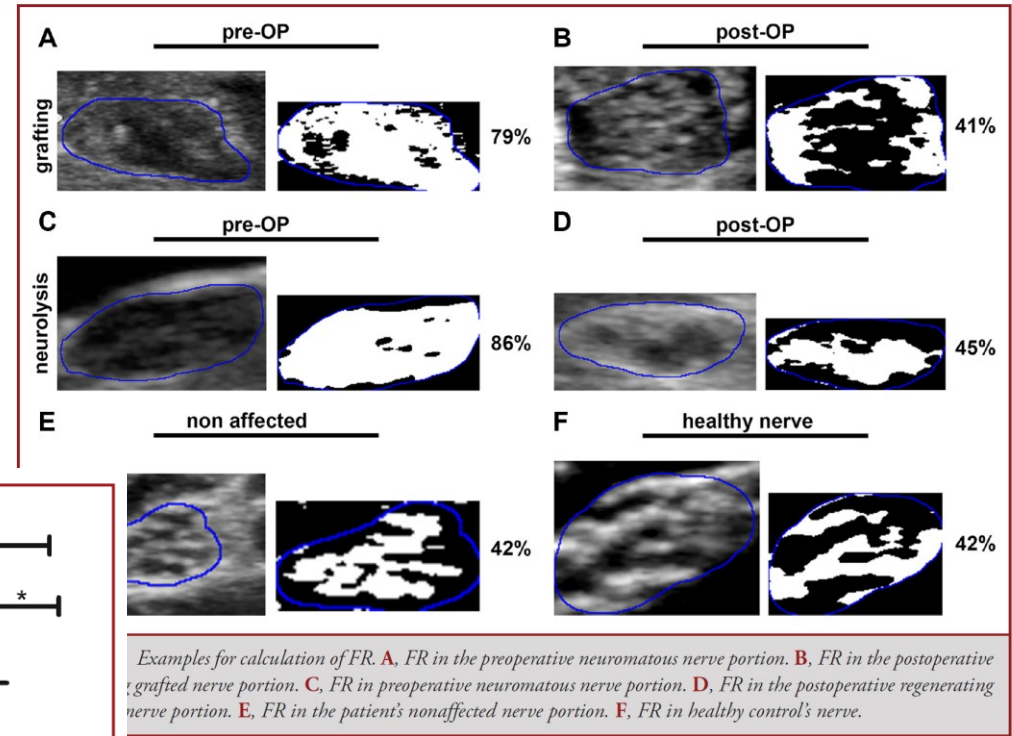
MICHAEL S. CARTWRIGHT, MD, MS, VANESSA BAUTE, MD, JAMES B. CARESS, MD, and FRANCIS O. WALKER, MD

Department of Neurology, Wake Forest School of Medicine, Medical Center Blvd., Winston-Salem, NC, USA 27157

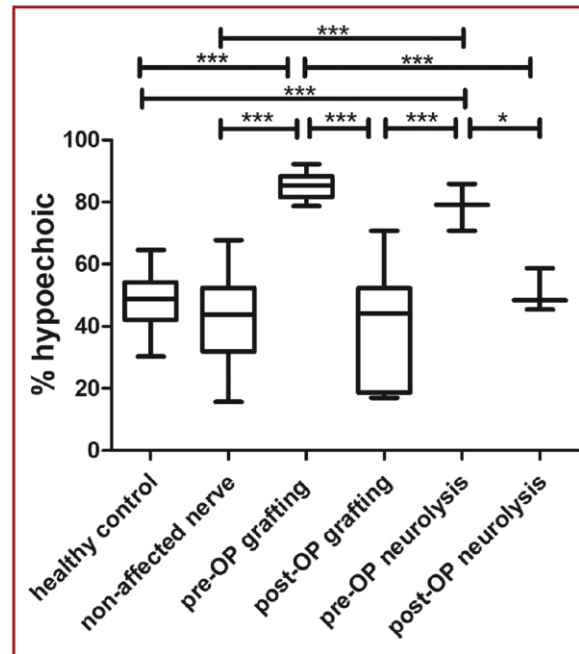
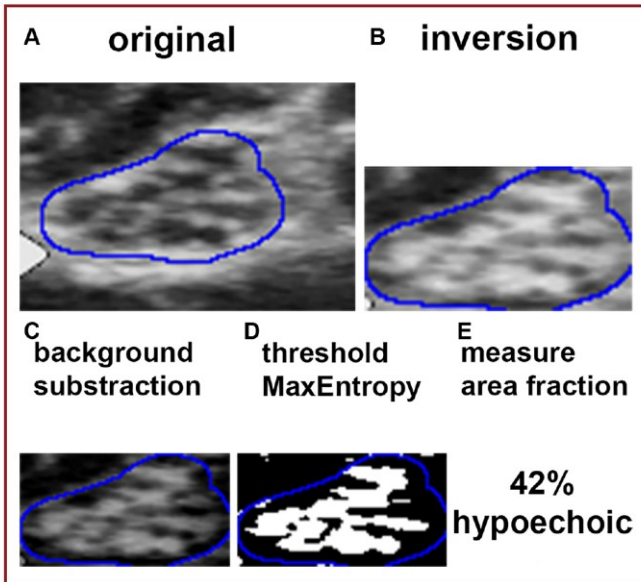
Accepted 14 February 2017



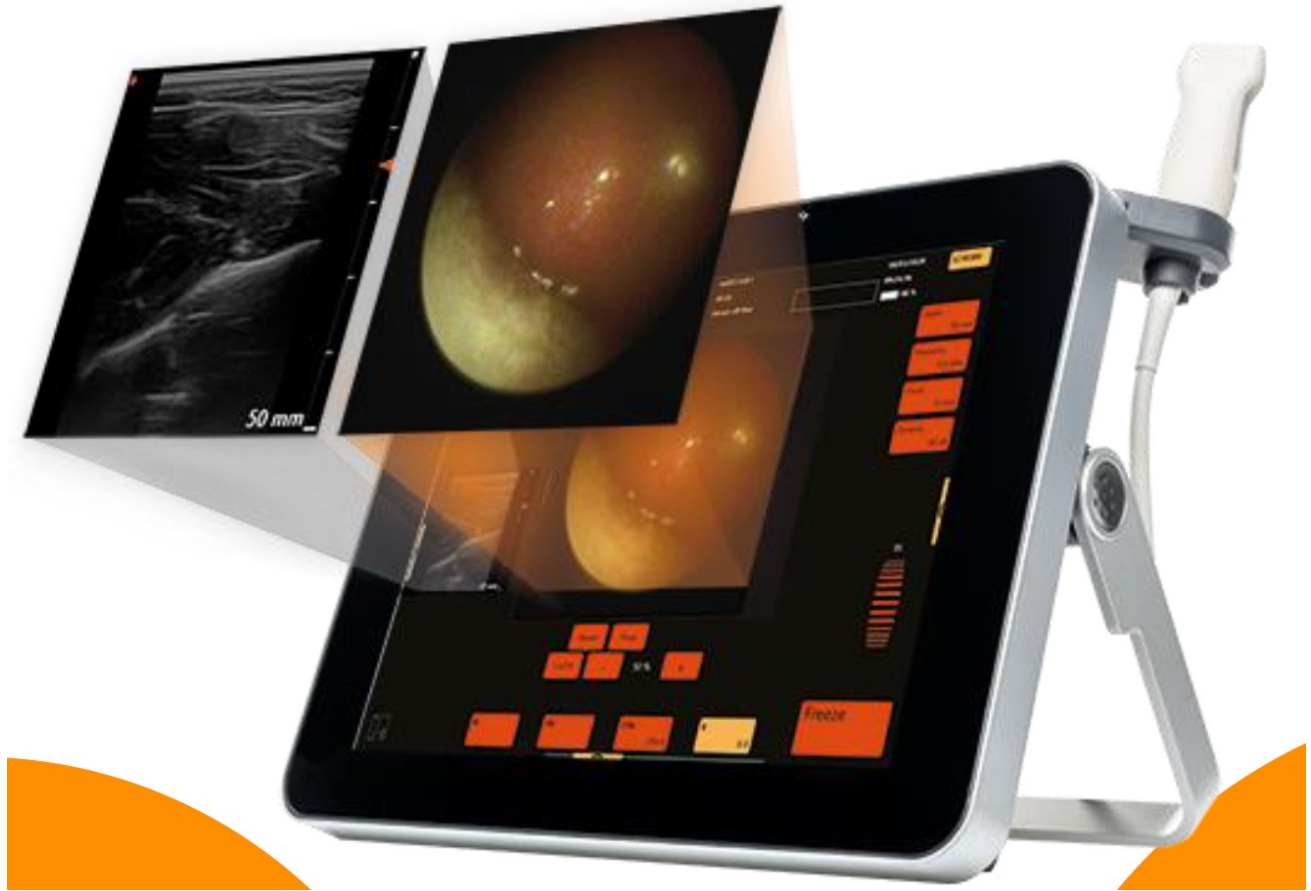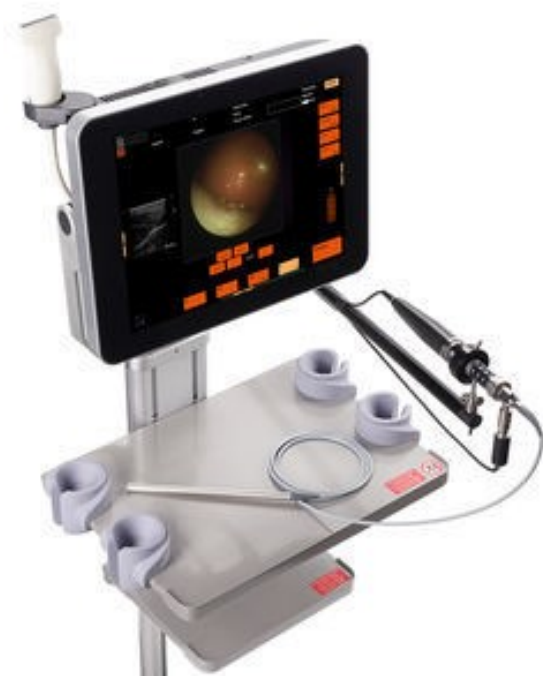Fascicular Ratio Pilot Study: High-Resolution Neurosonography—A Possible Tool for Quantitative Assessment of Traumatic Peripheral Nerve Lesions Before and After Nerve Surgery



Examples for calculation of FR. **A**, FR in the preoperative neuromatous nerve portion. **B**, FR in the postoperative grafted nerve portion. **C**, FR in preoperative neuromatous nerve portion. **D**, FR in the postoperative regenerating nerve portion. **E**, FR in the patient's nonaffected nerve portion. **F**, FR in healthy control's nerve.

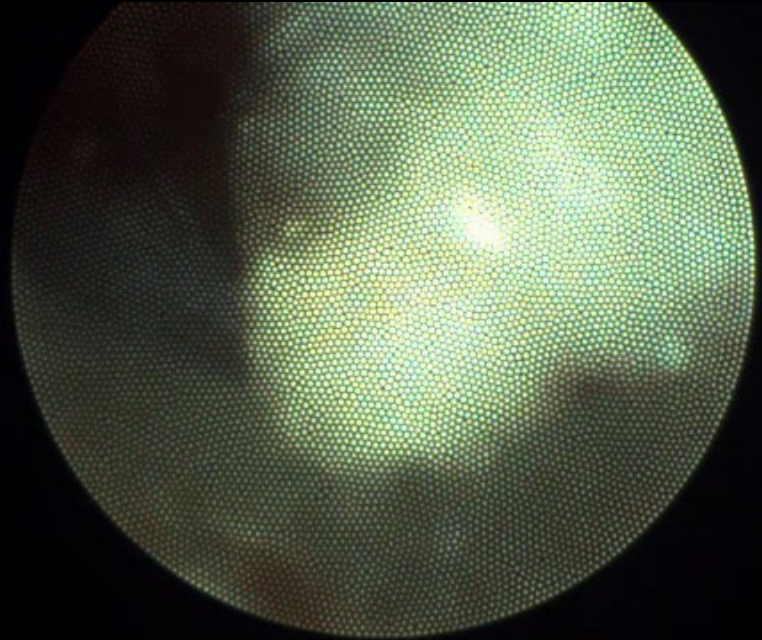


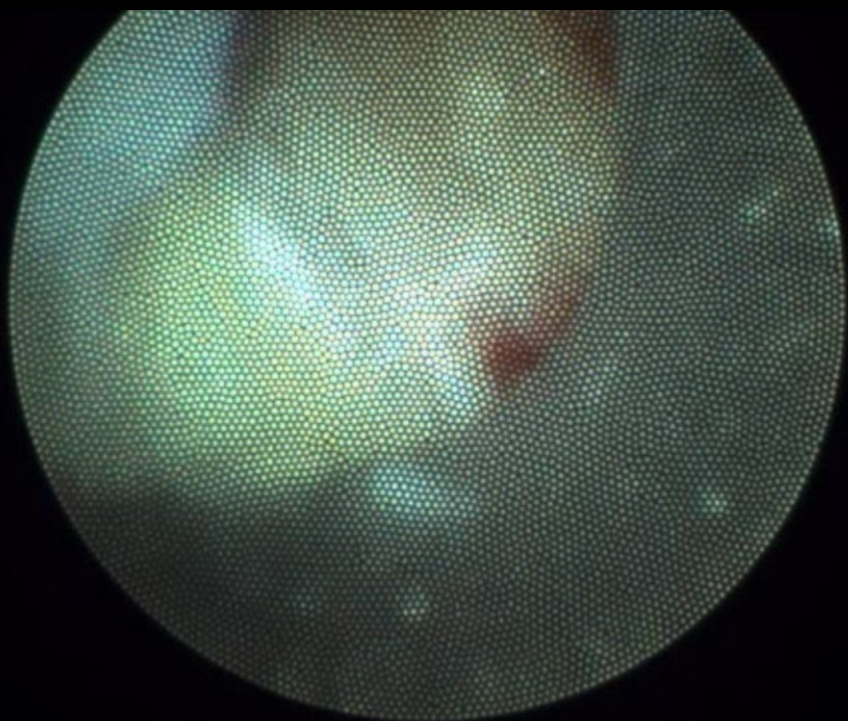Microendoscopy






Microendoscope

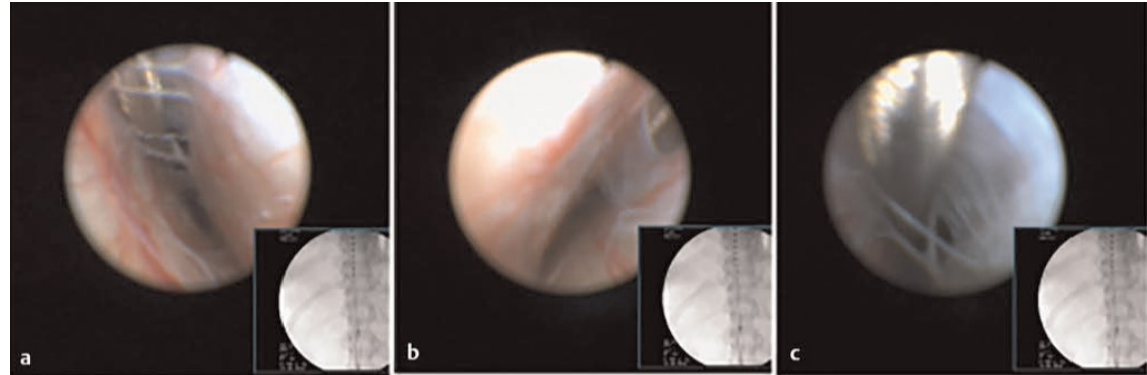
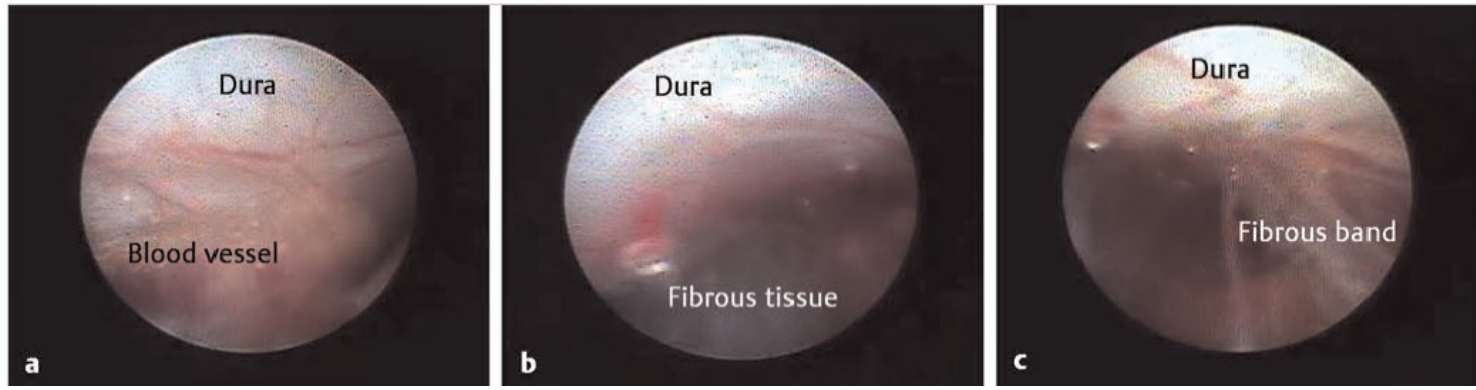
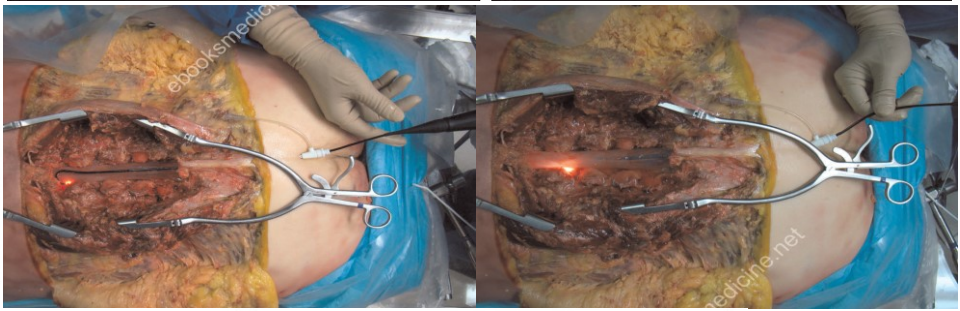
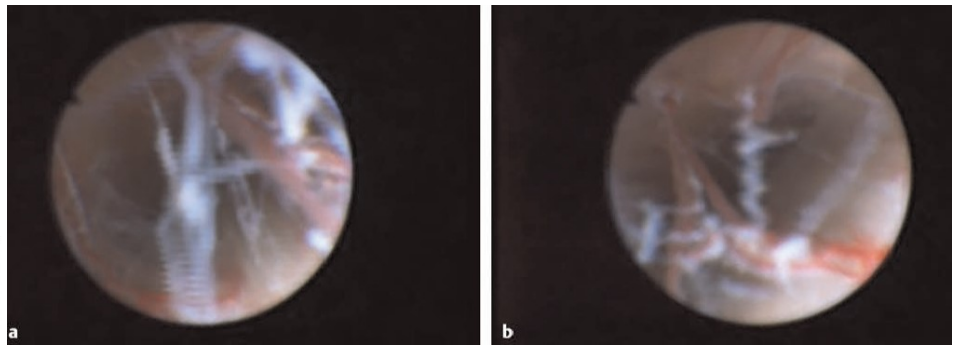
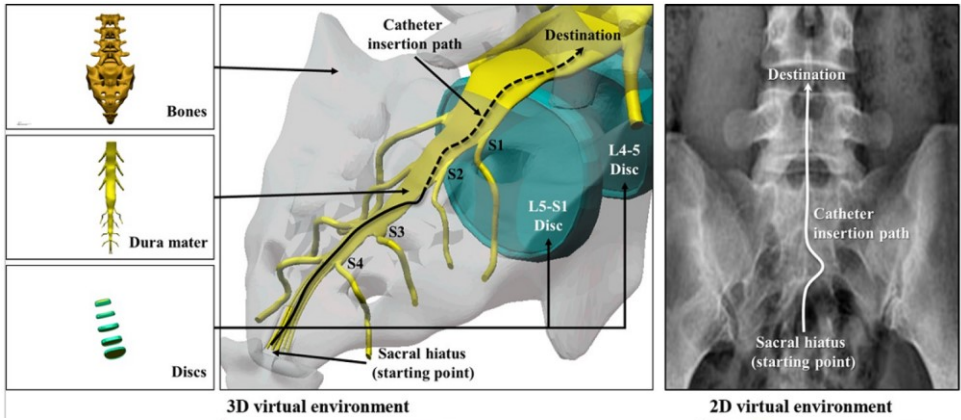


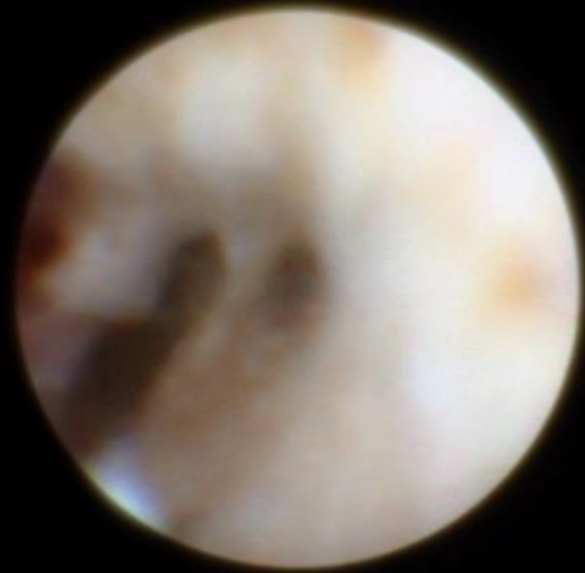


A blurred background image showing several surgeons in blue scrubs and masks, focused on a surgical procedure in an operating room. The text is overlaid in the center of the image.

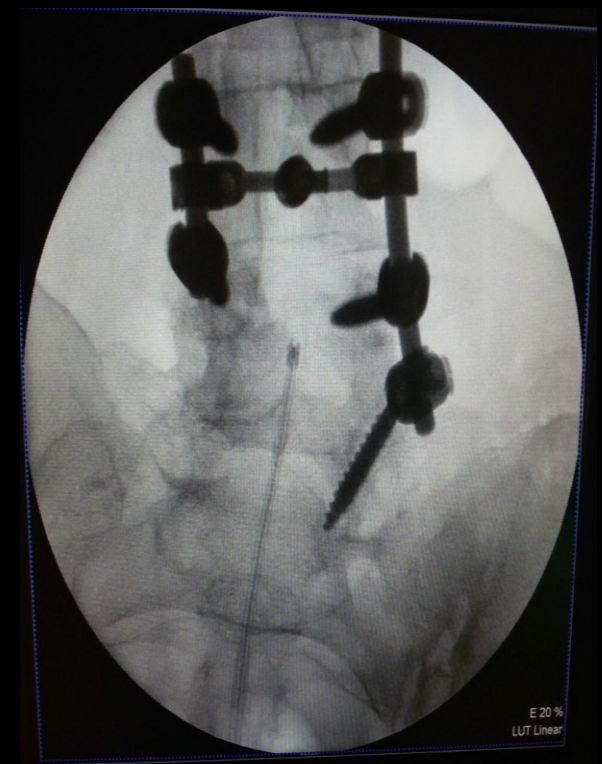Interventional and minimally invasive pain management

Epiduroscopy

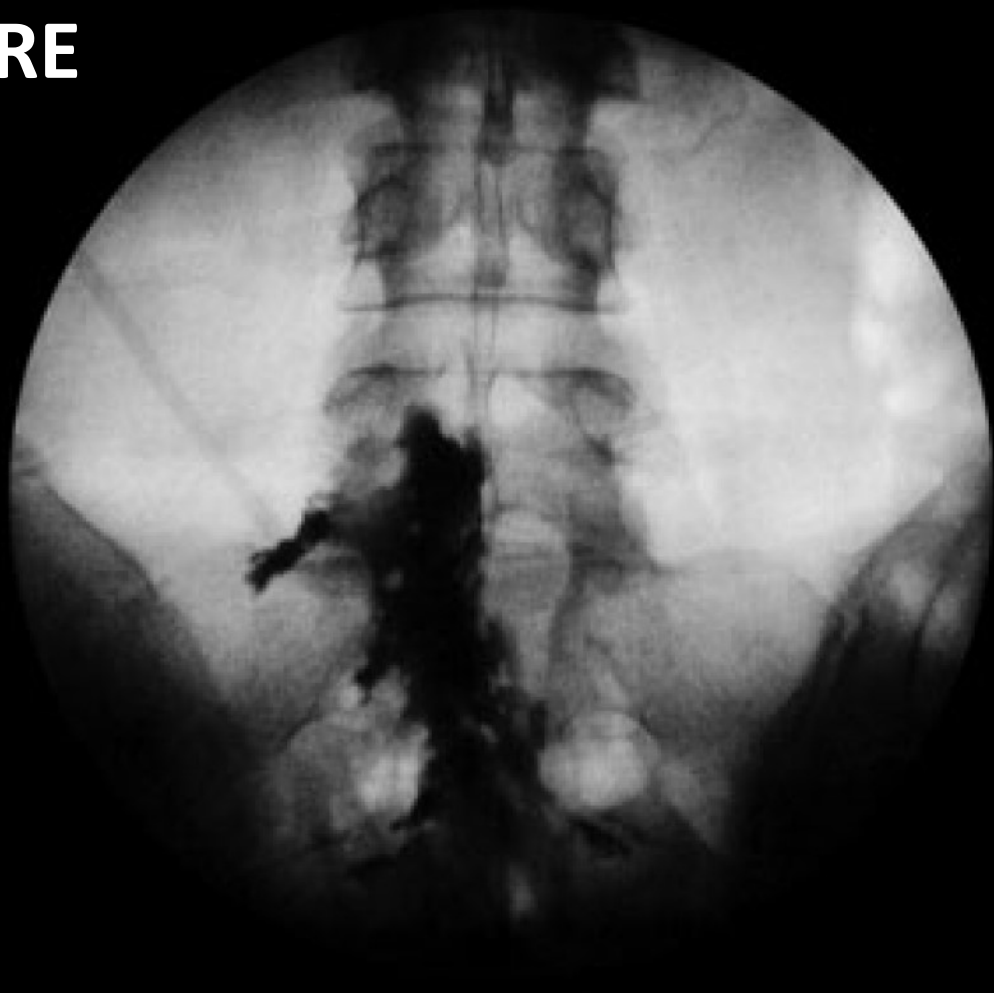



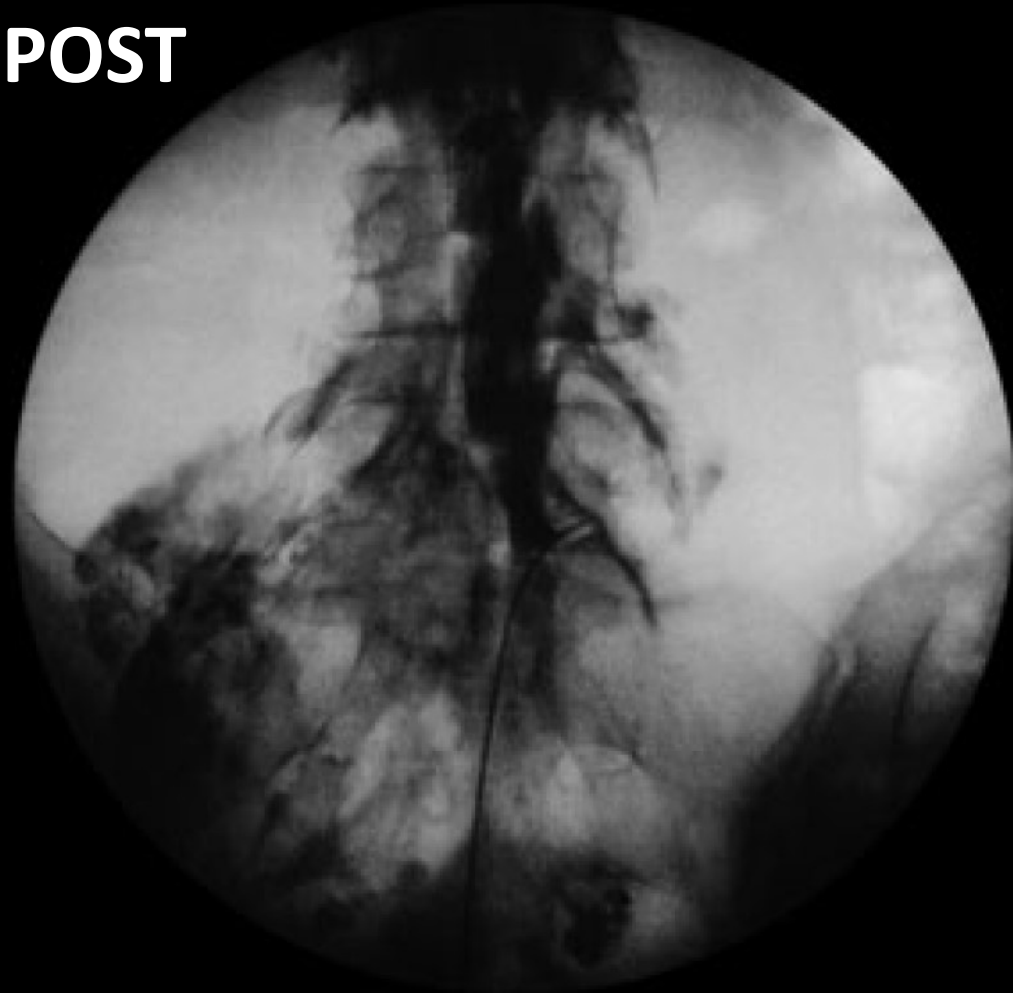
FLEX FILTER



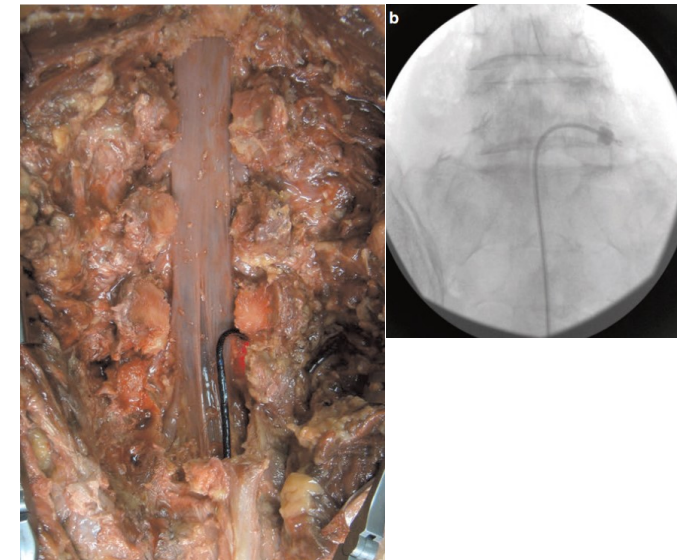
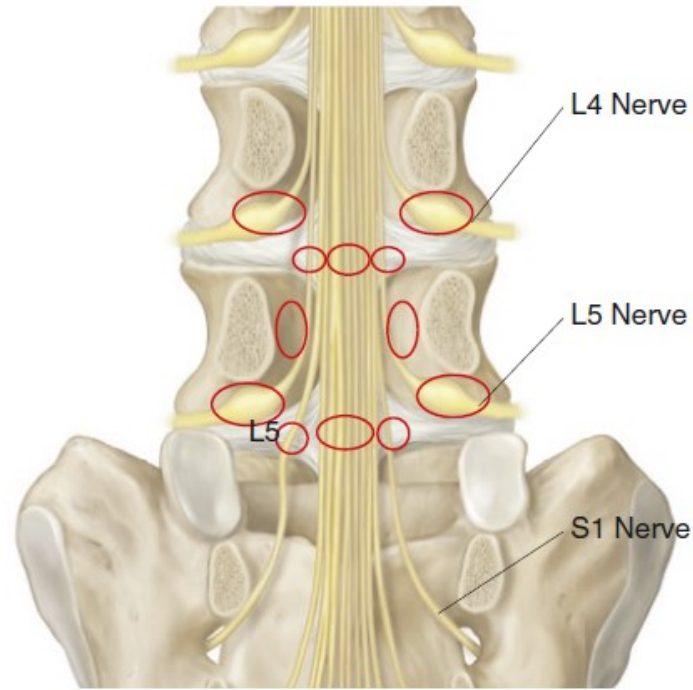

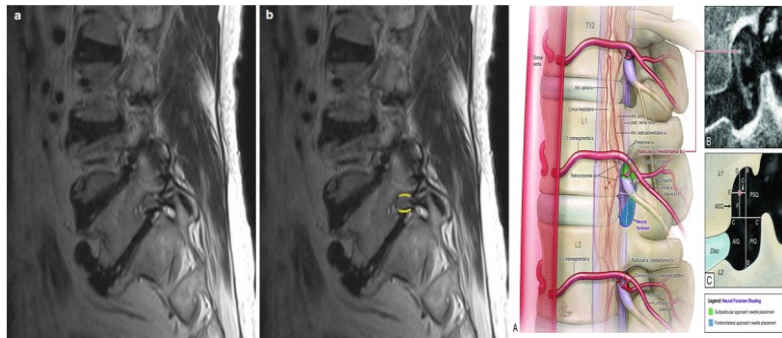
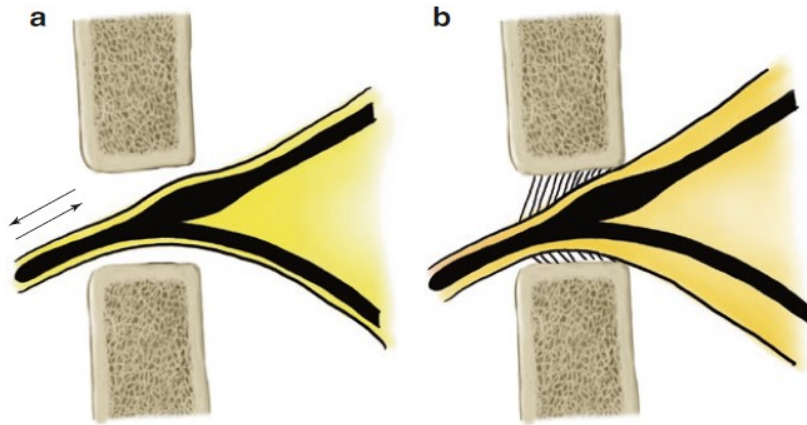
PRE

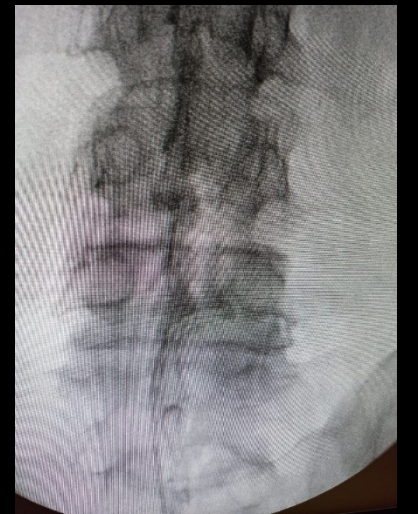
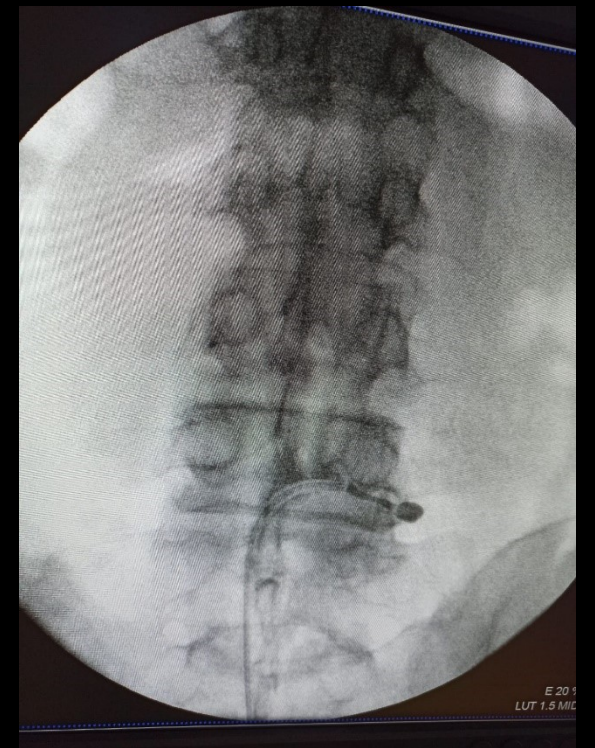
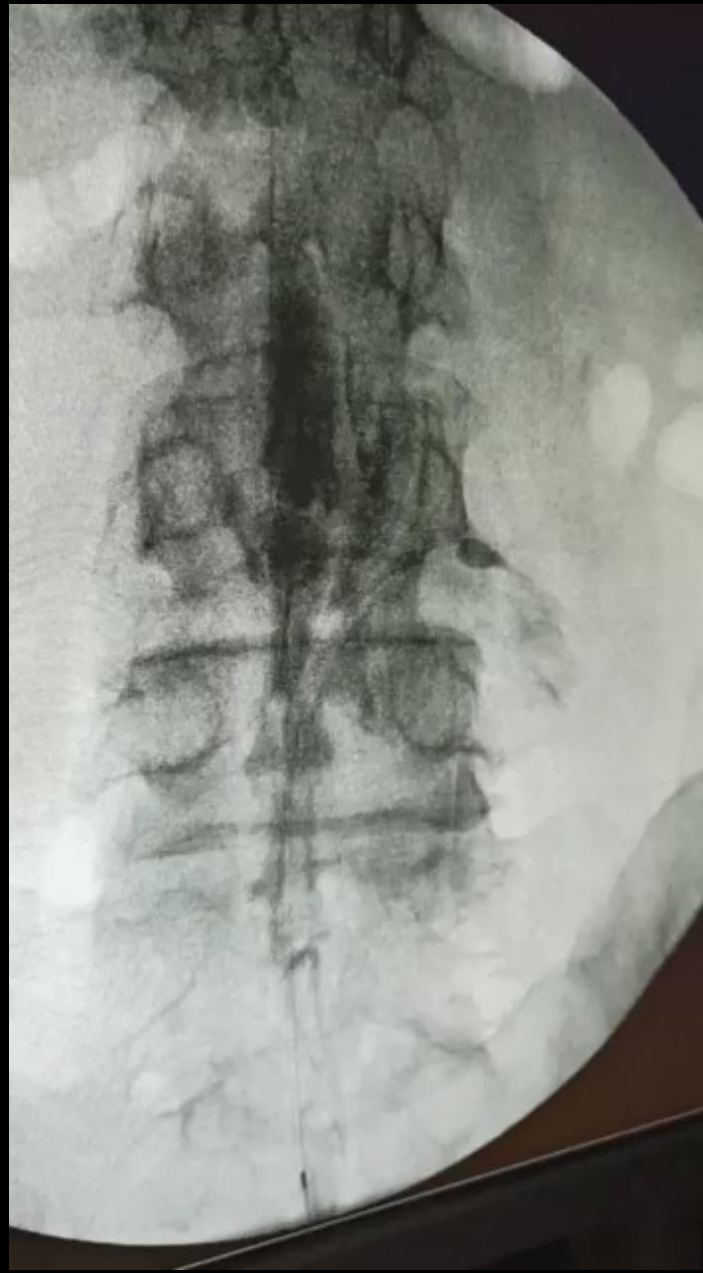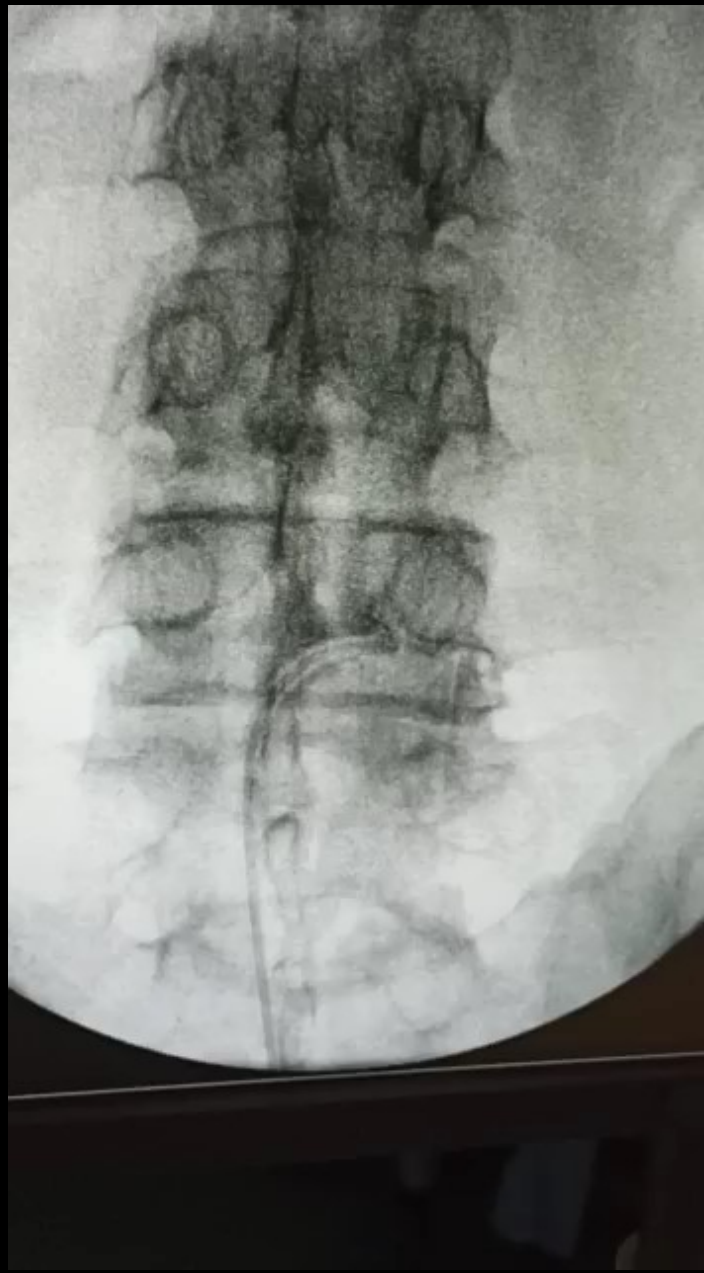


POST

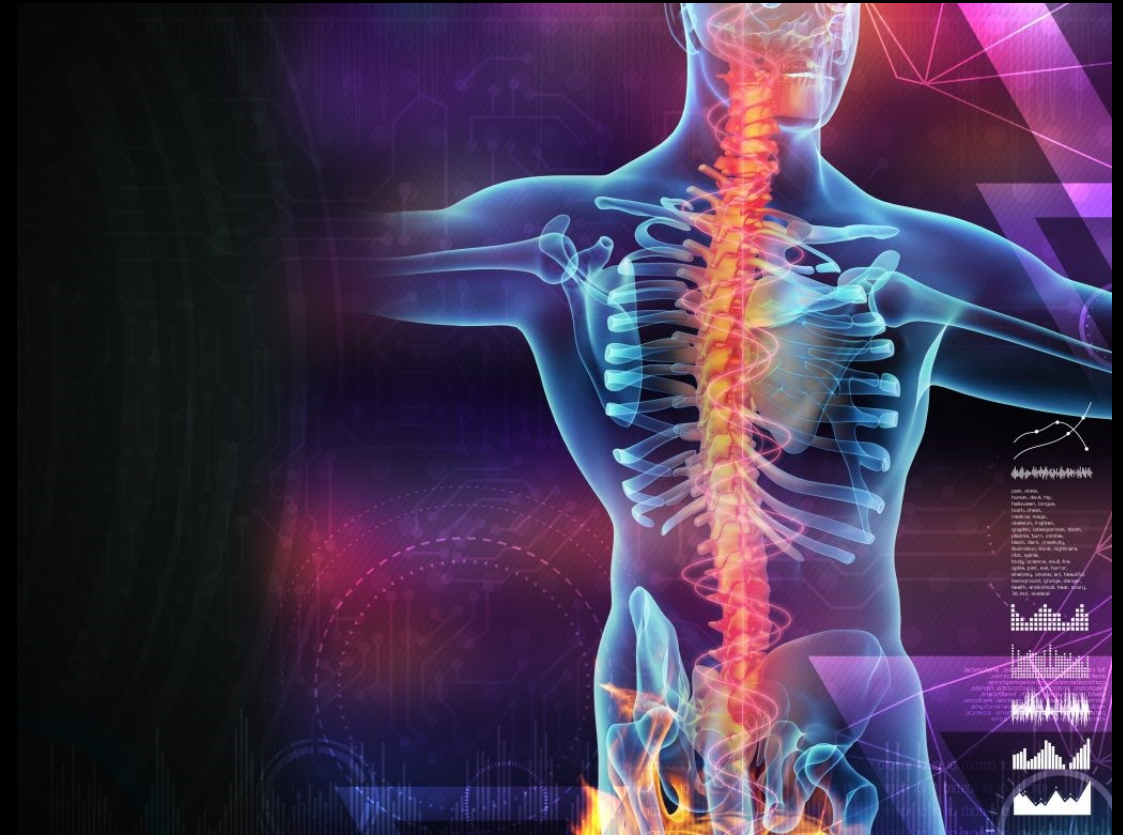

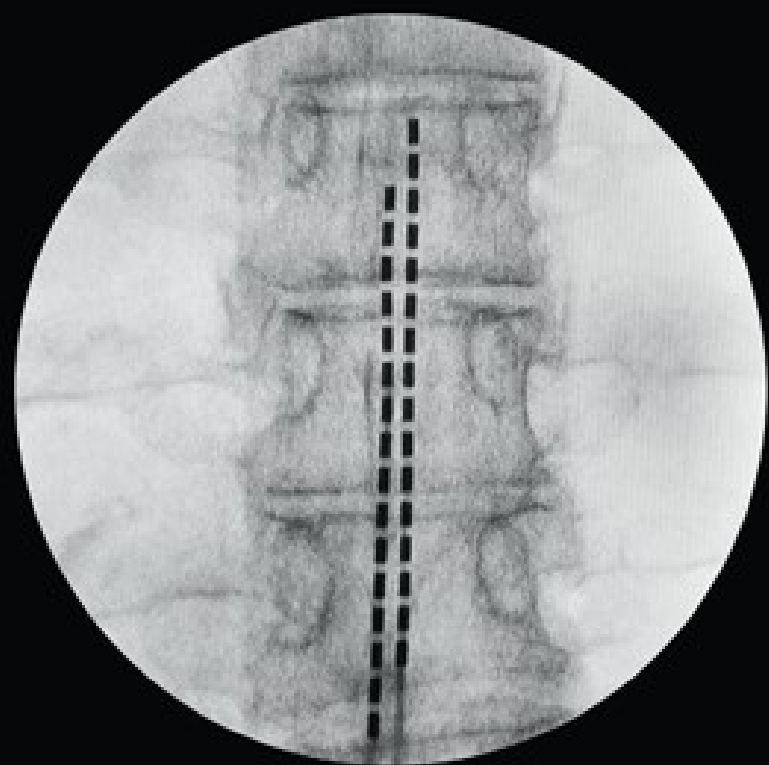
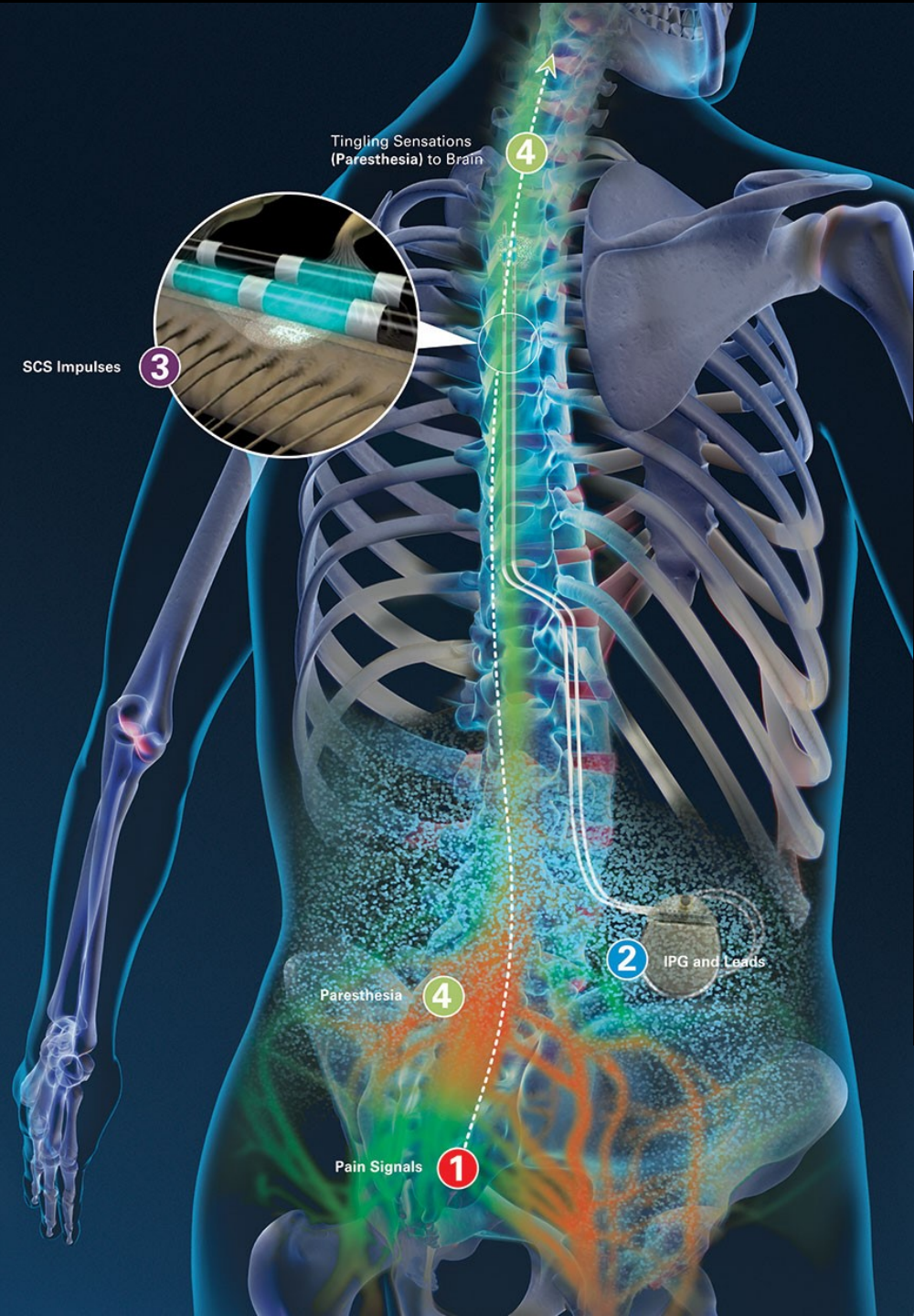
Foraminal neuroplasty





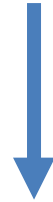The Advancing Role of Neuromodulation for the Management of Chronic Pain





SCS Common Neuropathic Indications

Failed back surgery syndrome
Complex regional pain syndrome (I and II)
Radicular and nerve root pain
Postherpetic neuralgia
Pain due to peripheral nerve injury
Intercostal neuralgia
Phantom pain



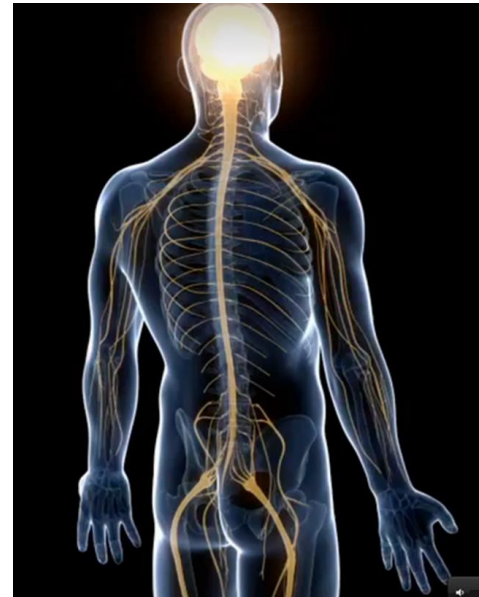
FBSS (Grade 1A)
CRPS type I (Grade A)
type II (Grade B)

SCS IMPLANT


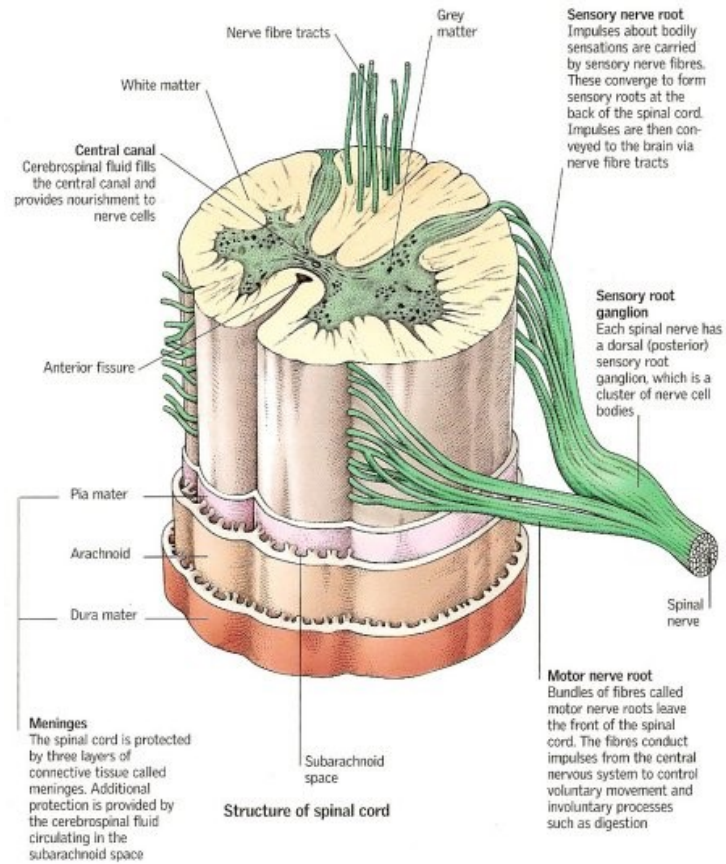
TWO PHASES

FIRST STEP:
Trial Implant

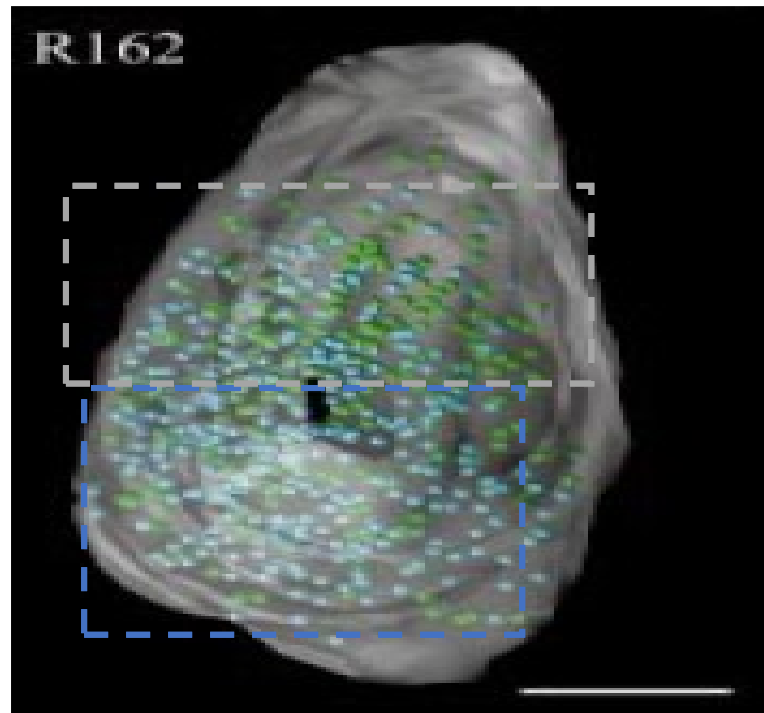
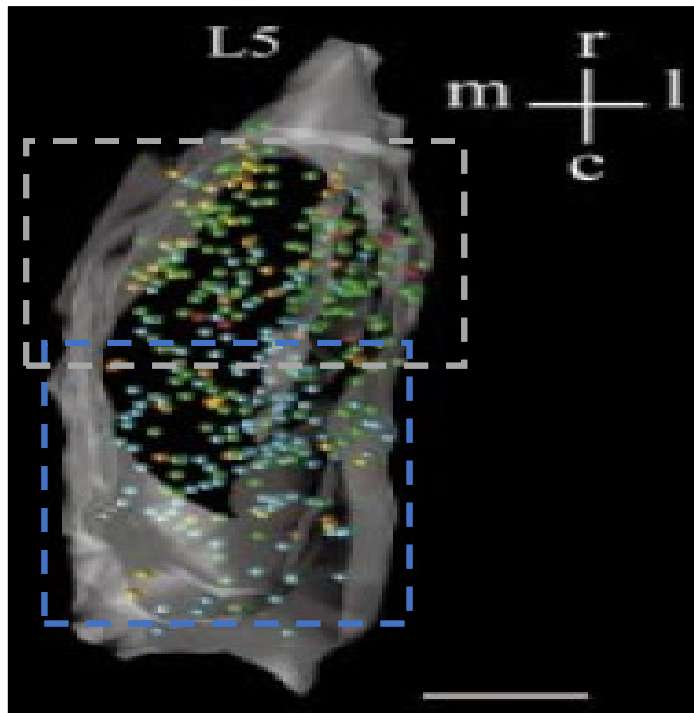
SECOND STEP:
DEFINITIVE Implant



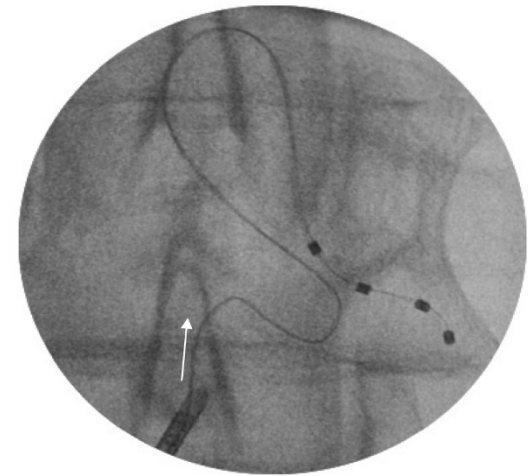
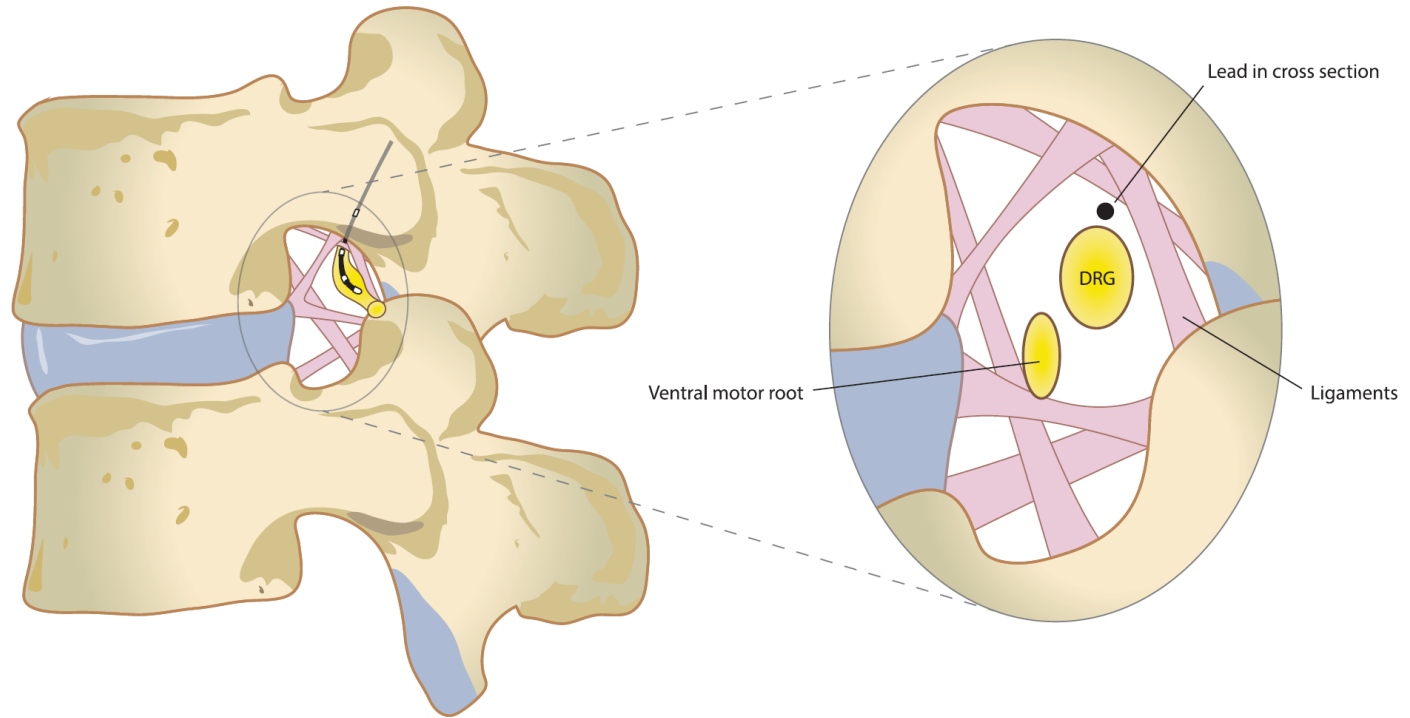
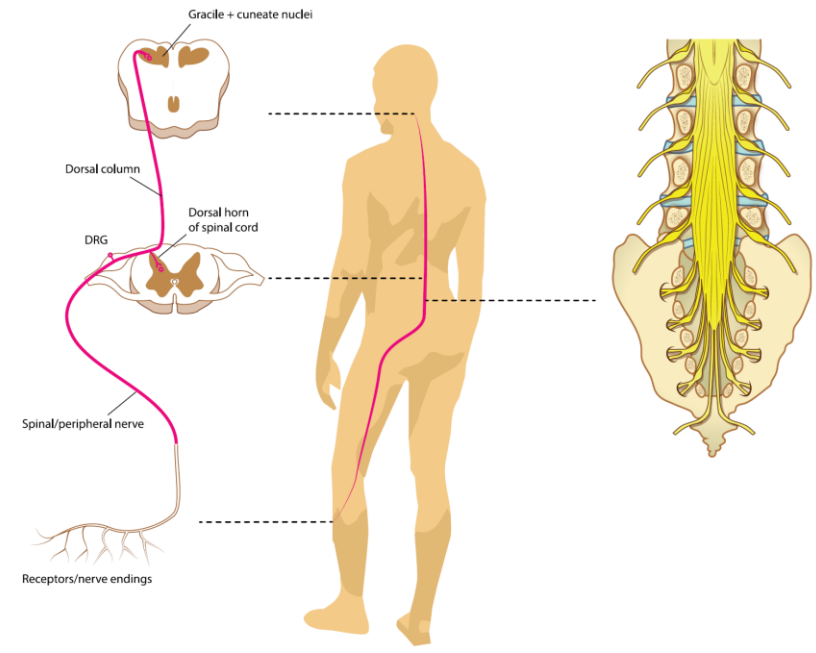
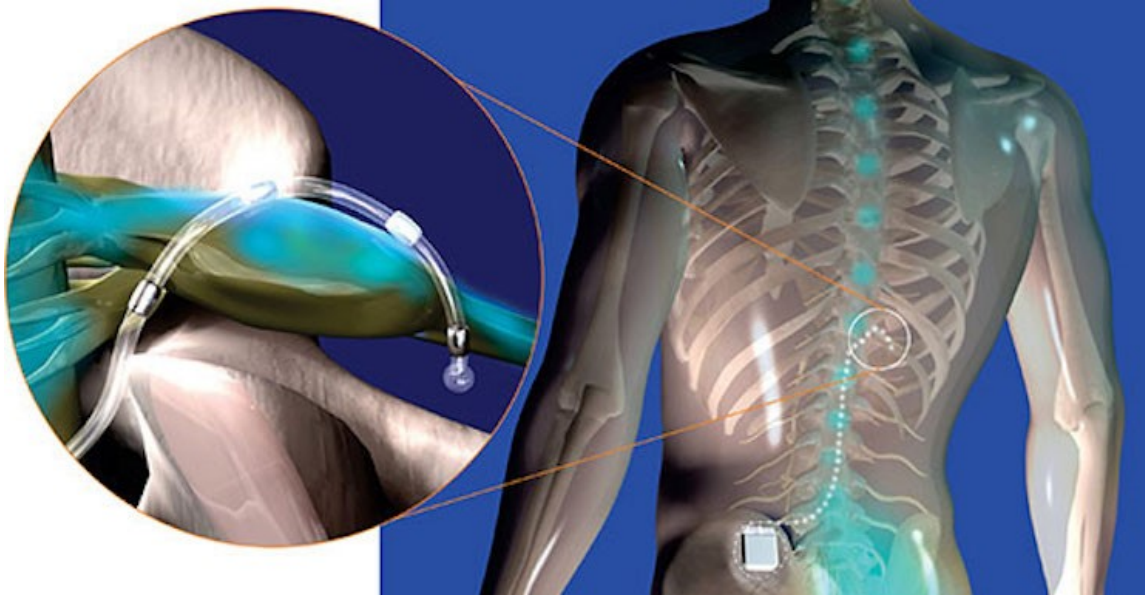
New Targets

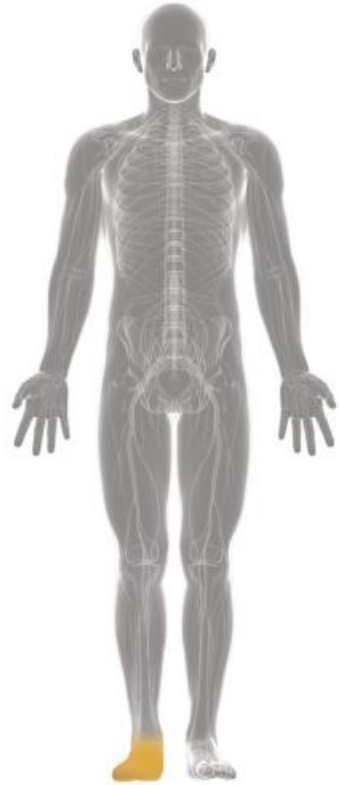

DRG Anatomy

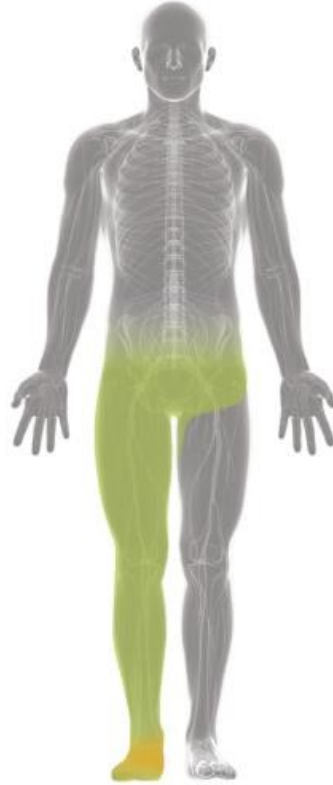

GREEN = IV finger
BLUE = V finger

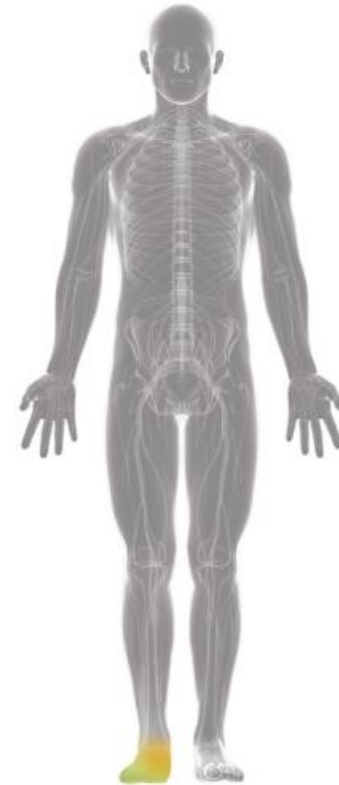



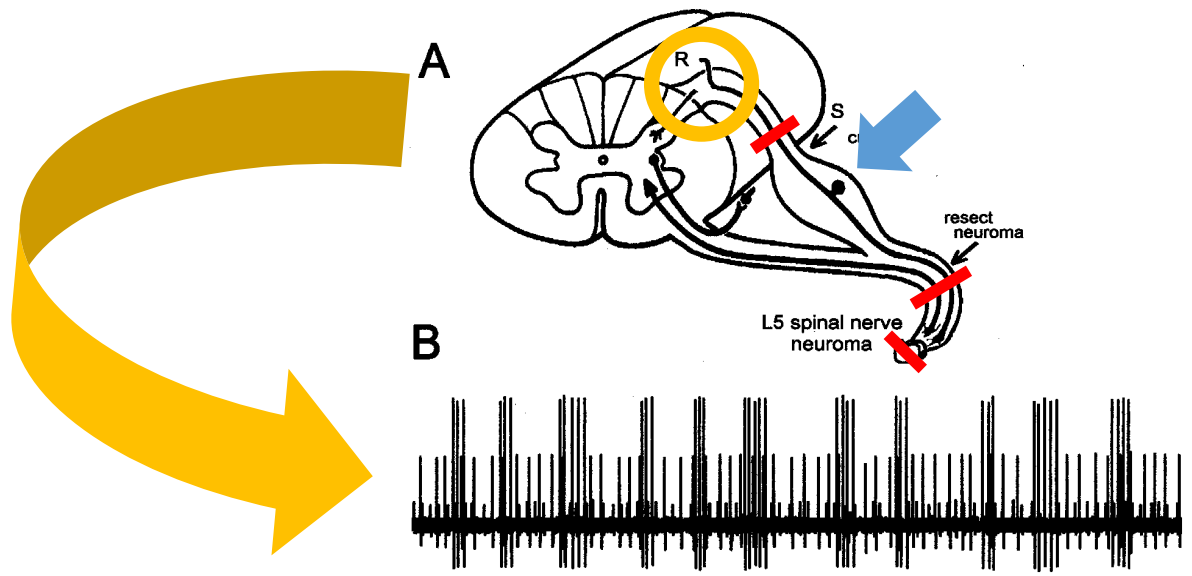
AREA OF PAIN

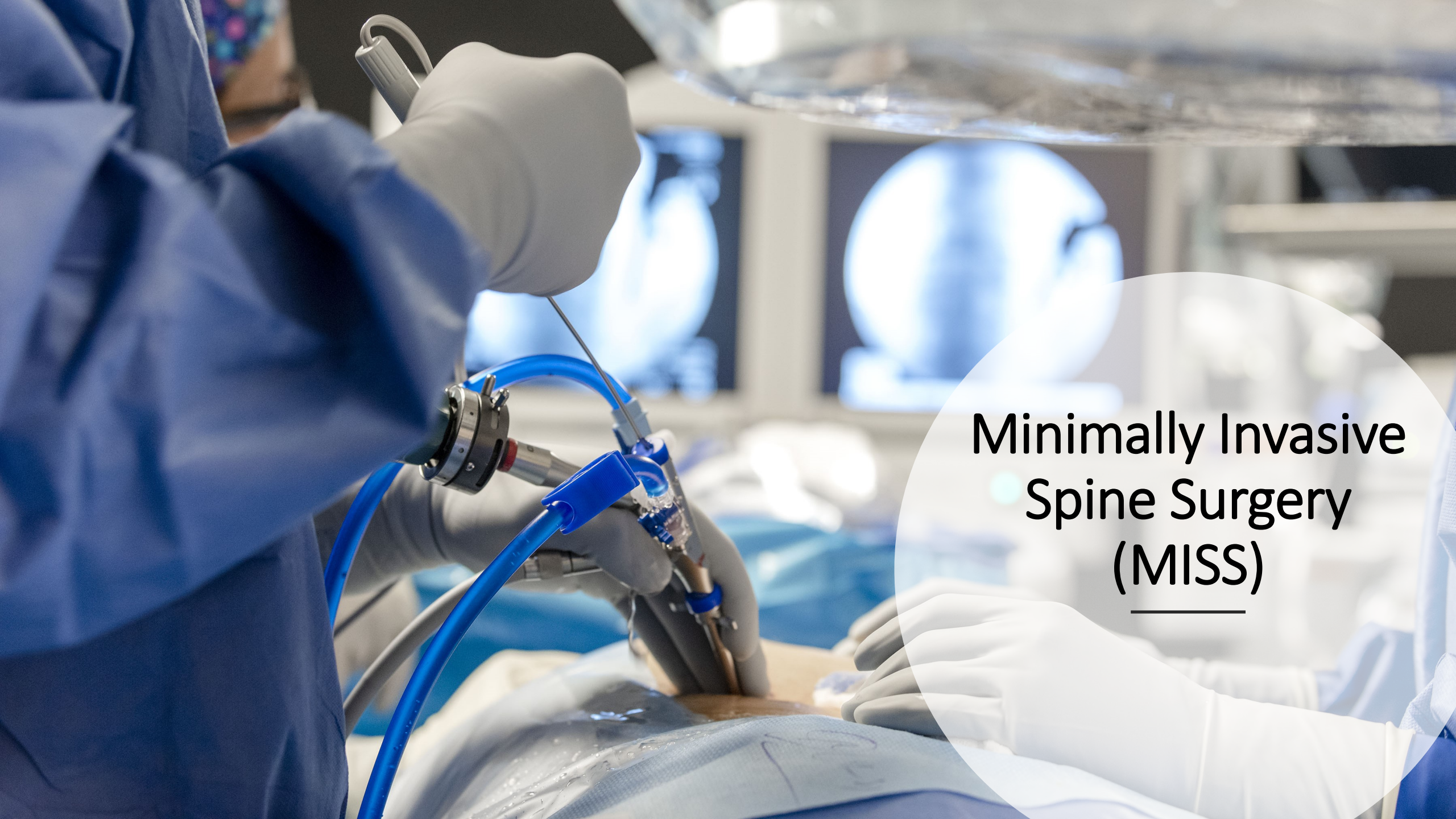

**TRADITIONAL
STIMULATION**

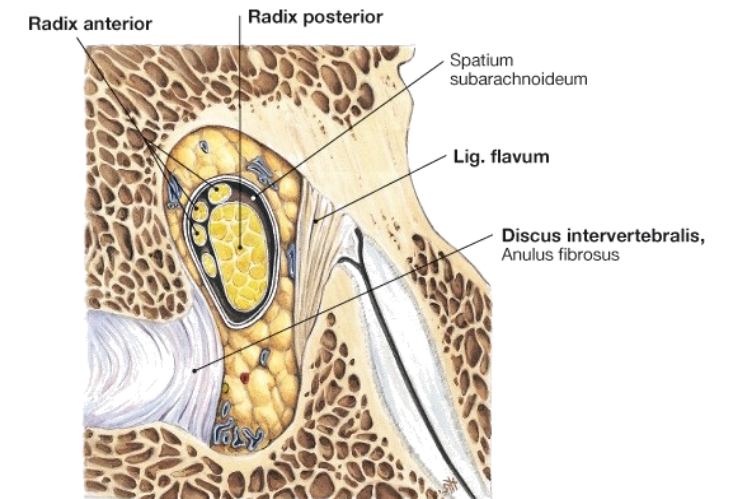
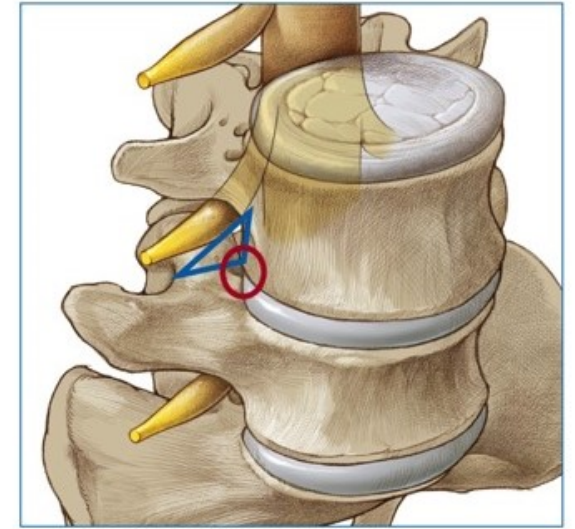
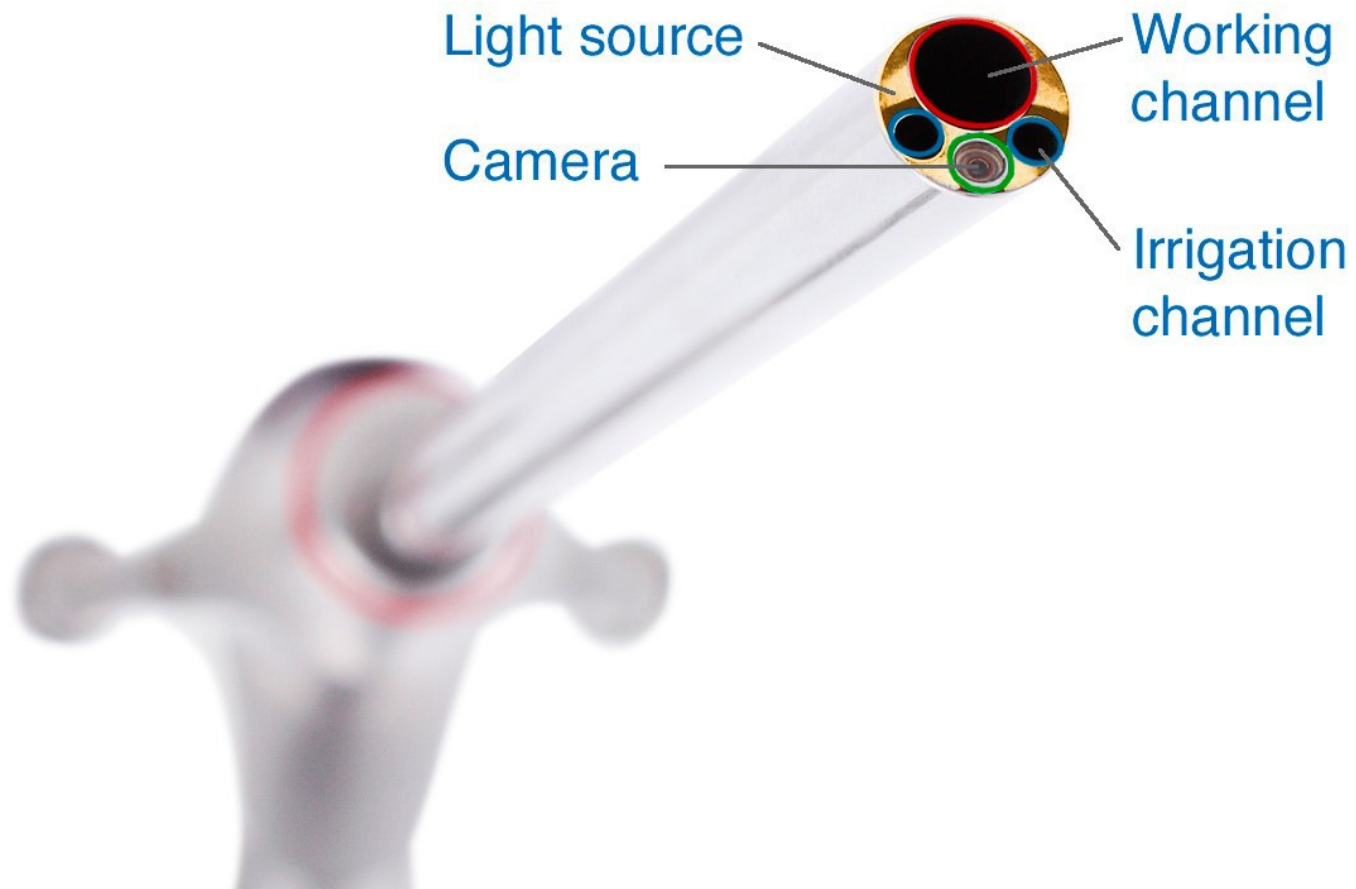


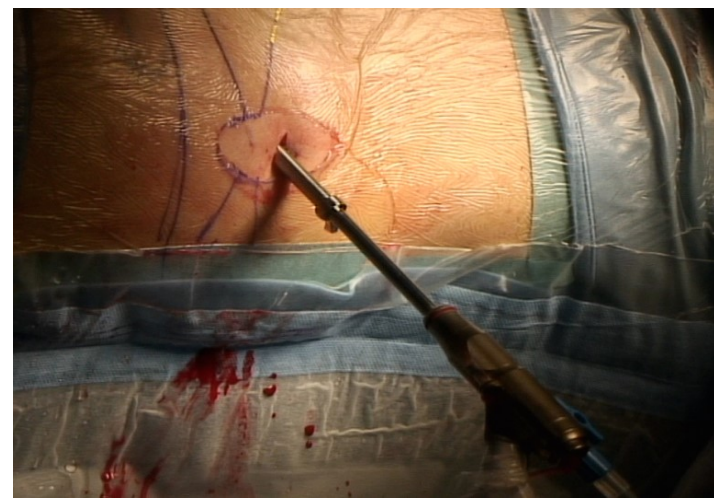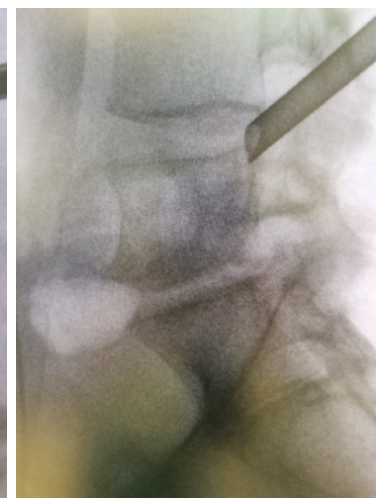
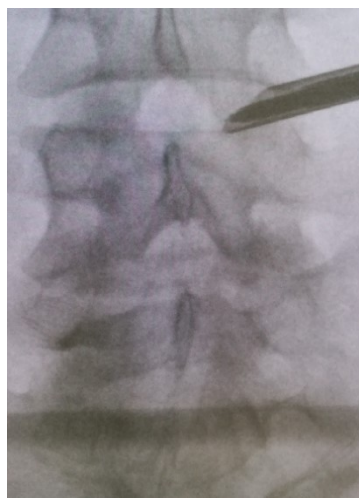
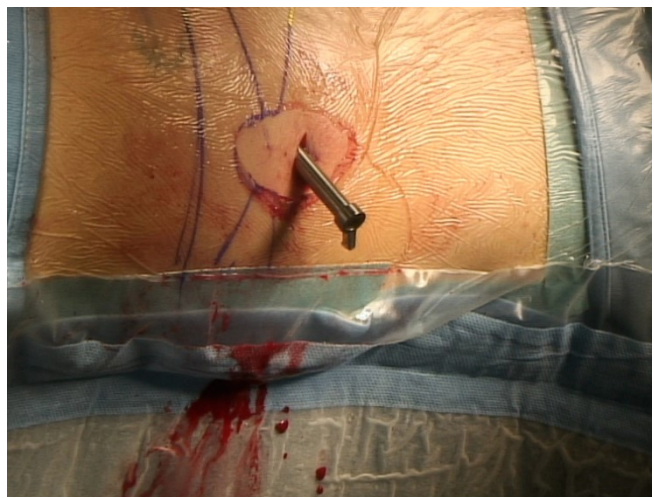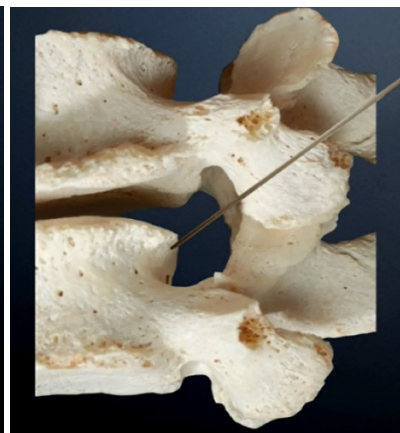
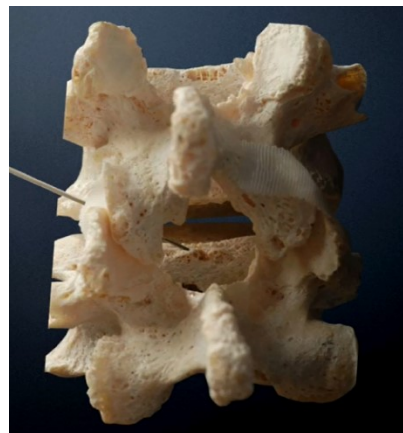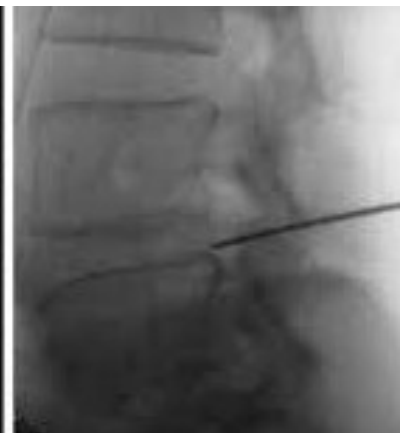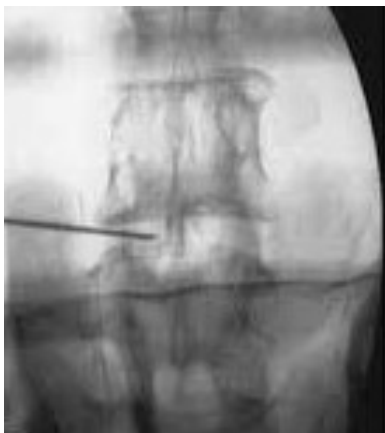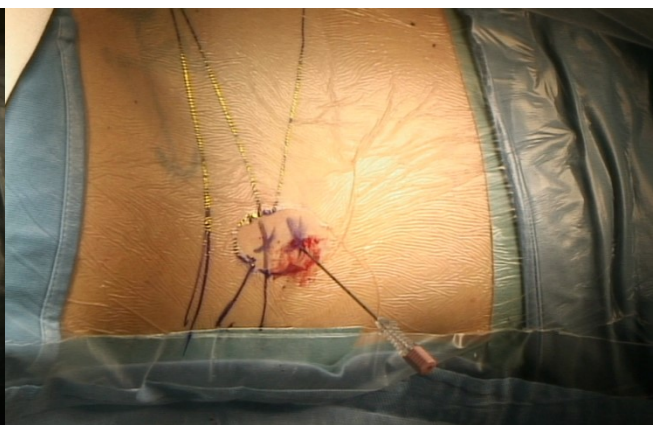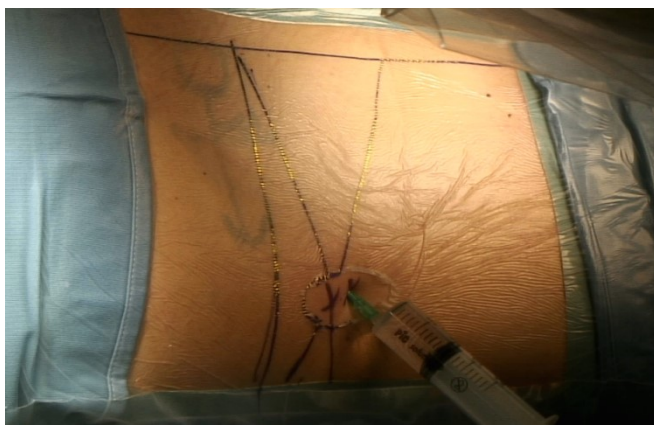**DRG
STIMULATION**

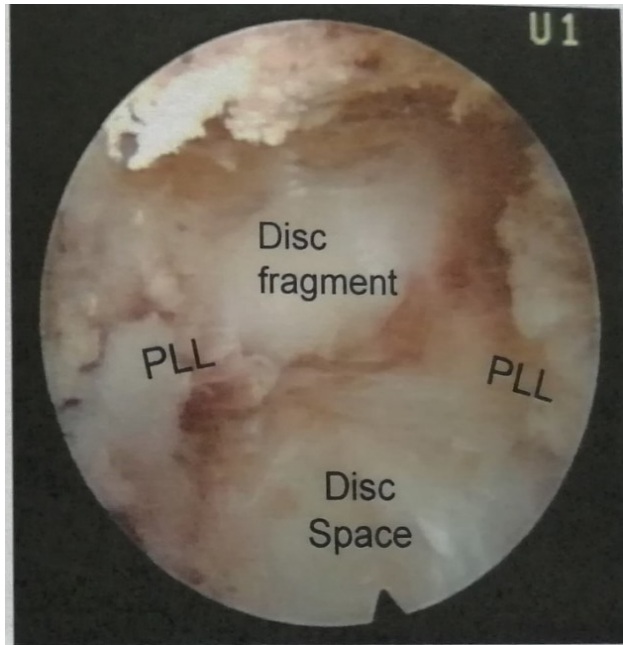
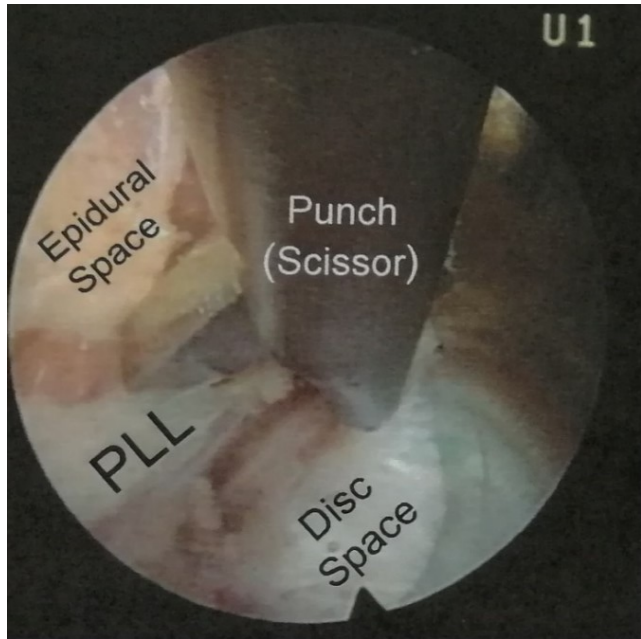
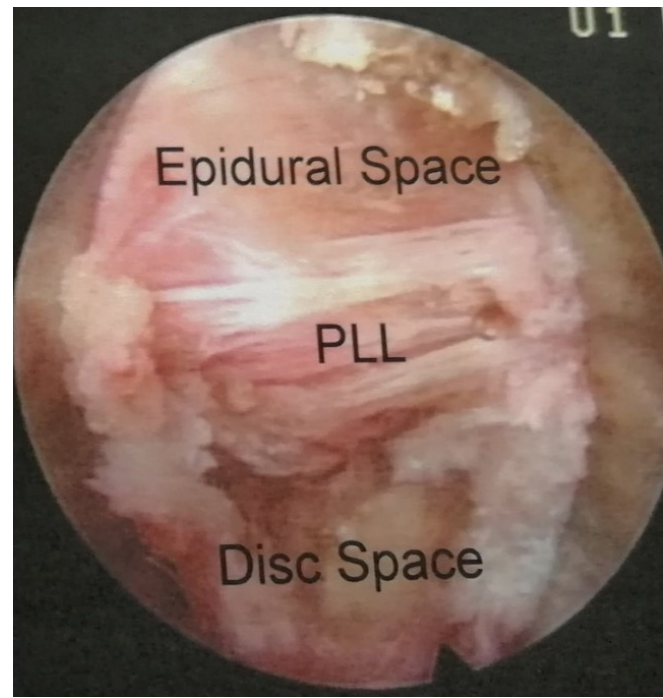
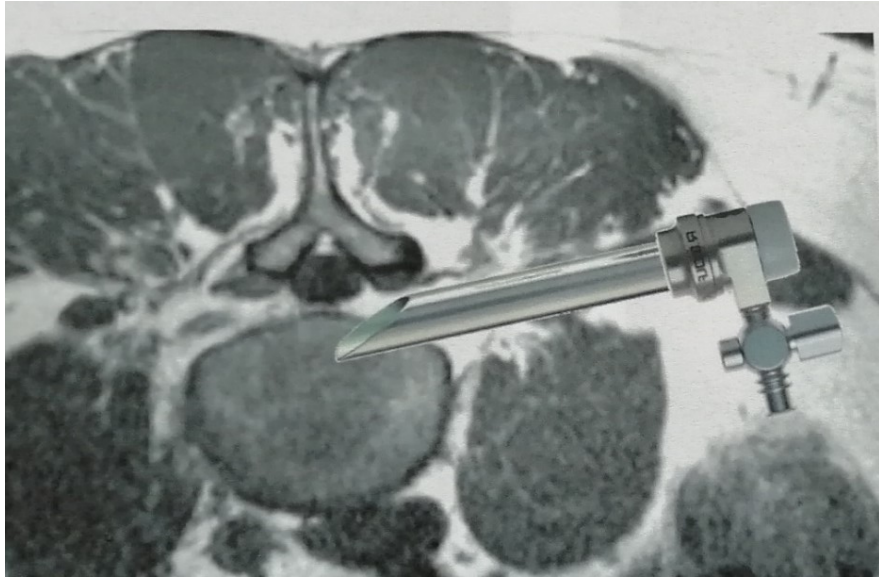




**Minimally Invasive
Spine Surgery
(MISS)**







Im: 13/23

Se: 2

S

2790003880

29/08/1965 M

Inacqua Coop Soc. A.R.L Onlus Rep. Rad. RM

1751

LOMBARE^GENERALE

t2_tse_sag_384

A

P

Im: 31/42

Se: 5

A

2790003880

29/08/1965

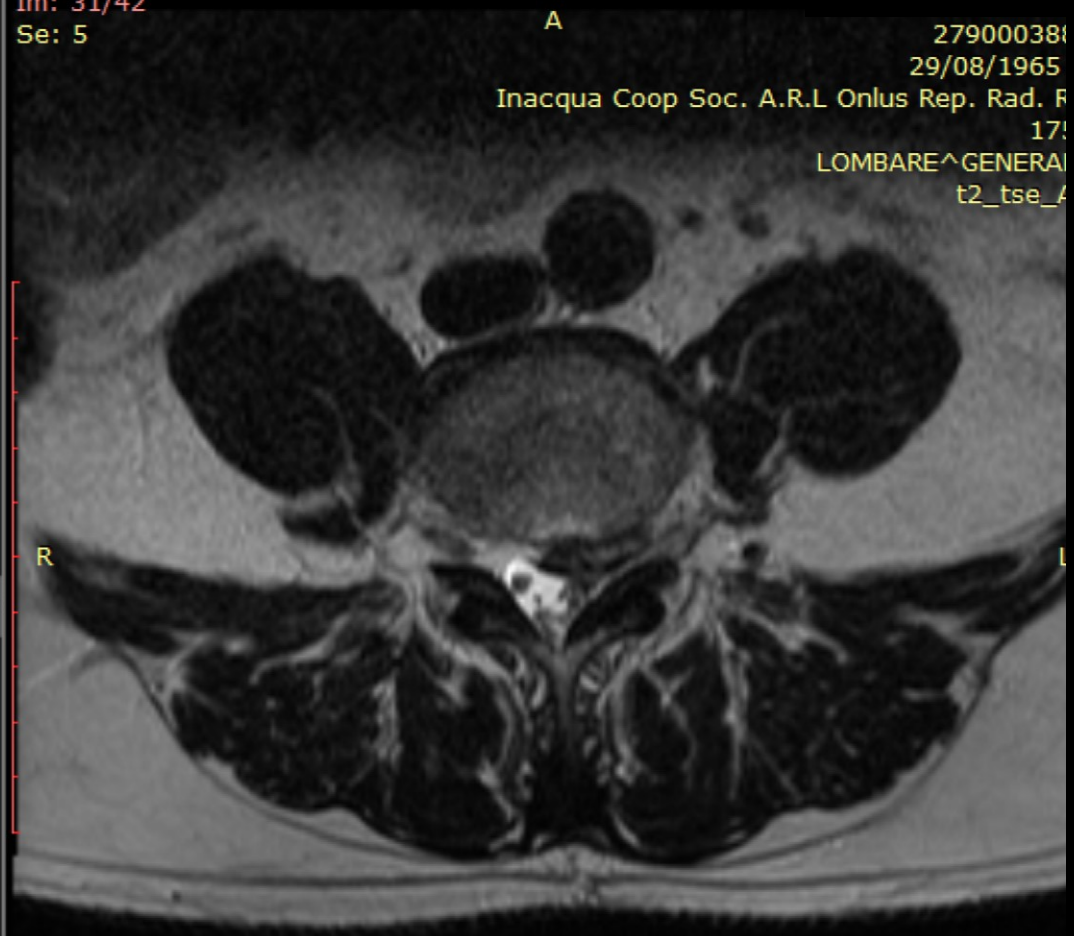
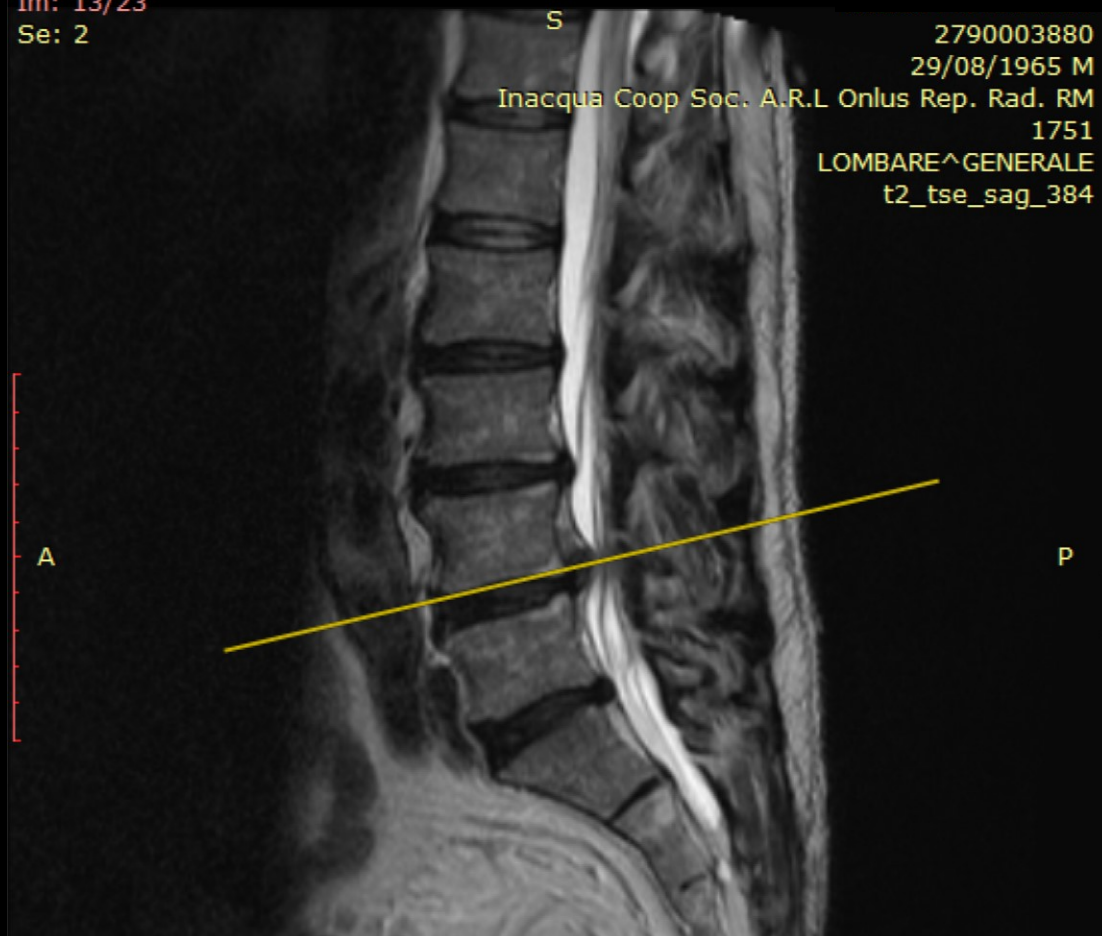
Inacqua Coop Soc. A.R.L Onlus Rep. Rad. F

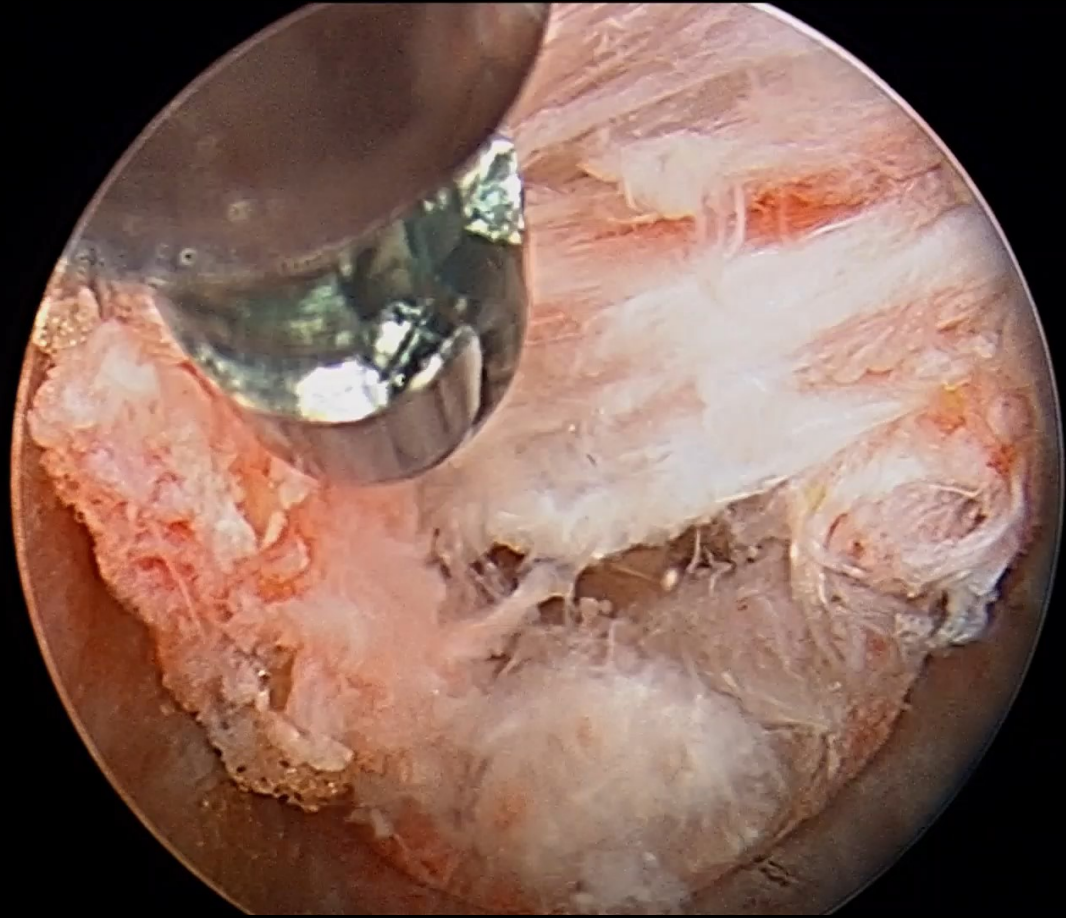
1751

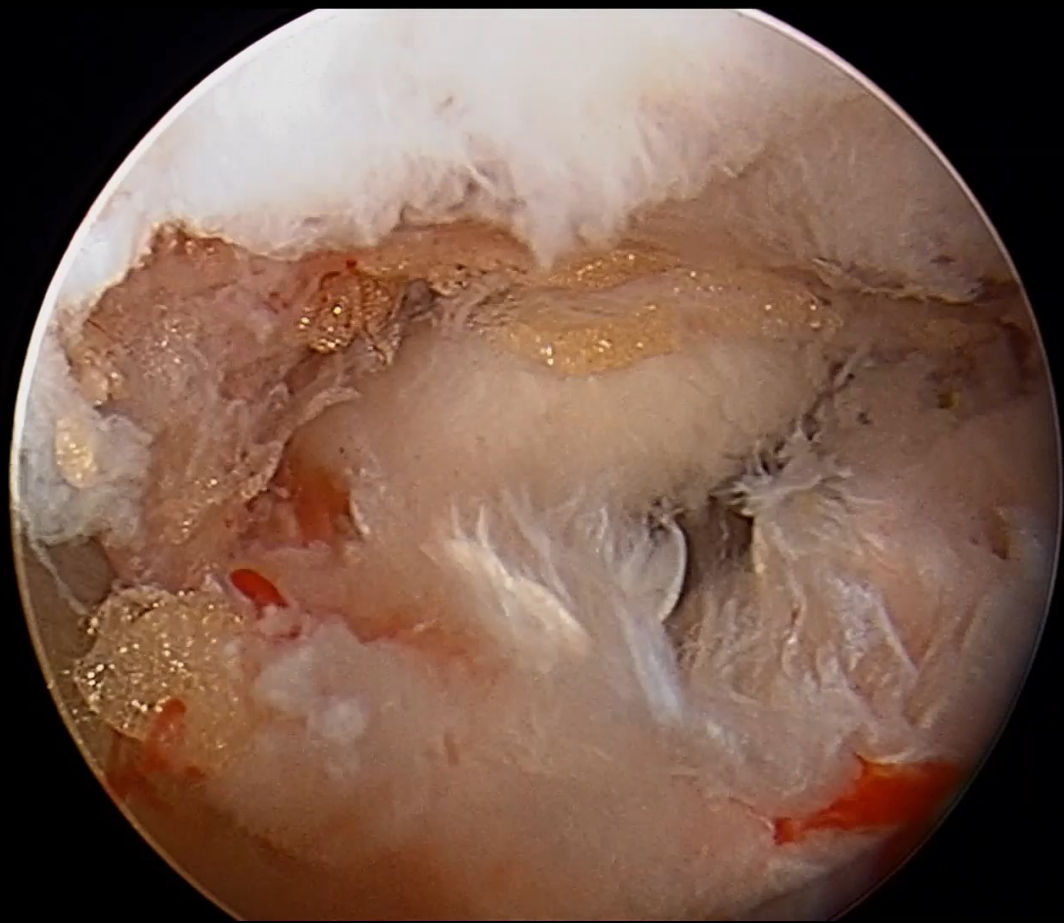
LOMBARE^GENERALE

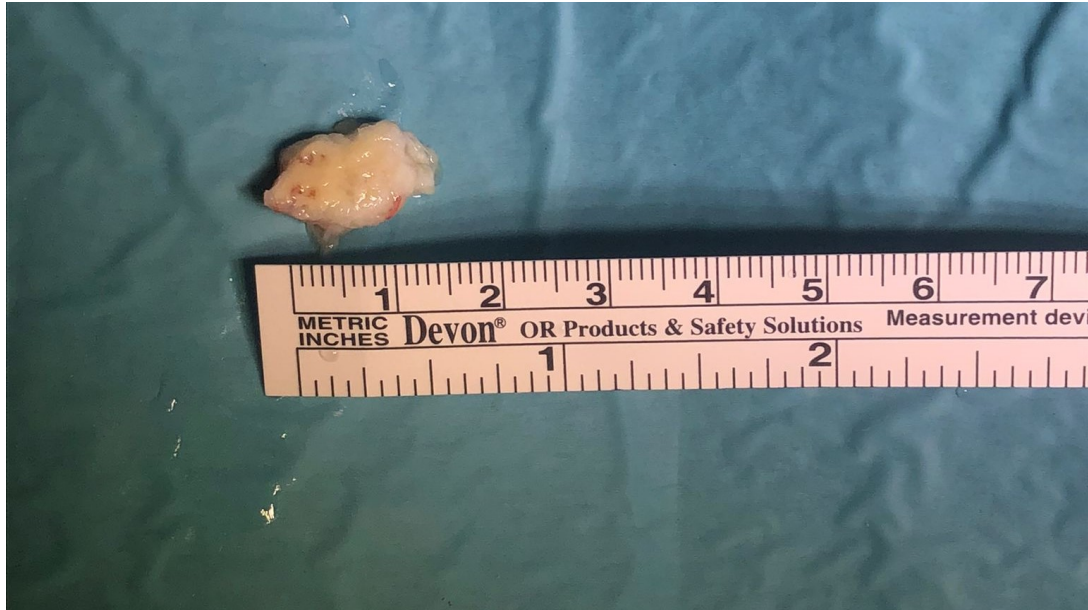
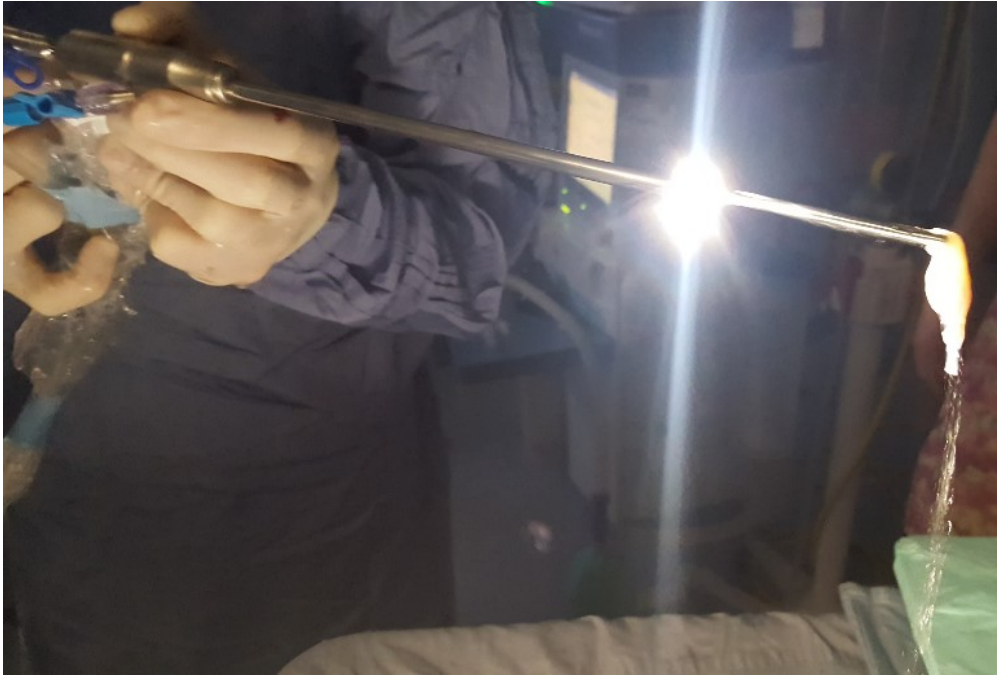t2_tse_4

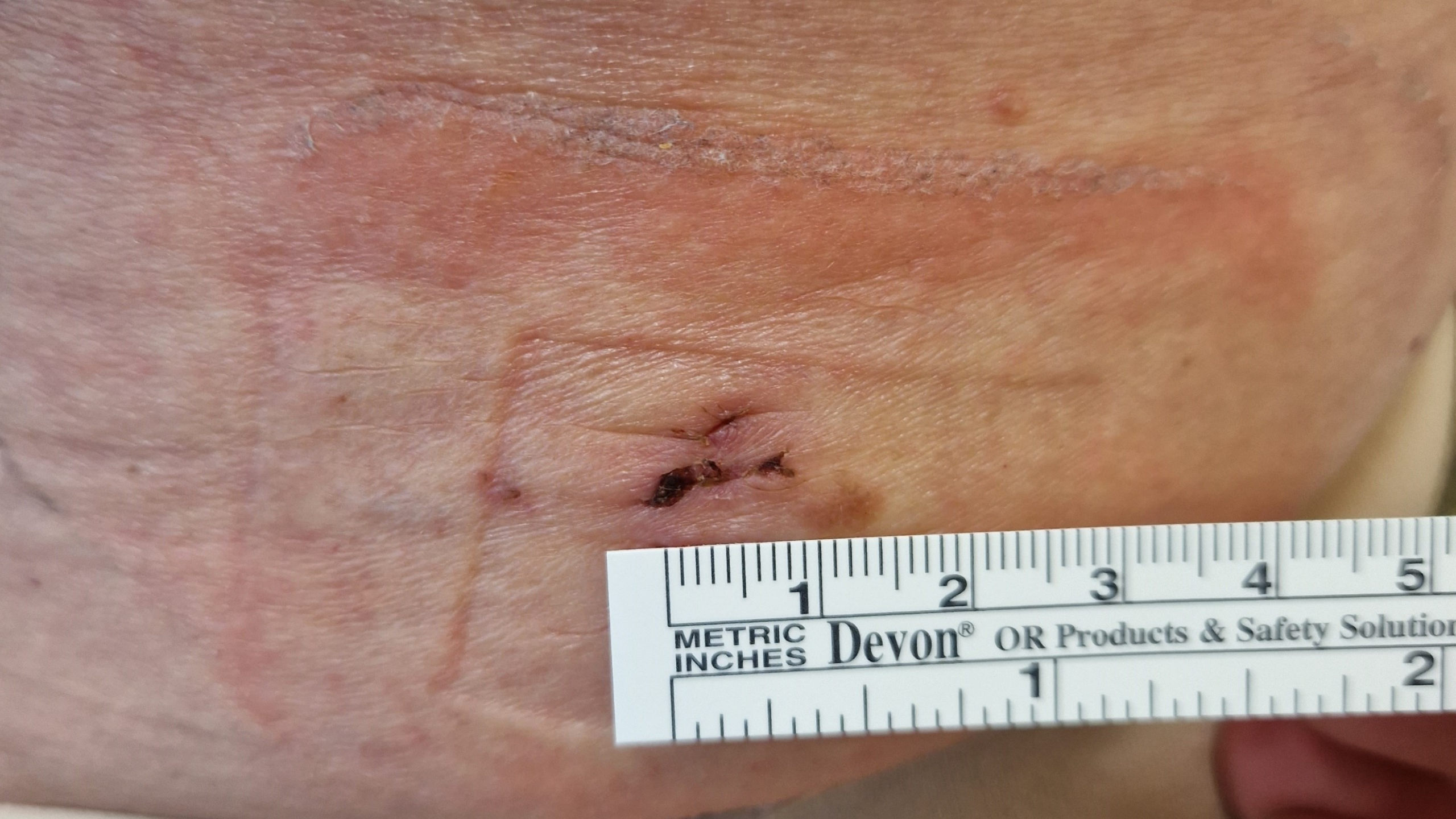R



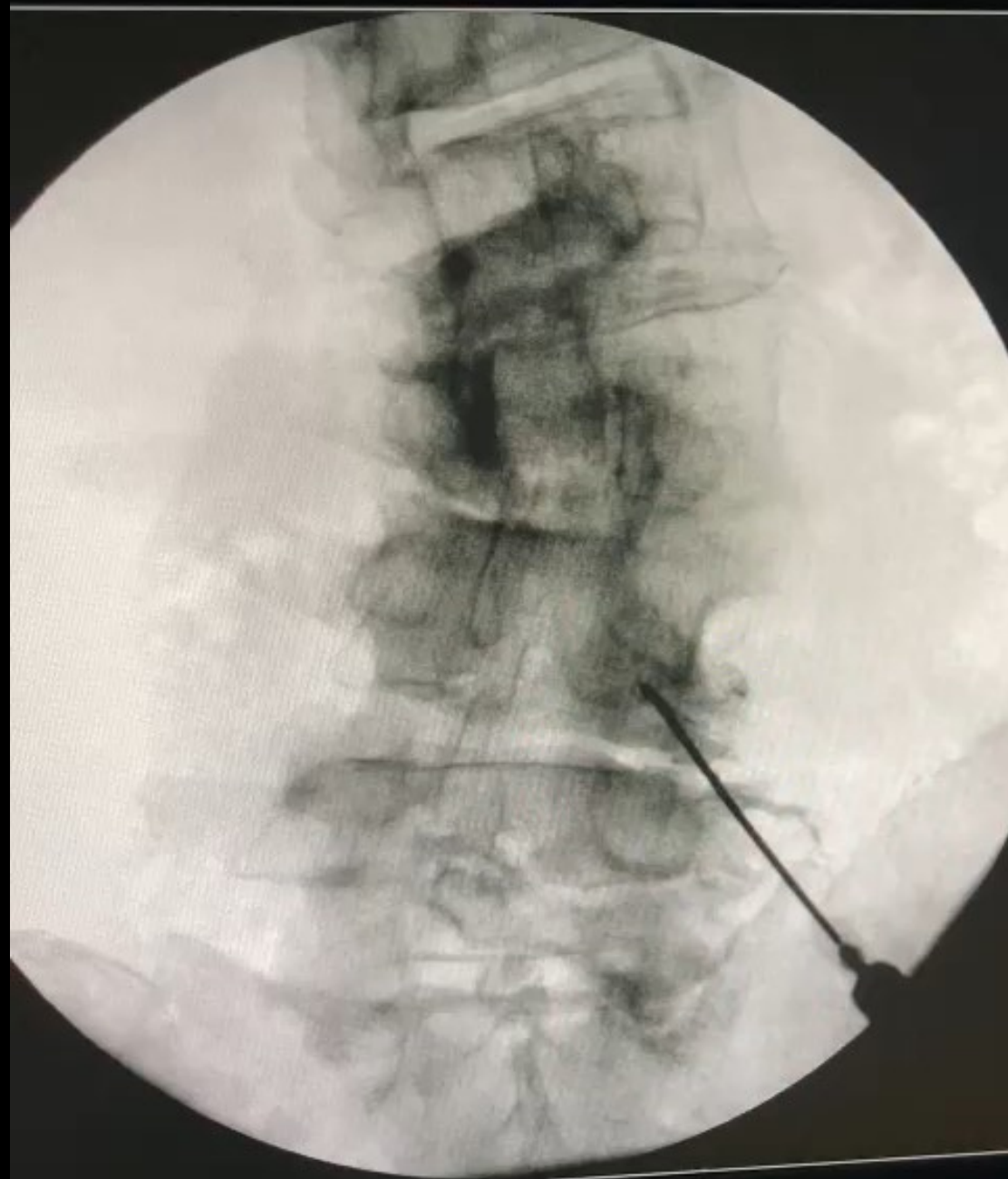







1 2 3 4 5
METRIC INCHES Devon® OR Products & Safety Solutions
1 2



Take home messages



- Interventional and surgical pain management should be used when **non-invasive modalities** have **failed**
- A feasible alternative/**add-on therapy** to pharmacological treatment
- Technology is expanding

**Me...
after my
spine
gets
adjusted.**



Thank you for the
attention

matteolg.leoni@gmail.com
matteoluigigiuseppe.leoni@uniroma1.it