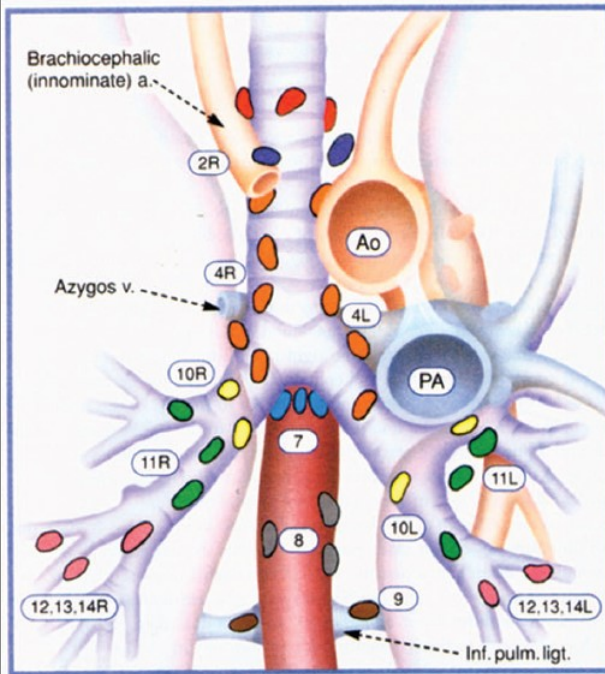




Trattamento Multidisciplinare delle
Neoplasie Polmonari
ORDINE DEI MEDICI BERGAMO

A.LUCIANETTI
UOC Chirurgia 1 e Toracica
Azienda Ospedaliera Papa Giovanni XXIII





Superior Mediastinal Nodes

- 1 Highest Mediastinal
- 2 Upper Paratracheal
- 3 Pre-vascular and Retrotracheal
- 4 Lower Paratracheal (including Azygos Nodes)

N₂ = single digit, ipsilateral

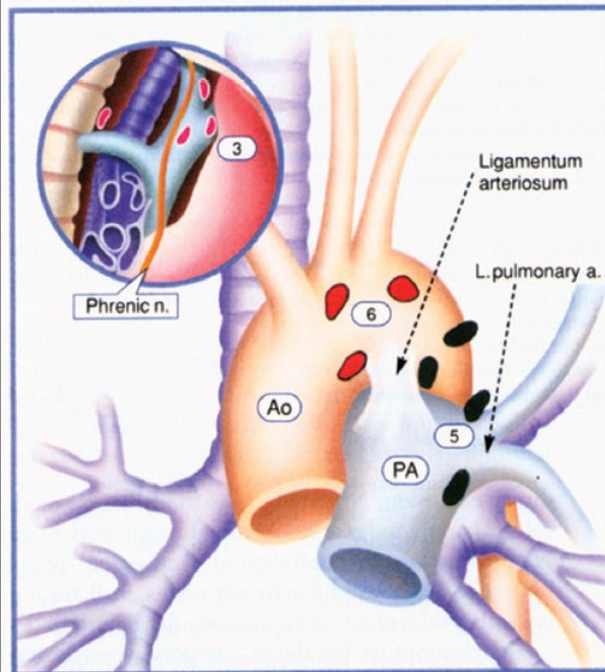
N₃ = single digit, contralateral or supraclavicular

Aortic Nodes

- 5 Subaortic (A-P window)
- 6 Para-aortic (ascending aorta or phrenic)

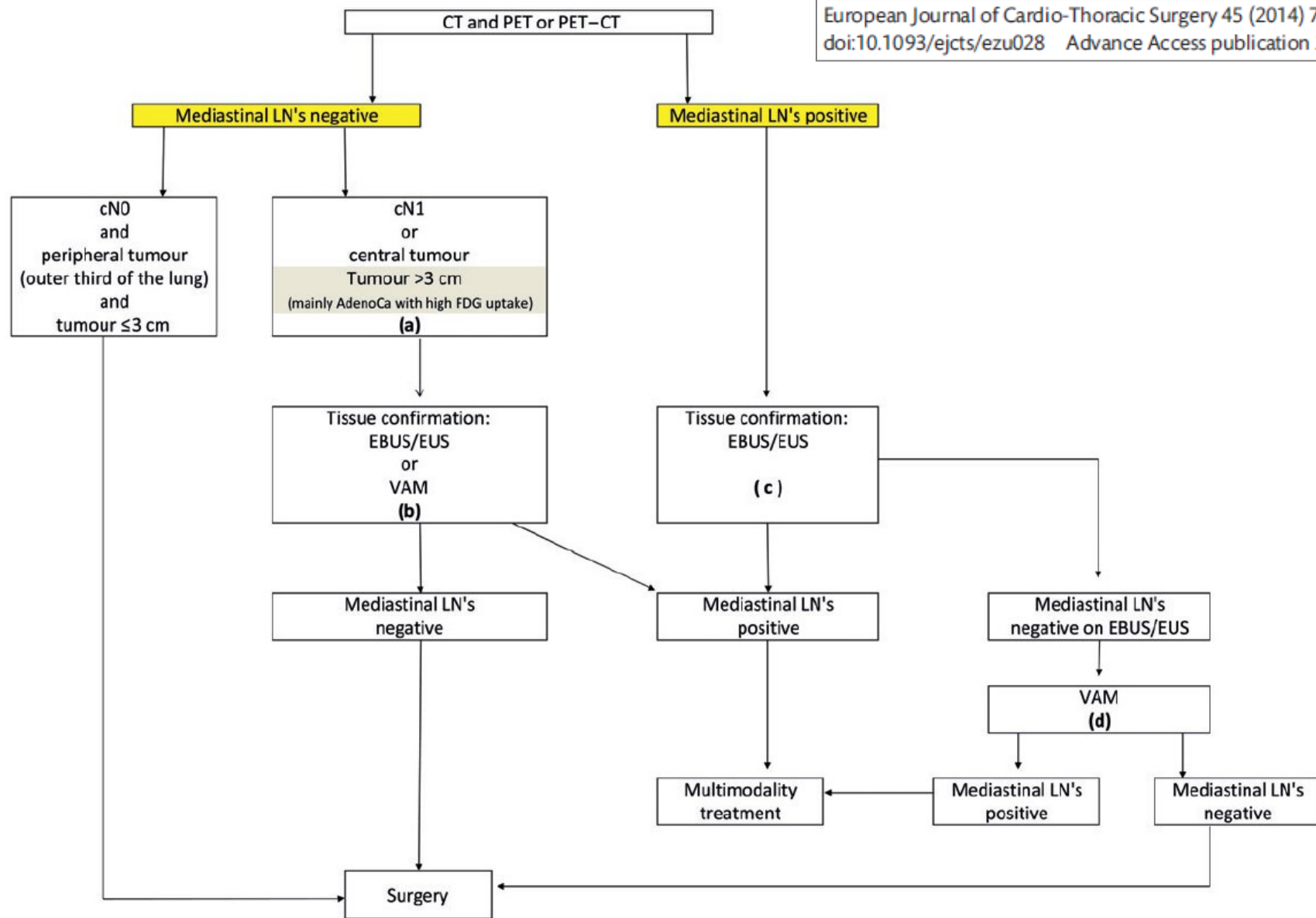
Inferior Mediastinal Nodes

- 7 Subcarinal
- 8 Paraesophageal (below carina)
- 9 Pulmonary Ligament



N₁ Nodes

- 10 Hilar
- 11 Interlobar
- 12 Lobar
- 13 Segmental
- 14 Subsegmental



(a) : In tumours > 3 cm (mainly in adenocarcinoma with high FDG uptake) invasive staging should be considered

(b) : Depending on local expertise to adhere to minimal requirements for staging

(c) : Endoscopic techniques are minimally invasive and are the first choice if local expertise with EBUS/EUS needle aspiration is available

(d) : Due to its higher NPV, in case of PET positive or CT enlarged mediastinal LN's, videoassisted mediastinoscopy (VAM) with nodal dissection or biopsy remain indicated when endoscopic staging is negative. Nodal dissection has an increased accuracy over biopsy

Figure 2: Revised ESTS guidelines for primary mediastinal staging.

Staging and stage Group (TNM)S

	N0	N1	N2	N3
T1a	IA1	IIB	IIIA	IIIB
T1b	IA2	IIB	IIIA	IIIB
T1c	IA3	IIB	IIIA	IIIB
T2a	IB	IIB	IIIA	IIIB
T2b	IIA	IIB	IIIA	IIIB
T3	IIB	IIIA	IIIB	IIIC
T4	IIIA	IIIA	IIIB	IIIC
M1a	IVA	IVA	IVA	IVA
M1b	IVA	IVA	IVA	IVA
M1c	IVB	IVB	IVB	IVB

743 x 353

180822

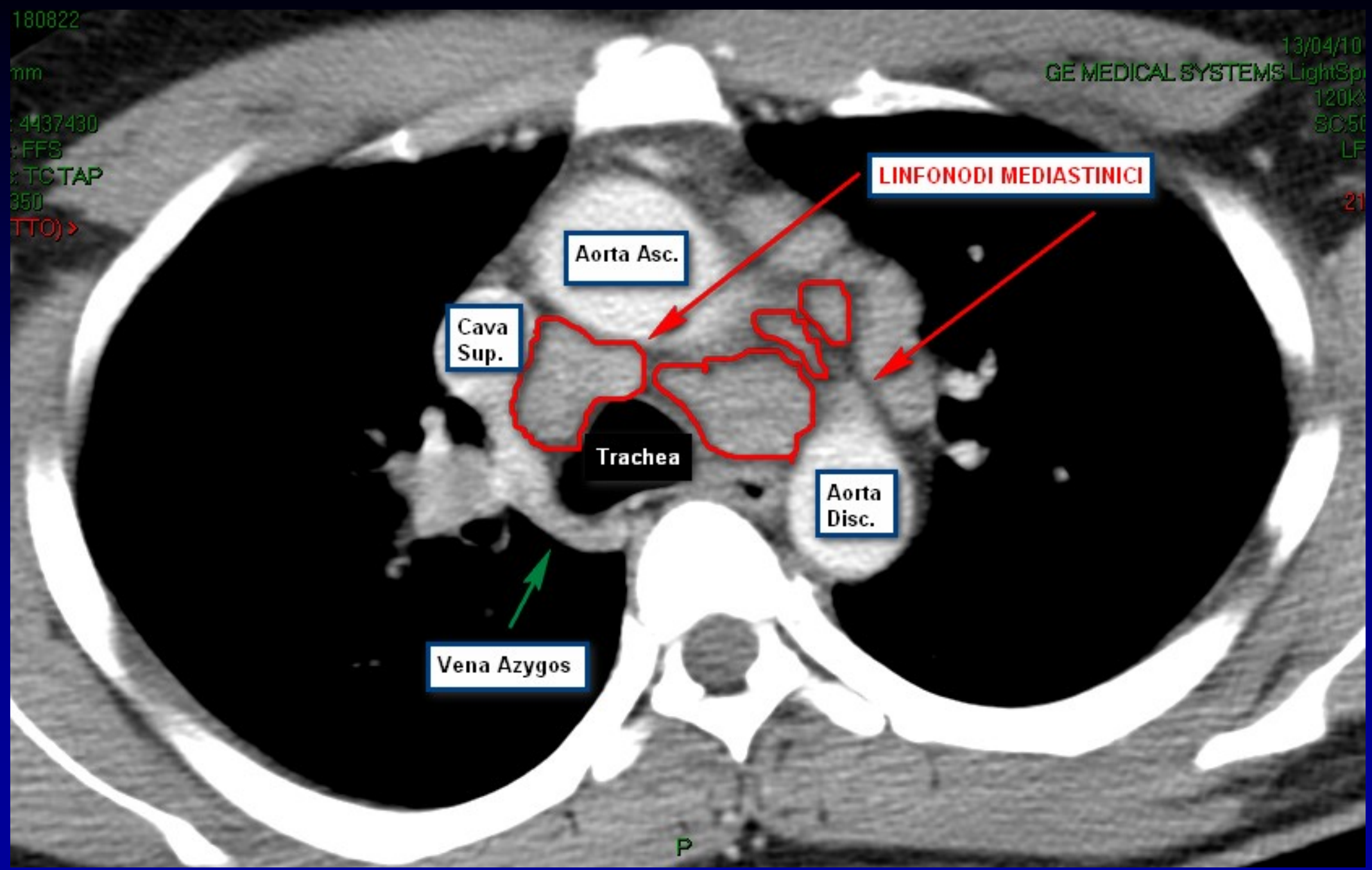
mm

: 4437430
: FFS
: TCTAP
350
TTO) >

13/04/10

GE MEDICAL SYSTEMS LightSp
120K
5050
LF

21



Cava
Sup.

Aorta Asc.

Trachea

Aorta
Disc.

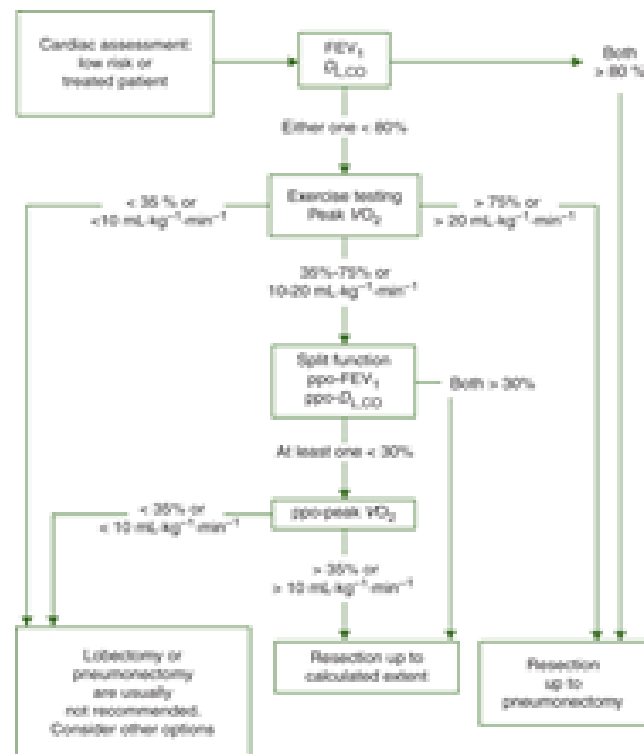
Vena Azygos

LINFONODI MEDIASTINICI

P

Preoperative respiratory and cardiac evaluation

Figure 3. Preoperative respiratory evaluation. DLCO, diffusing capacity of the lungs for carbon monoxide; FEV₁, forced ...



- Surgery should be offered to all patients with stage I and II NSCLC as the preferred treatment to all who are willing to accept procedure-related risks [III, A].
- For patients with a non-centrally located resectable tumour and absence of nodal metastasis on both CT and PET images, surgical resection is recommended [I, A].

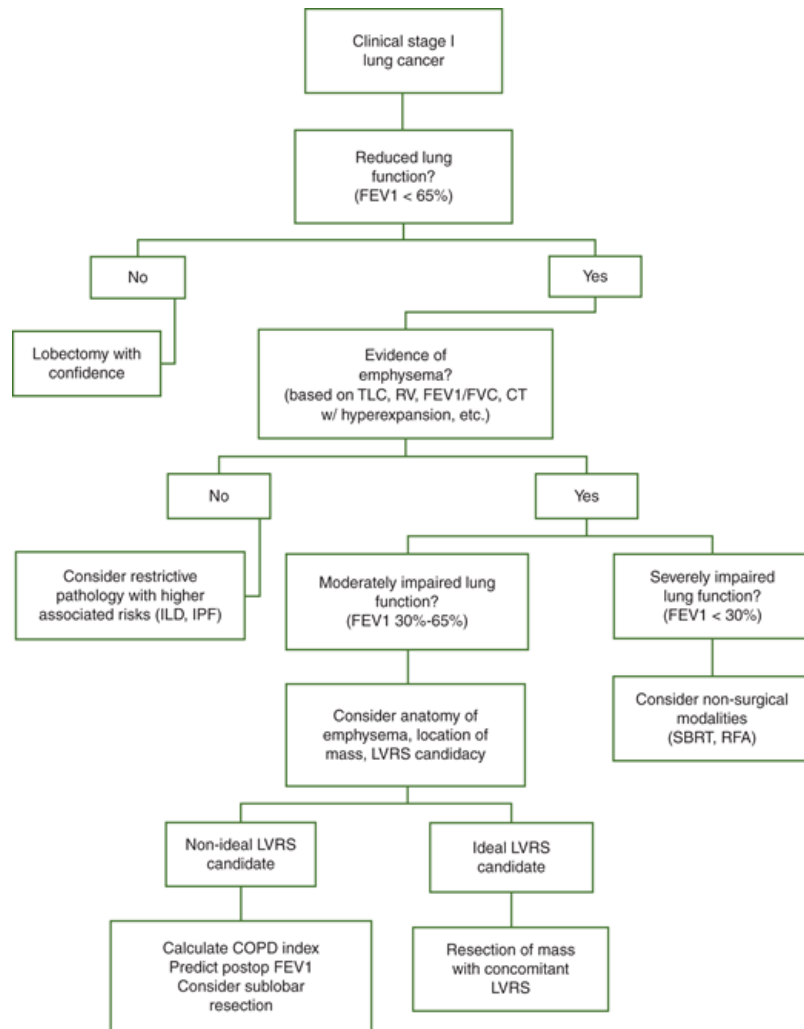
Anatomical resection is preferred over wedge resection [I, A].

Anatomical segmentectomy is generally considered acceptable for pure GGO lesions or adenocarcinomas in situ or with minimal invasion [III, B].

Lobectomy is still considered the standard surgical treatment of tumours ≥ 2 cm in size that have a solid appearance on CT [II, B].

- Lymph node dissection should conform to IASLC specifications for staging [III, A].
- Either open thoracotomy or VATS access can be carried out as appropriate to the expertise of the surgeon [III, A].
- VATS should be the approach of choice in stage I tumours [V, C].

Stage I treatment



Algorithm for patients with clinical stage I lung cancer and limited pulmonary function due to emphysema. CT, computed tomography; COPD, chronic obstructive pulmonary disease; FEV1, forced expiratory volume 1; FVC, forced vital capacity; ILD, interstitial lung disease; IPF, idiopathic pulmonary fibrosis; LVRS, lung volume reduction surgery; RFA, radiofrequency ablation; RV, reserve volume; SBRT, stereotactic body radiotherapy; TLC, total lung capacity. Reprinted from [45], with permission from Elsevier.

- For patients with multifocal lung cancer, complete resection is recommended whenever possible. All patients with multifocal lung cancer should be discussed in a multidisciplinary tumour board [III, B]

TERAPIA CHIRURGIA DEL NSCLC: LINEE GUIDA ROL 2017

Stadio	T	N	M	Terapia standard	Terapia personalizzata
IA	T1a-b	N0	M0	Lobectomia vs Resezione più ampia + LA radicale	<ul style="list-style-type: none"> •Terapia standard in VATS •Resezione sublobare •Sleeve lobectomy •Lobectomia vs Resezione più ampia + Sampling dei linfonodi mediastinici
IB	T2a	N0	M0		
IIA	T2b	N0	M0	Lobectomia vs Resezione più ampia + LA radicale	<ul style="list-style-type: none"> •Sleeve lobectomy •Lobectomia vs Resezione più ampia + Sampling dei linfonodi mediastinici
	T1a-b	N1	M0	Lobectomia vs Resezione più ampia + LA radicale, CT adiuvante	
	T2a	N1	M0	Lobectomia vs Resezione più ampia + LA radicale, CT adiuvante	
IIB	T2b	N1	M0	Lobectomia vs Resezione più ampia + LA radicale, CT adiuvante	<ul style="list-style-type: none"> •Sleeve lobectomy •Lobectomia vs Resezione più ampia + Sampling dei linfonodi mediastinici
	T3	N0	M0	Lobectomia vs Resezione più ampia + LA radicale	

Stadio	T	N	M	Terapia standard	Terapia personalizzata
IIIA	T3	N1	M0	Lobectomia vs Resezione più ampia + LA radicale, CT adiuvante	Sleeve lobectomy
	T1-3	N2*	M0	Lobectomia vs Resezione più ampia + LA radicale, CT +/- RT adiuvante	
	T1-3	N2**	M0	<ul style="list-style-type: none"> •Lobectomia vs Resezione più ampia + LA radicale, CT +/- RT adiuvante •CT neoadiuvante, ev. Lobectomia vs Resezione più ampia + LA radicale, ev. RT adiuvante 	
	T1-3	N2***	M0		CT + RT neoadiuvante, ev. Lobectomia vs Resezione più ampia + LA radicale
	T4#	N0-1	M0	<ul style="list-style-type: none"> •<u>Se T4 per 2 noduli in lobi diversi dello stesso polmone:</u> chirurgia R0, CT adiuvante •<u>Se T4 per invasione di strutture vicine:</u> chirurgia, CT +/- RT adiuvante (se chirurgia R0) vs CT + RT adiuvante (se chirurgia R1-2) 	CT neoadiuvante, chirurgia, RT adiuvante
	T4##	N0-1	M0	CT neoadiuvante, ev. chirurgia, RT adiuvante	

* Reperto incidentale i.o.

*** Reperto clinico preoperatorio, bulky

** Reperto clinico preoperatorio, non bulky

Resecabile

Non resecabile

Stadio	N	M	Terapia standard	Terapia personalizzata
IV	N0-1	M1: metastasi solitaria cerebrale sincrona	Lobectomia vs Resezione più ampia + LA radicale, ev. RT panencefalica	
	N0-1	M1: metastasi surrenalica solitaria sincrona	Metastasectomia, Lobectomia vs Resezione più ampia + LA radicale, ev. CT adiuvante	
Tumore di Pancoast	N0-1	M0	CT + RT neoadiuvante, ev. chirurgia	
	N2	M0		CT + RT neoadiuvante, ev. chirurgia

VATS LOBECTOMY CONSENSUS RECOMMENDATIONS

INDICATIONS FOR VATS LOBECTOMY

≤7 cm (T1, T2a and T2b)	Recommended
-------------------------	-------------

N0 or N1 status	Recommended
-----------------	-------------

CONTRAINDICATIONS FOR VATS LOBECTOMY

Chest wall involvement including rib(s)	Recommended
---	-------------

Centrality of tumour if invading hilar structure(s)	Recommended
---	-------------

Previous thoracic surgery or pleurisy is not a contraindication	Highly Recommended
---	--------------------

FEV1 <30%	Recommended
-----------	-------------

DLCO <30%	Recommended
-----------	-------------

PREOPERATIVE INVESTIGATIONS

PET/CT and sampling of positive mediastinal lymph nodes	Highly Recommended
---	--------------------

Sampling of positive lymph nodes by EBUS/EUS	Recommended
--	-------------

VATS assessment at the time of surgery	Highly Recommended
--	--------------------

Total ipsilateral lymph node dissection in all patients	Recommended
---	-------------

Video-assisted thoracoscopic surgery lobectomy at 20 years: a consensus statement

Tristan D. Yan, Christopher Cao, Thomas A. D'Amico, Todd L. Demmy,
Jianxing He, Henrik Hansen, Scott J. Swanson and William S. Walker
on behalf of the International VATS Lobectomy Consensus Group

Eur J Cardiothorac Surg 2014 Apr;45(4):633-9

Definition of VATS lobectomy

Regarding the CALGB definition of VATS lobectomy as “no use of rib-spreading; a maximum length of 8 cm for the utility incision; individual dissection of pulmonary vessels and bronchus; standard node sampling or dissection”, an expert consensus was reached. Forty-one respondents (82%, “highly recommended”) completely agreed with the CALGB definition, while nine respondents (18%) stated that a small retractor should be acceptable in selected circumstances, such as conducting complex procedures (e.g. sleeve resection) or delivery of a large specimen.

Hybrid Surgical Approach of Video-Assisted Minithoracotomy for Lung Cancer*

Significance of Direct Visualization on Quality of Surgery

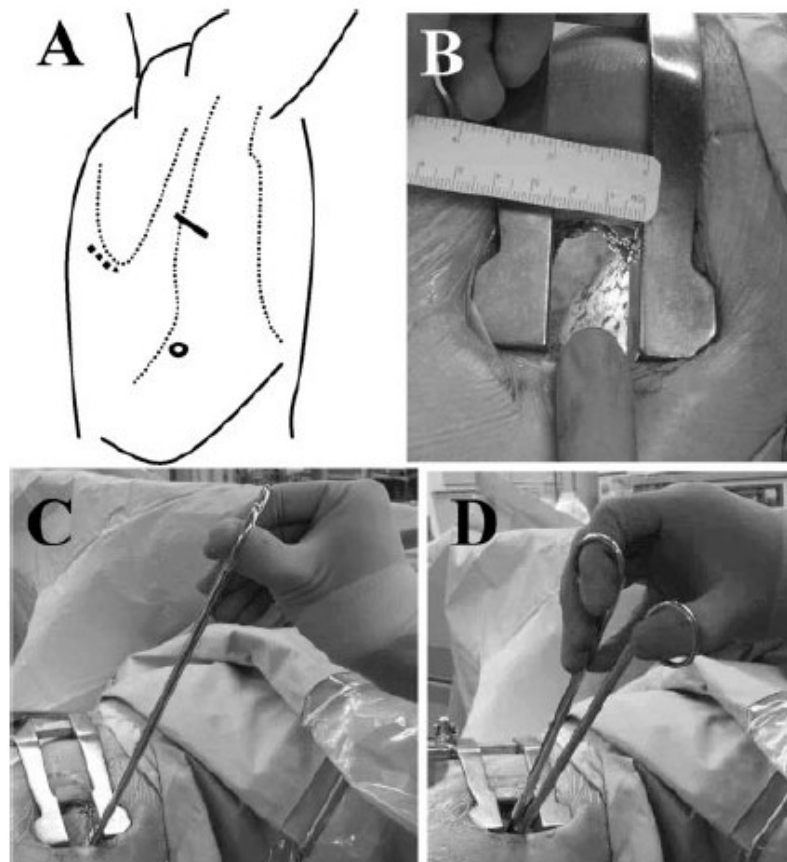
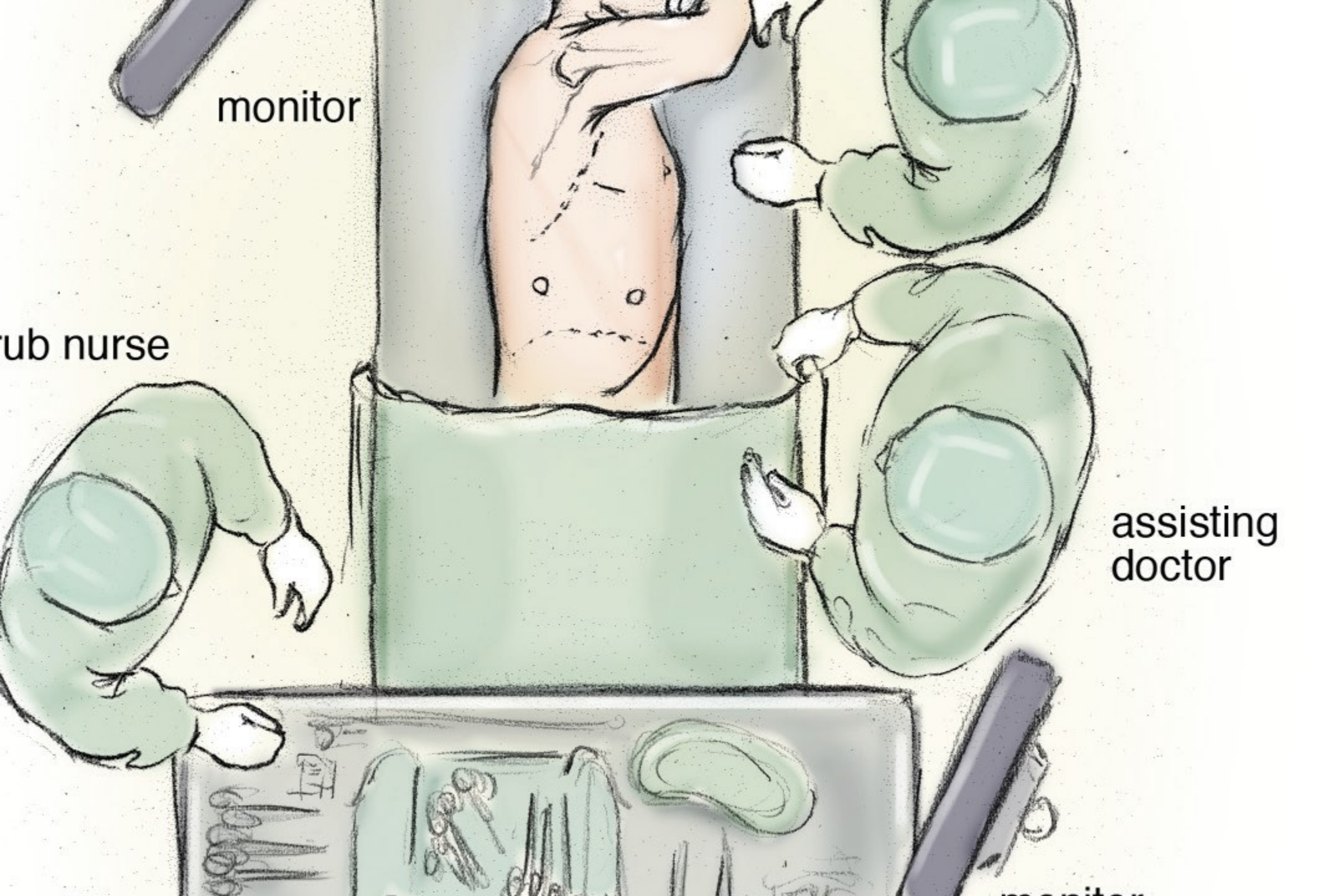


FIGURE 1. *Top left, A:* Skin incisions for one access port for a thoracoscope (circle) and for an access thoracotomy (solid line), which is made over the midaxillary line in the fourth interspace for upper or middle lobe tumors. Lower lobe tumors are approached through the auscultatory triangle in the fifth interspace (dotted line). An operative exposure about 2-cm-wide is made using a thoracic opener (*top right, B*), and dissection through direct vision is performed using an upside-down grip of 30-cm-long scissors, which the surgeon can maneuver at will by turning up the wrist (*bottom left, C*, and *bottom right, D*).

monitor

sub nurse

assisting
doctor



ATTIVITA' di CHIRURGIA TORACICA
ASST Papa Giovanni XXIII

Neoplasie polmonari

Neoplasie del Mediastino

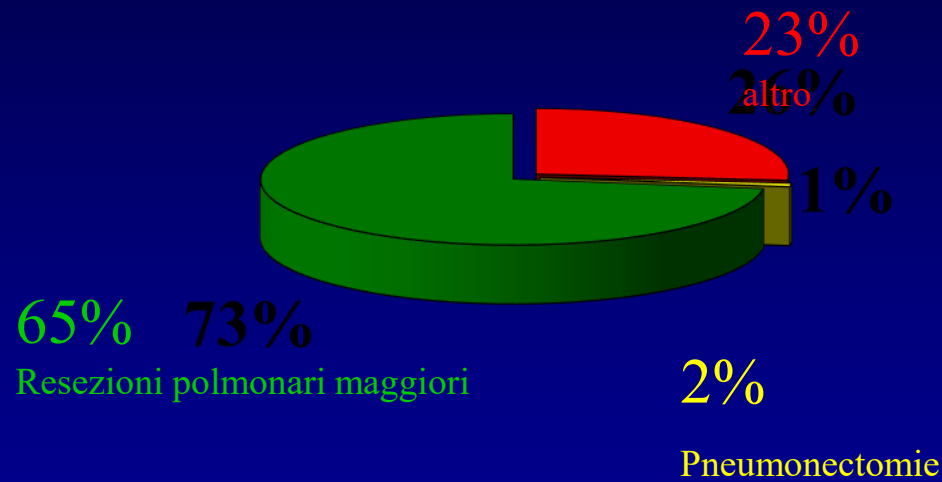
Neoplasia esofagee

Centro regionale di riferimento del trauma toracico

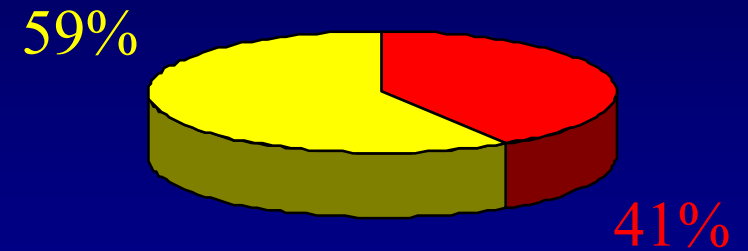
Attività di trapianto polmonare (Chirurgia 3[^])

Tipologia di interventi e Classi di età

Interventi



Classi di età

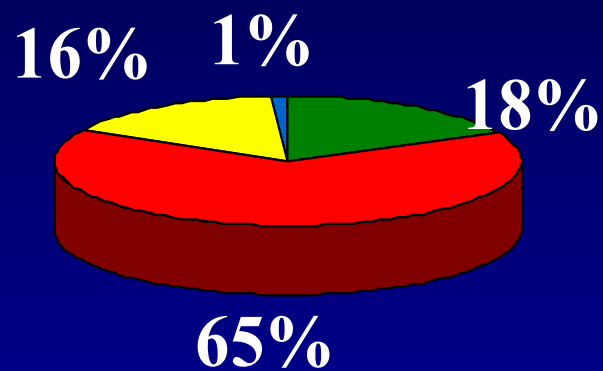


- < 65 anni
- > 65 anni

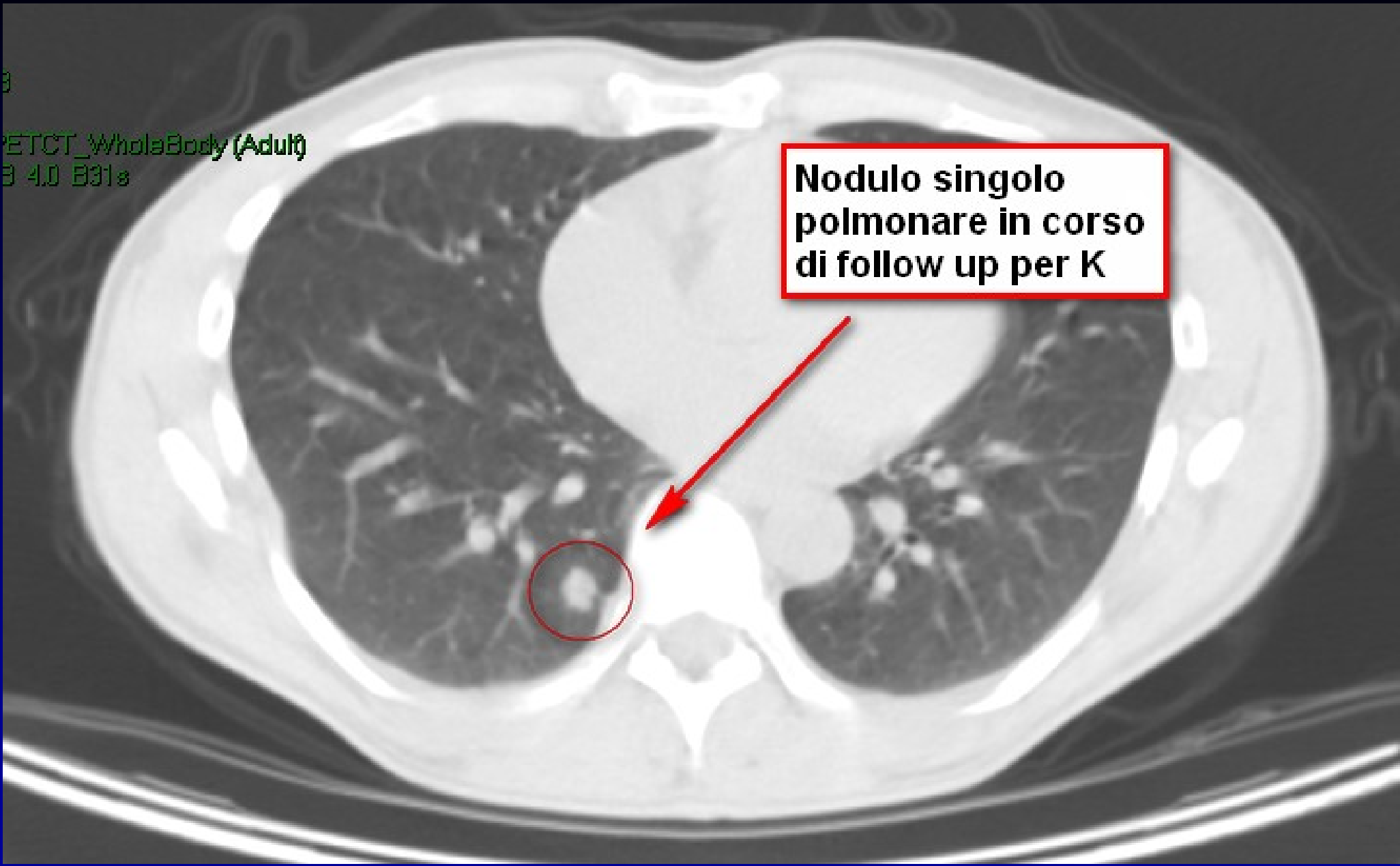
Chirurgia Toracica

ASA preoperatorio

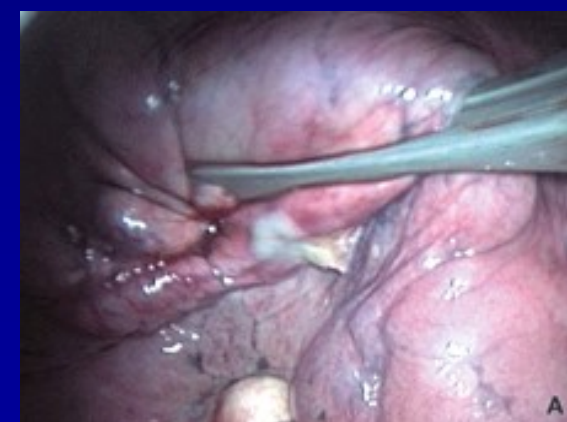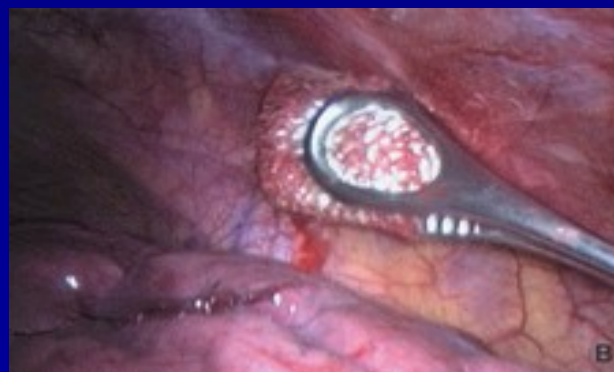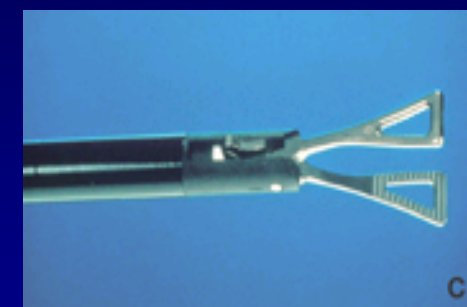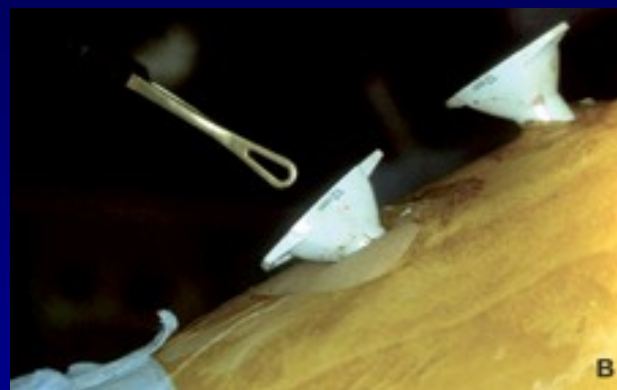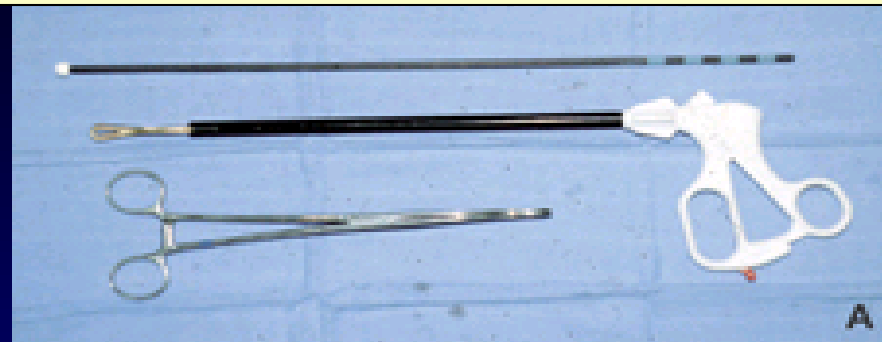
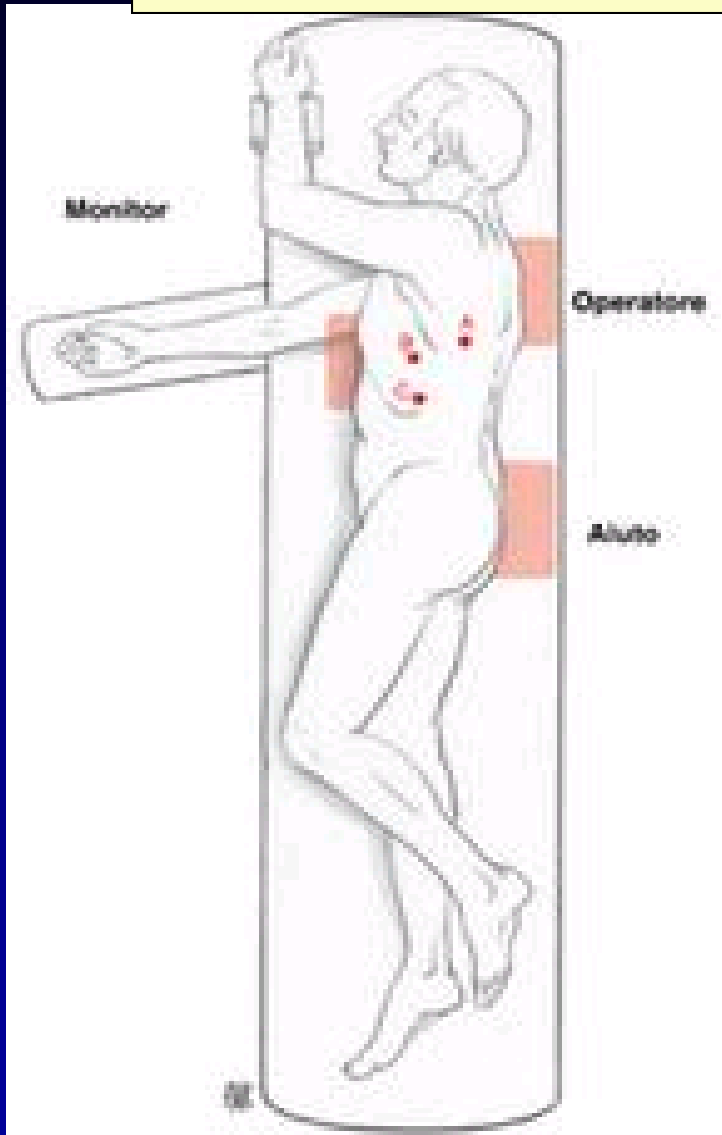
Status ASA %



**Nodulo singolo
polmonare in corso
di follow up per K**

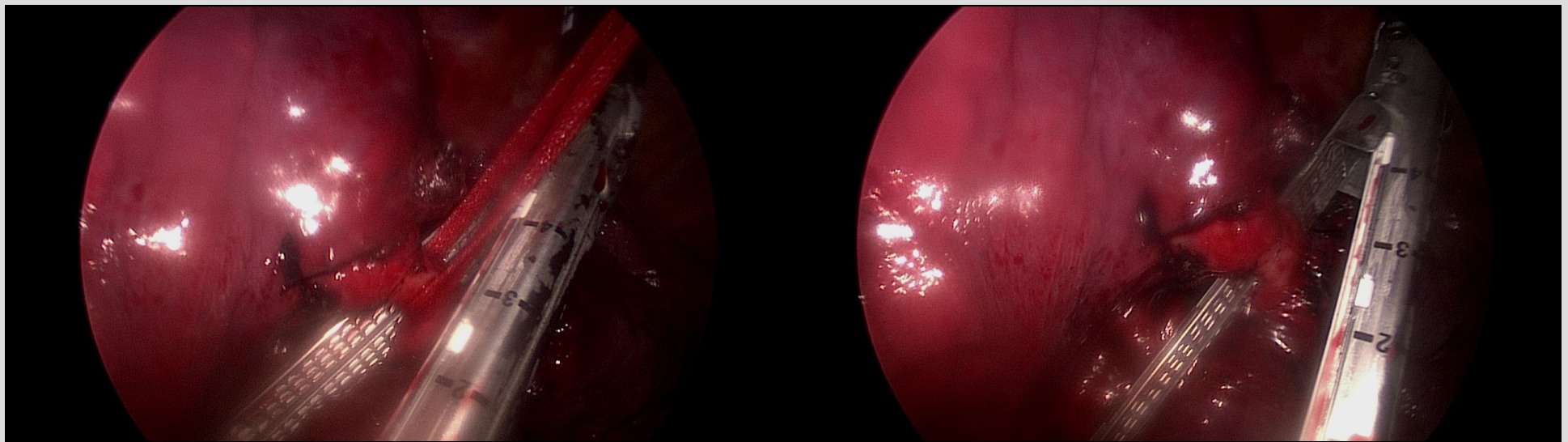
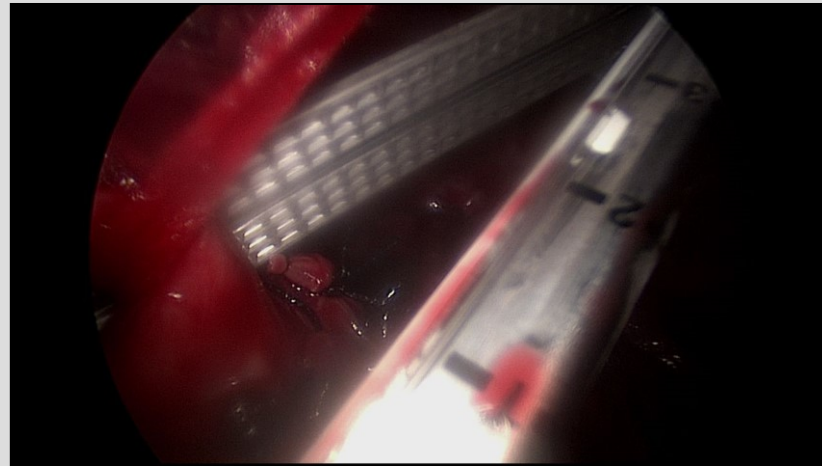


POSIZIONE DEL PAZIENTE E MATERIALE VARIO PER TORACOSCOPIA VIDEOASSISTITA (VATS)



A. R.: LOBECTOMIA INFERIORE DESTRA IN VATS

Adenocarcinoma del lobo inferiore destro



Isolamento e sezione dell'arteria polmonare tra ramo del lobo medio e ramo del sg apicale del lobo inferiore

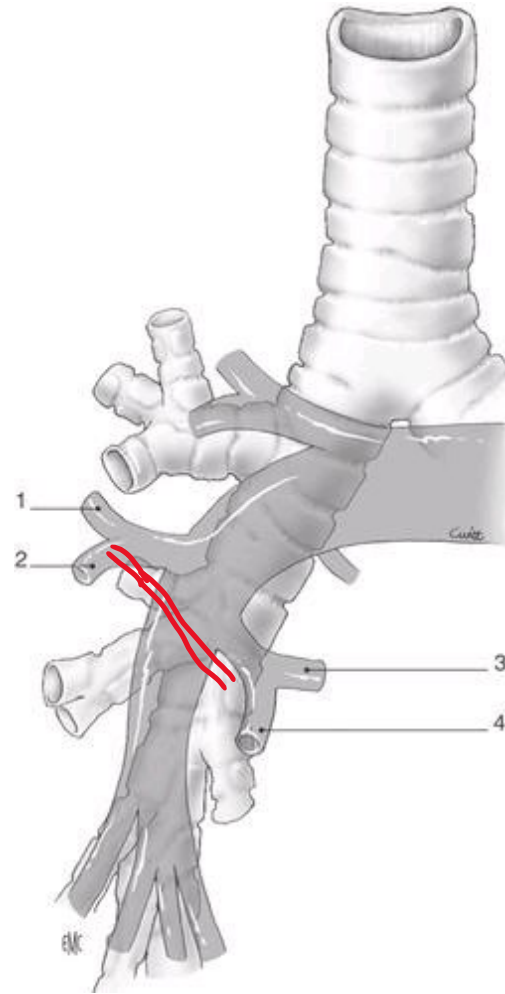
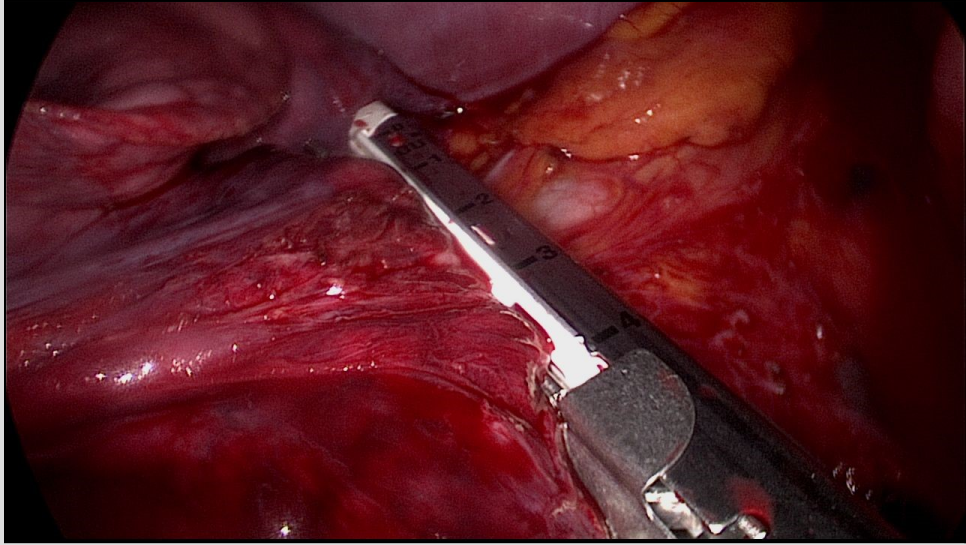
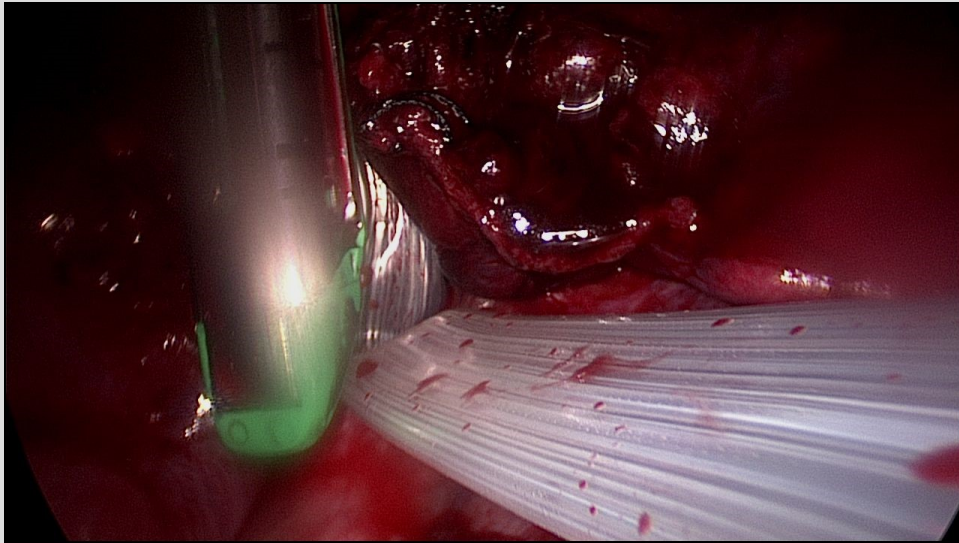
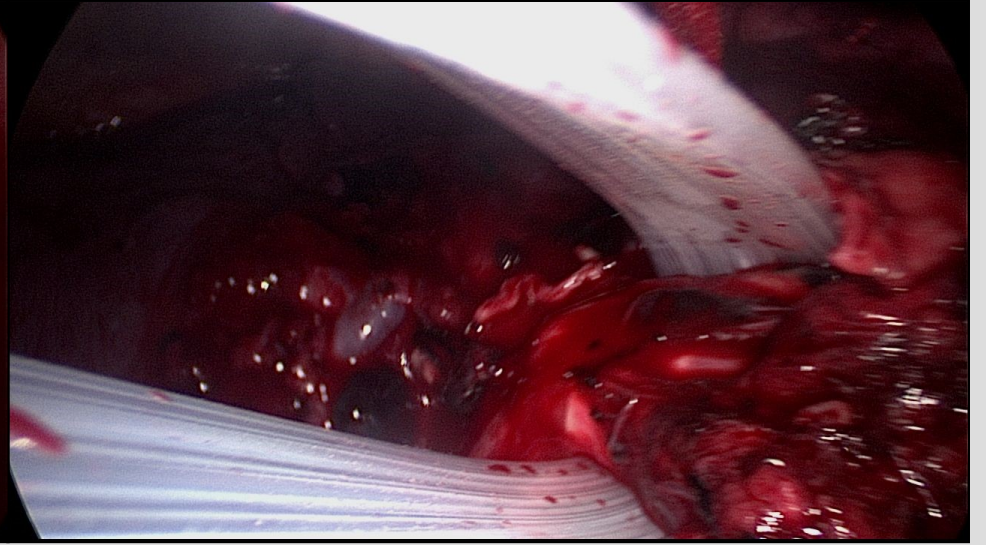


Figura 3 : Variazioni anatomiche dell'arteria polmonare destra: tronco comune. 1. Arteria scissurale; 2. Arteria per il lobo di Nelson; 3 . Arteria scissurale ventrale; 4. Arteria lobare media.

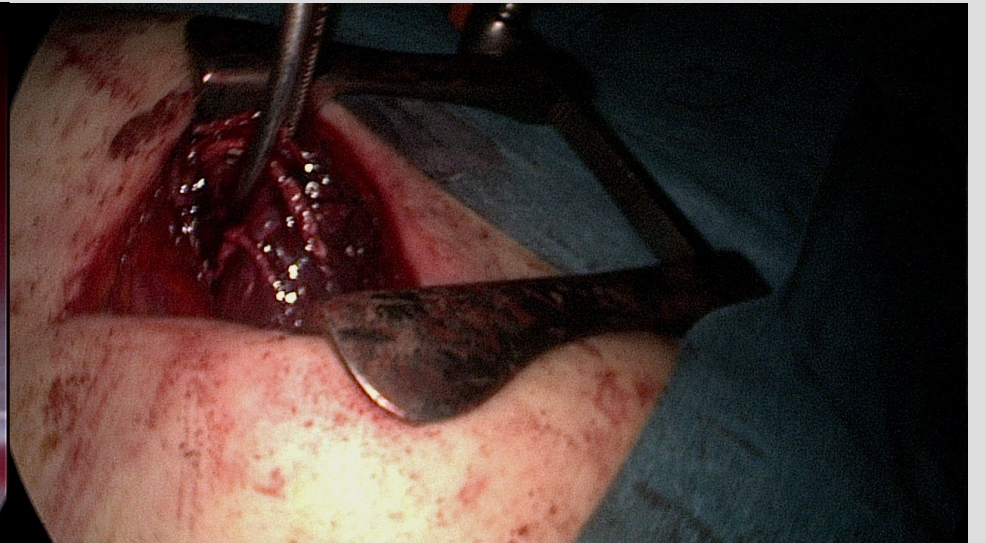Sezione della vena polmonare inf.



Isolamento del bronco lobare inferiore



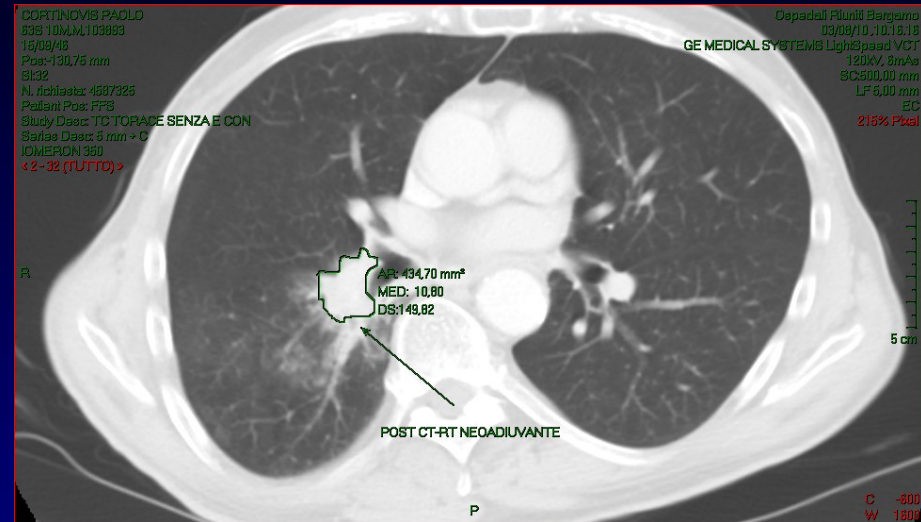
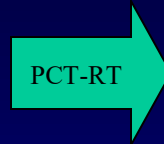
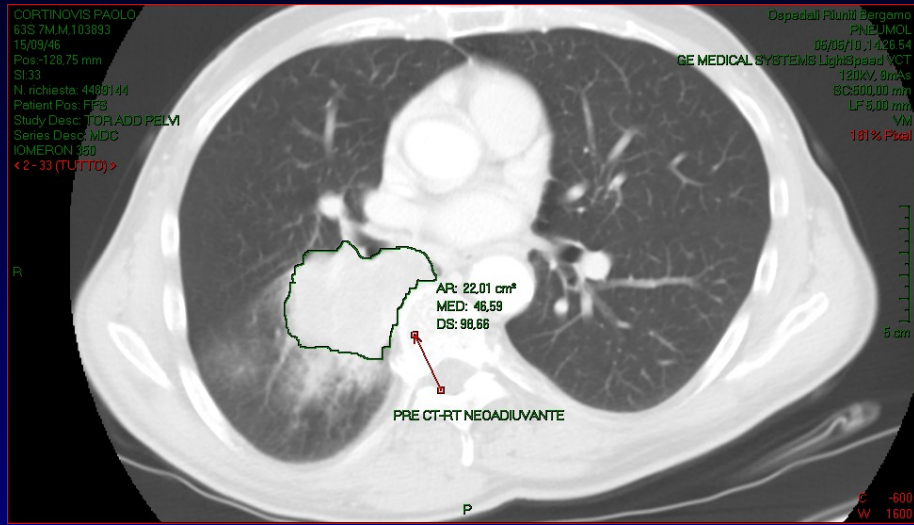
Sezione del bronco lobare inferiore



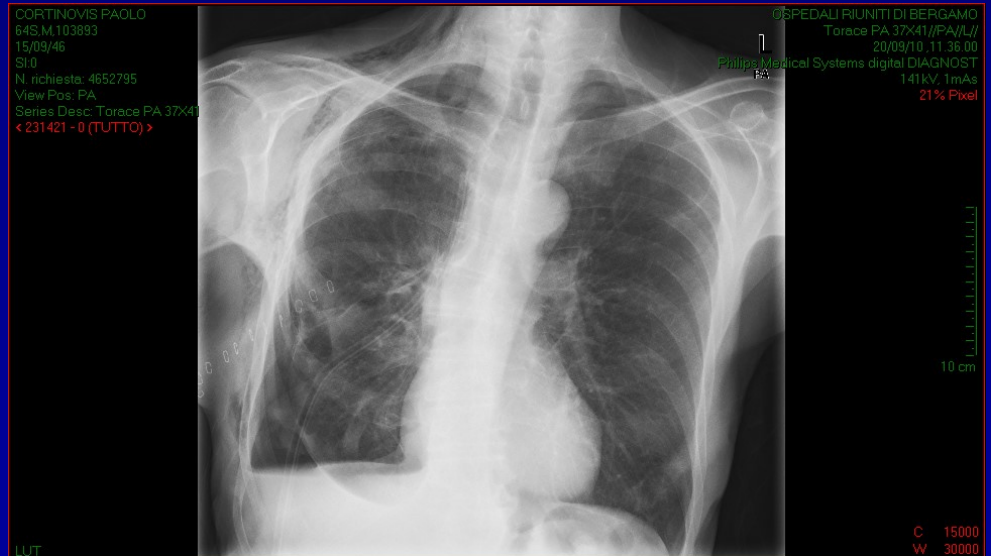
Estrazione del pezzo

Caso Clinico

Caso Clinico



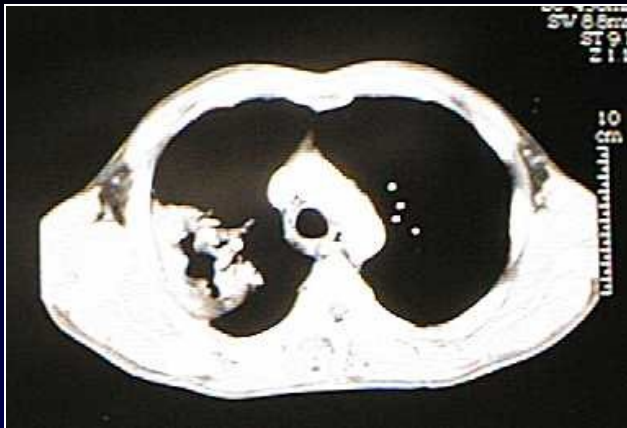5° gg. POST. OP.



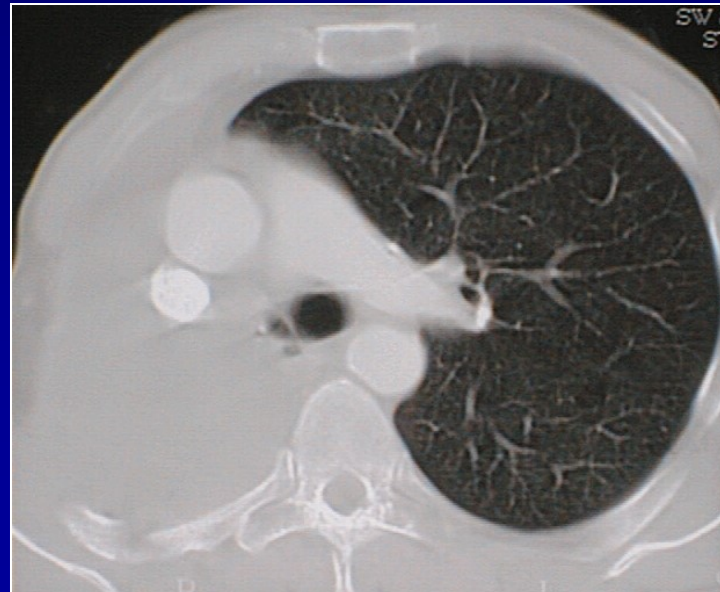
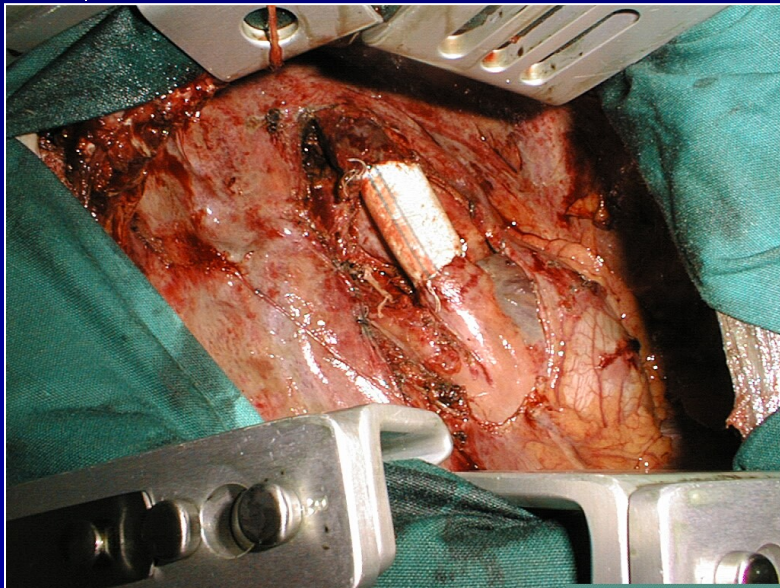
Neoplasie Polmonari

Caso Clinico

- Neoplasia del lobo superiore destro
- Reperto intra operatorio di infiltrazione della vena cava superiore
- Pneumonectomia con sostituzione della VCS mediante protesi in PTFE

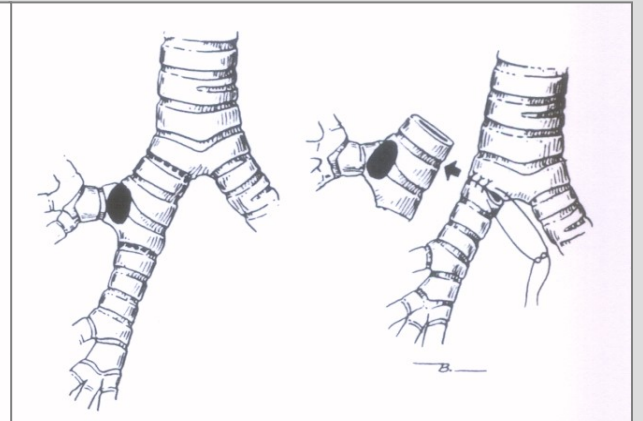
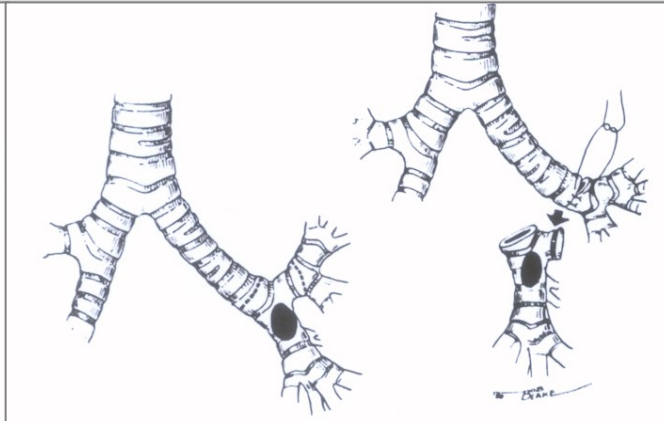
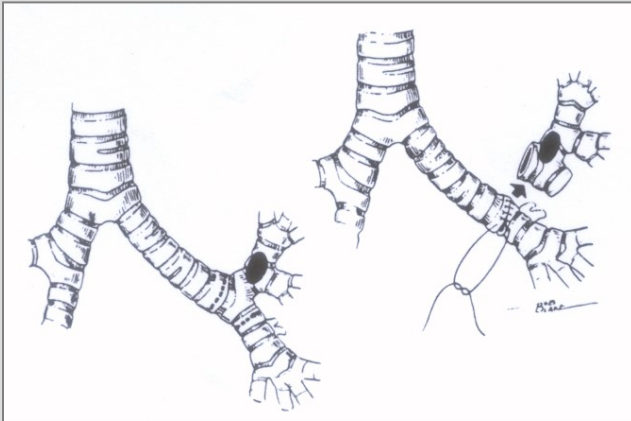
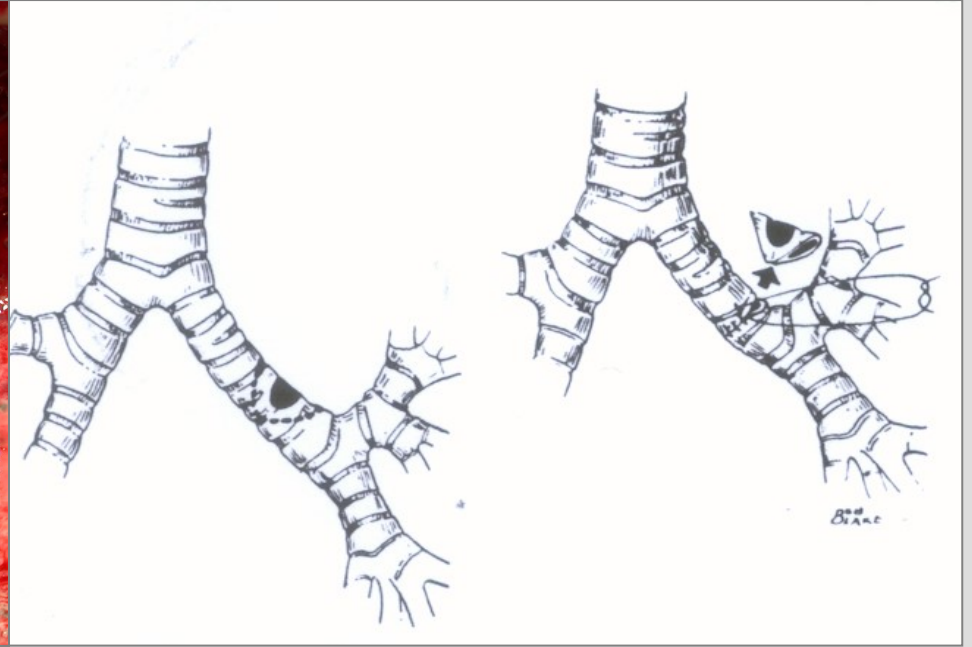
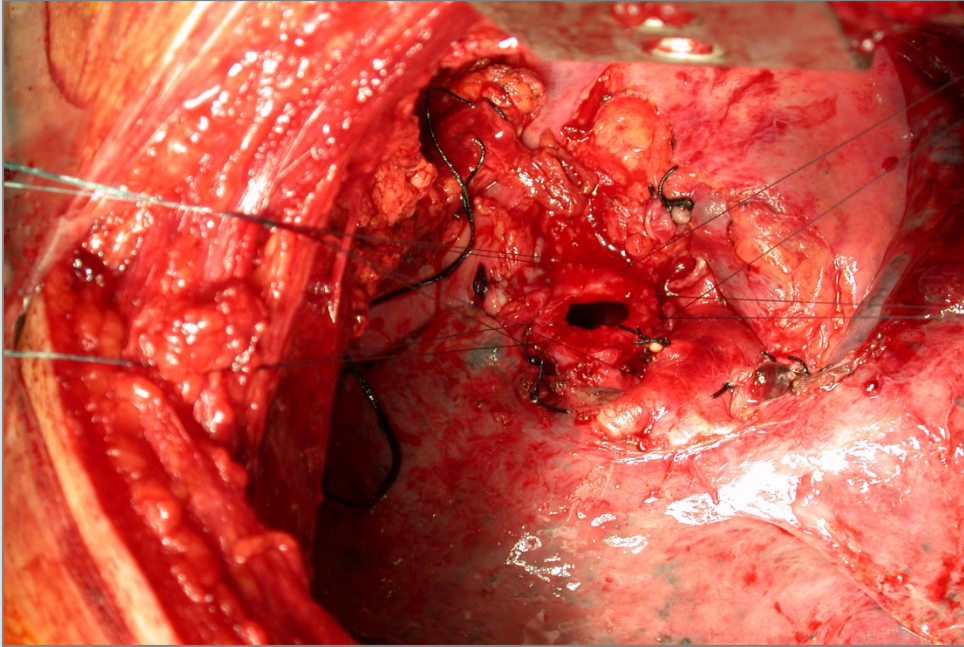


- Immagine TC pre-operatoria
- Protesi in PTFE



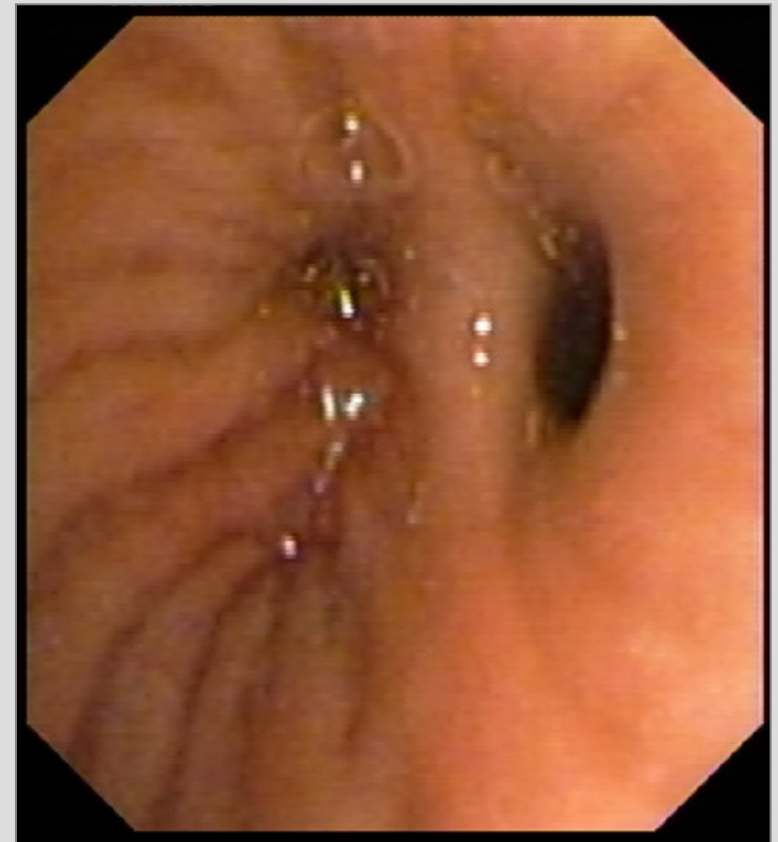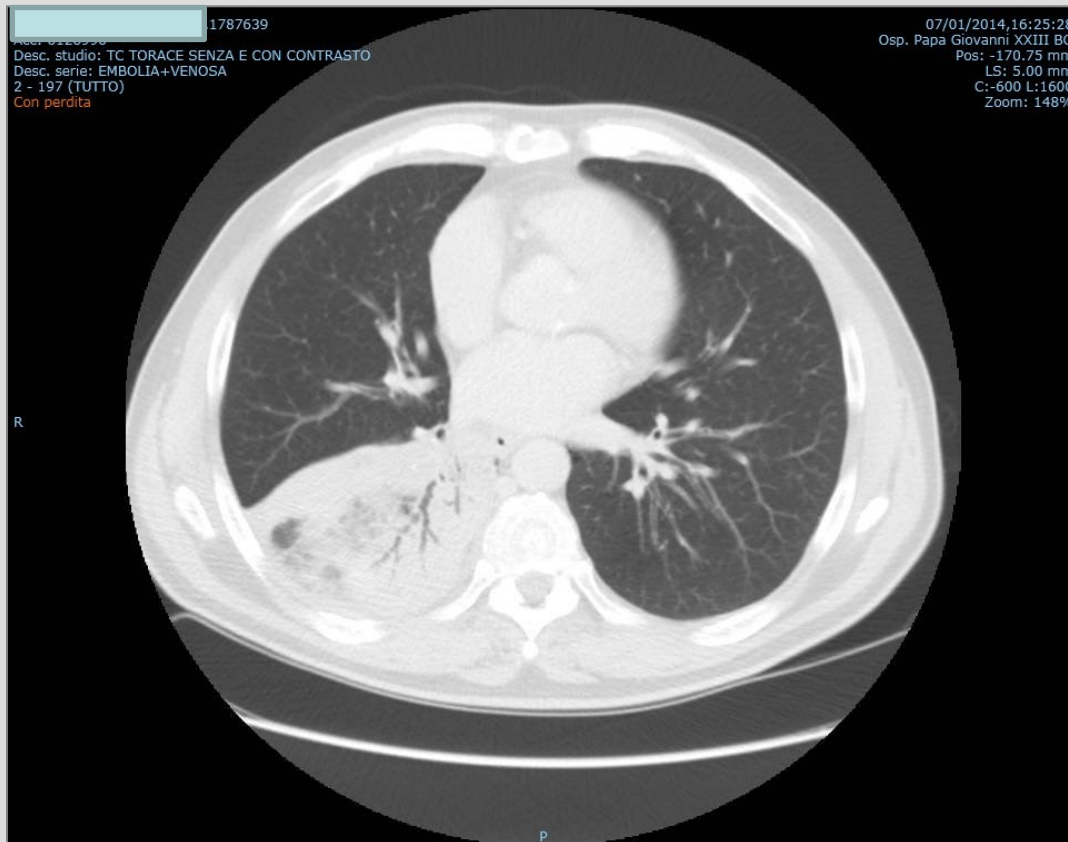
- Pervietà della protesi al controllo TC postoperatorio

X. X. : LOBECTOMIA SUPERIORE DESTRA CON SLEEVE BRONCHIALE



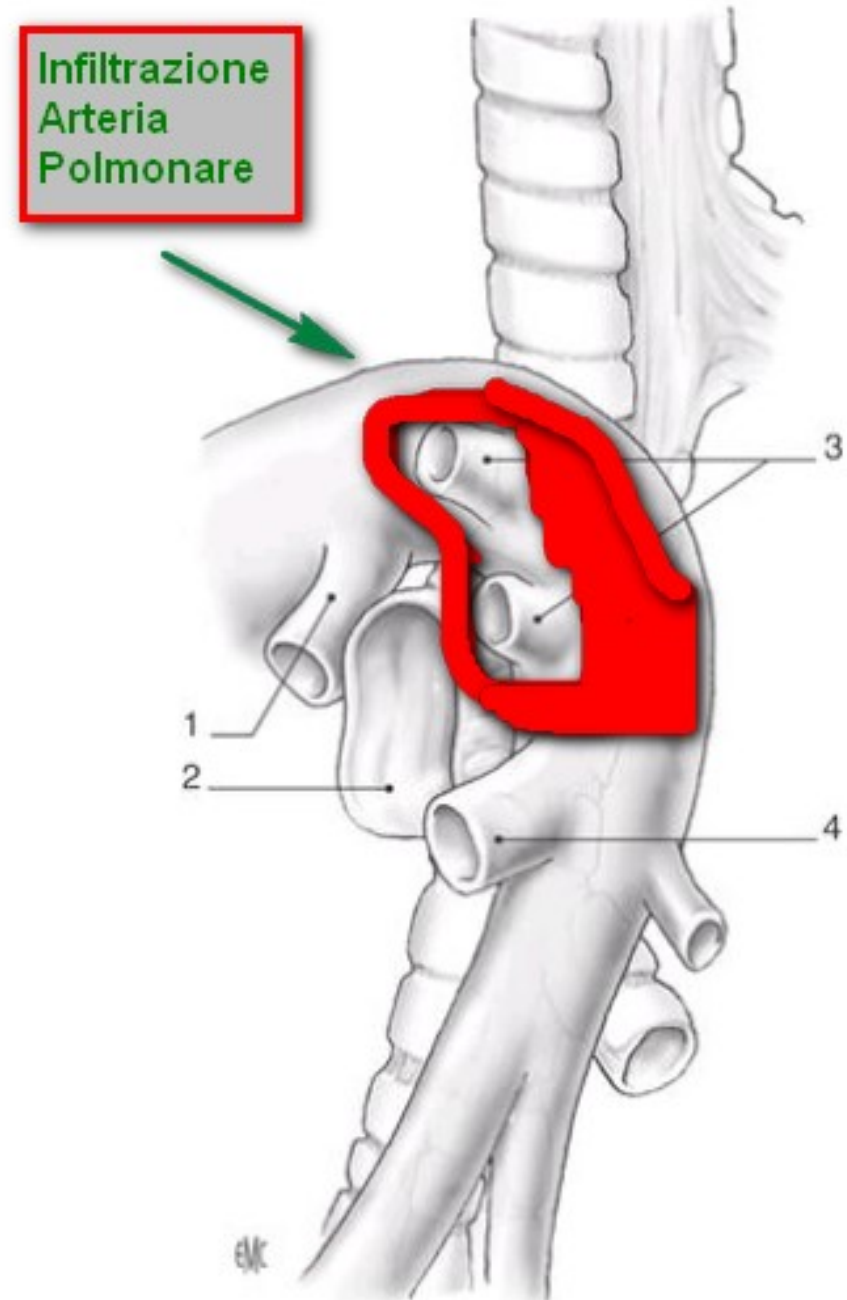
A. M. P.: BILOBECTOMIA DESTRA

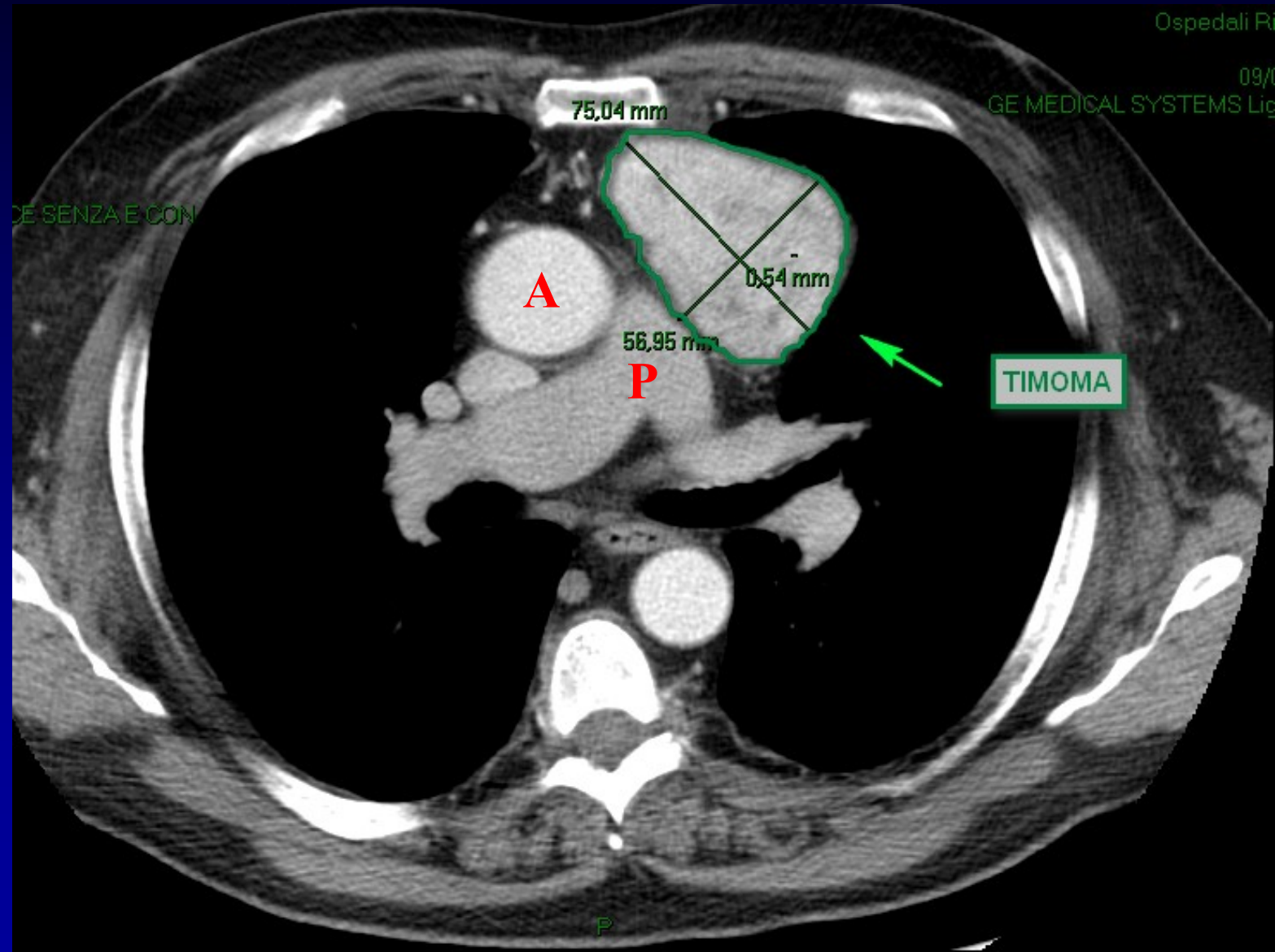
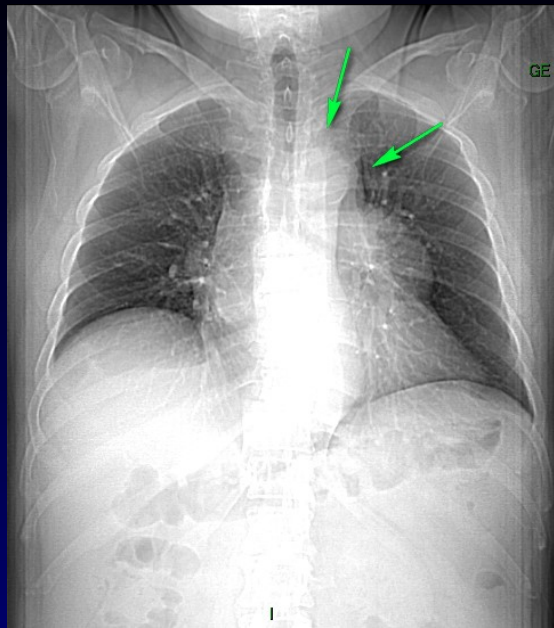
Carcinoma squamocellulare del lobo inferiore destro con occlusione del bronco lobare inferiore e infiltrazione del bronco lobare medio
T2a N0 M0

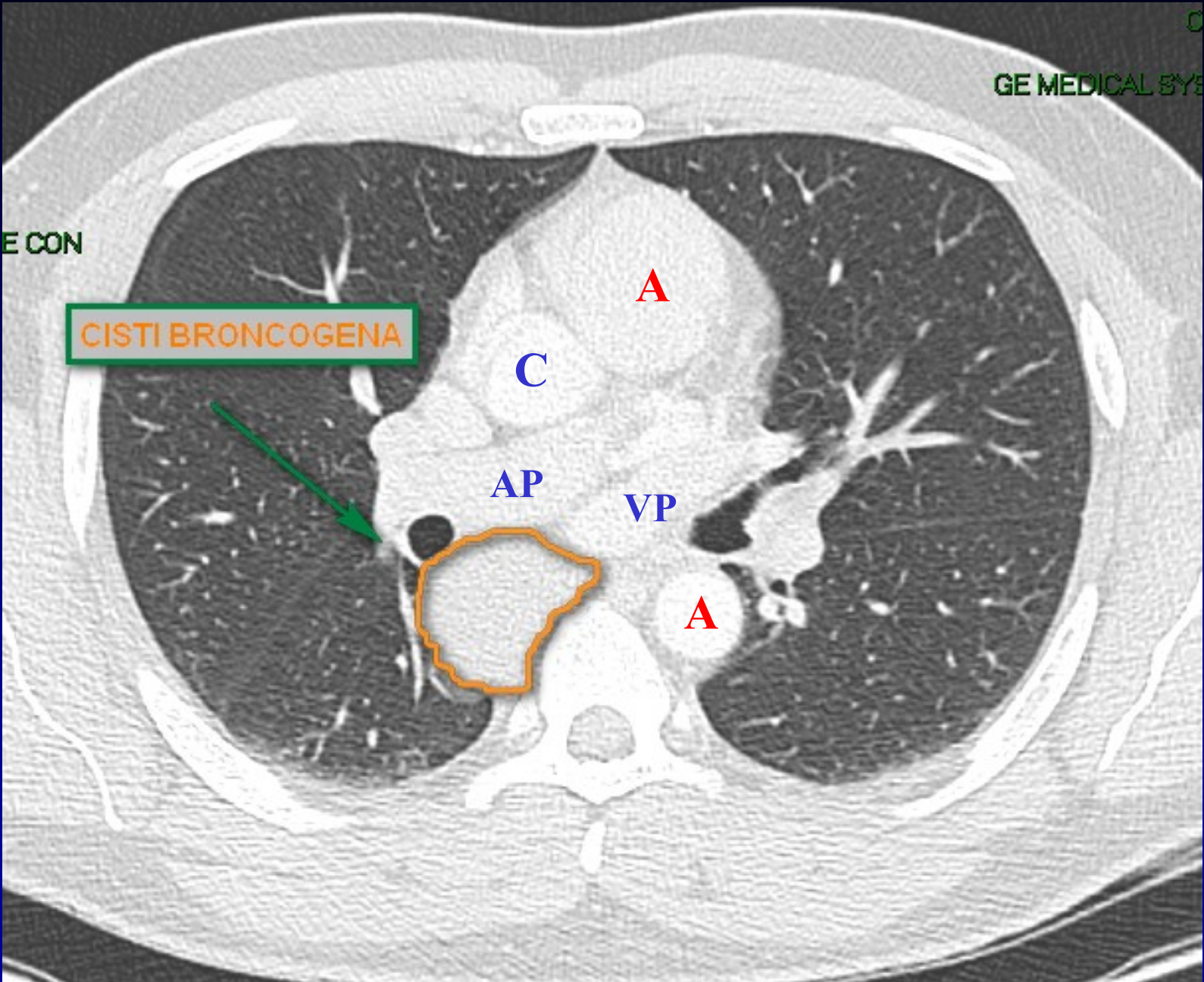


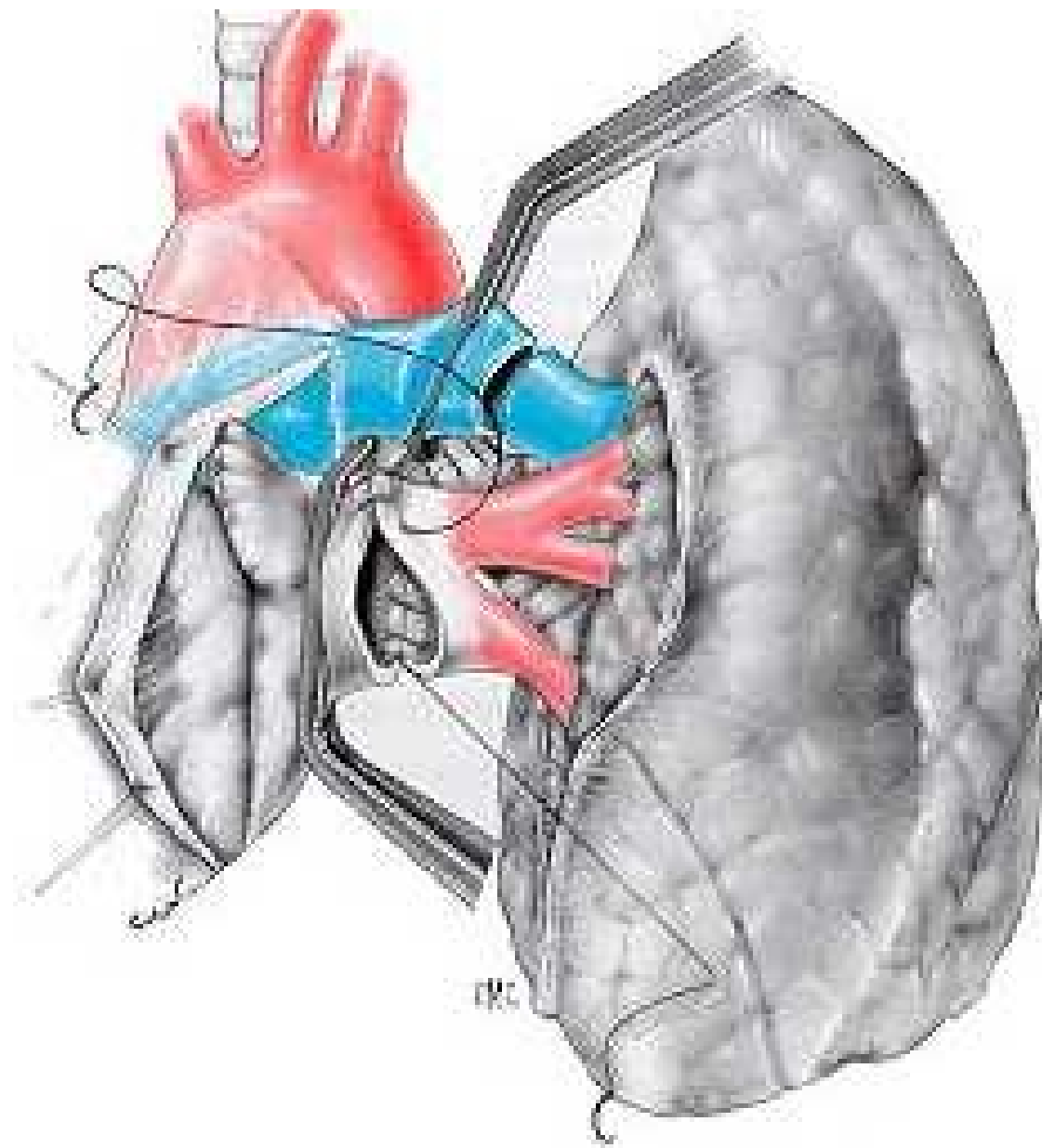
Sleeve / Plastica Arteria polmonare

1. Arteria mediastinica;
2. Bronco lobare superiore
3. Arterie dorsali
4. Arteria lingulare.



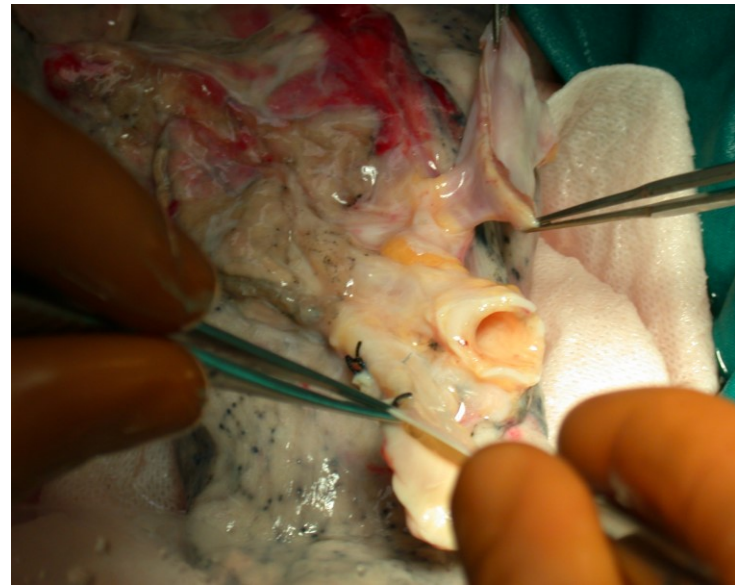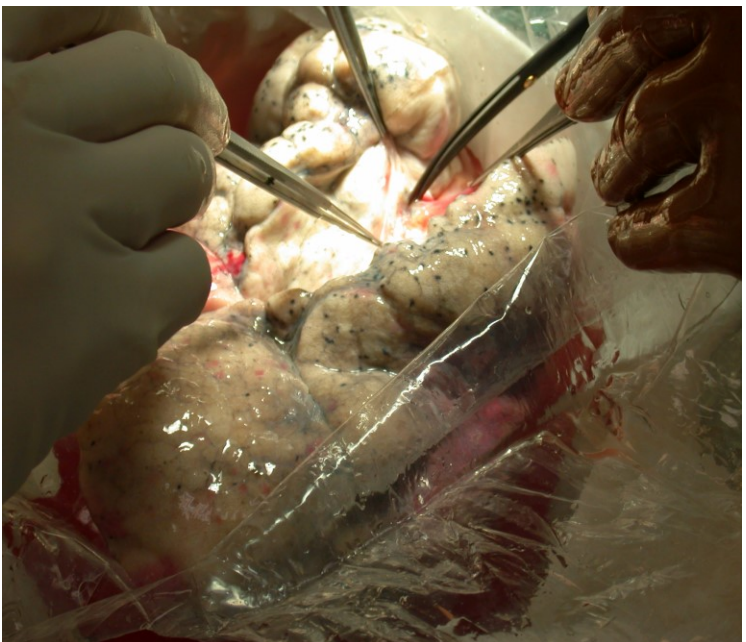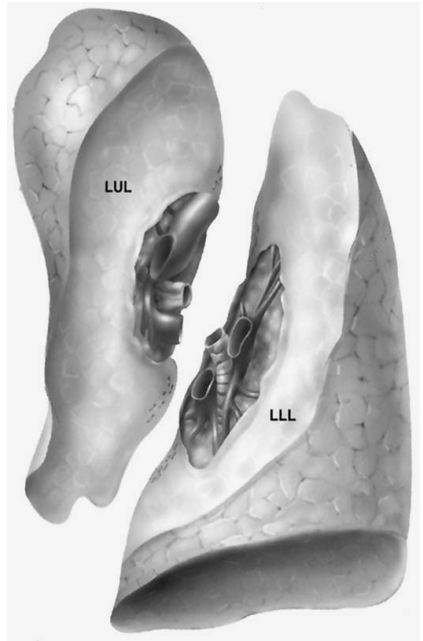
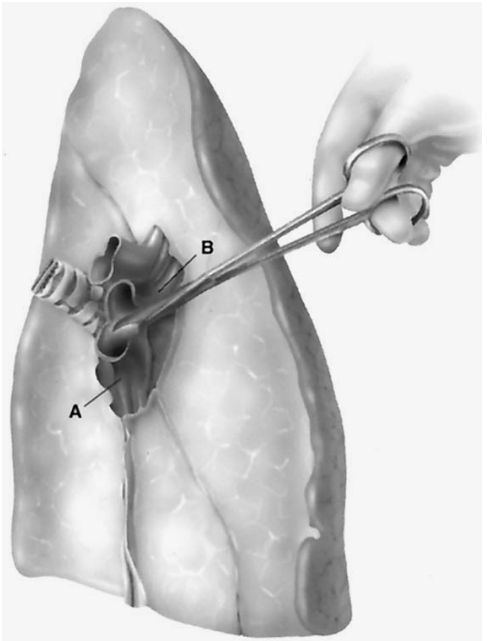
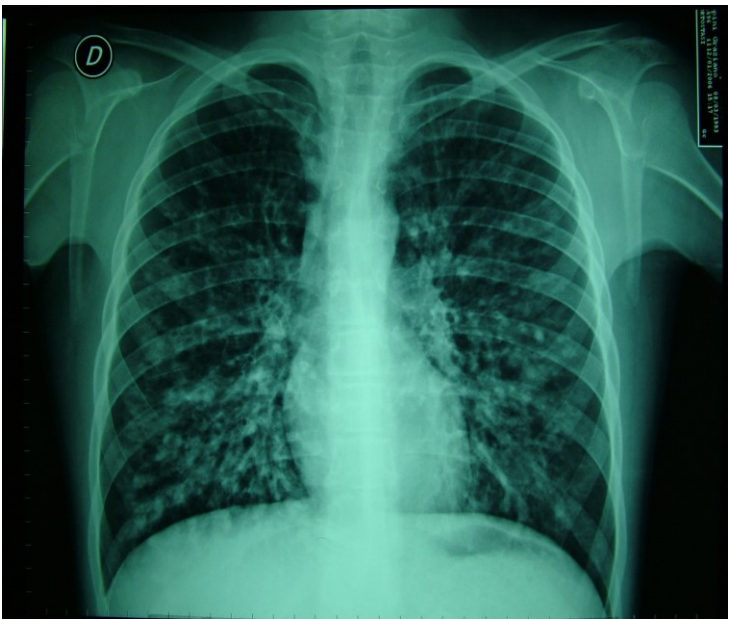




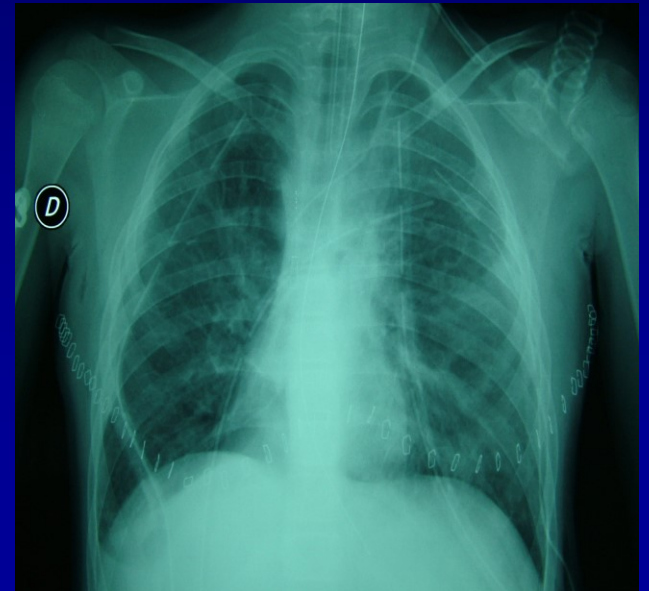
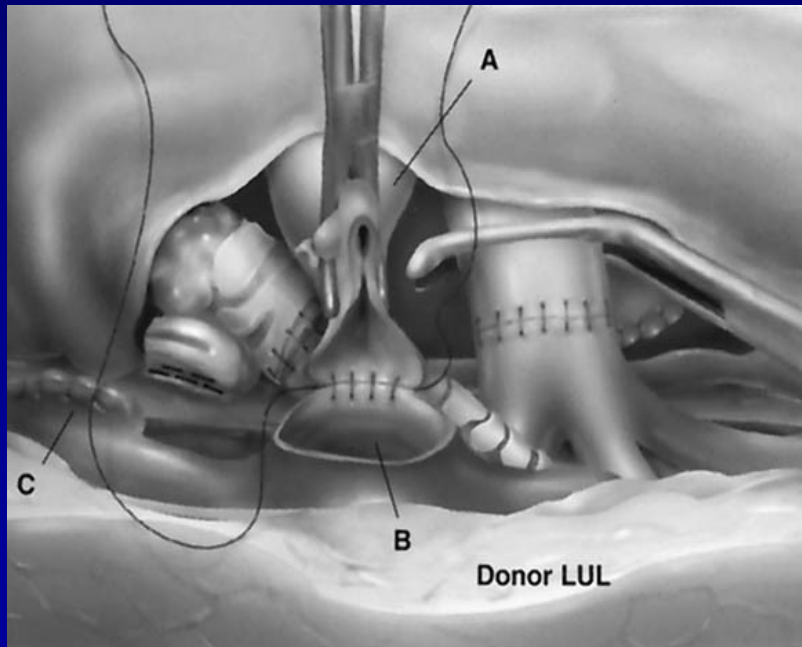
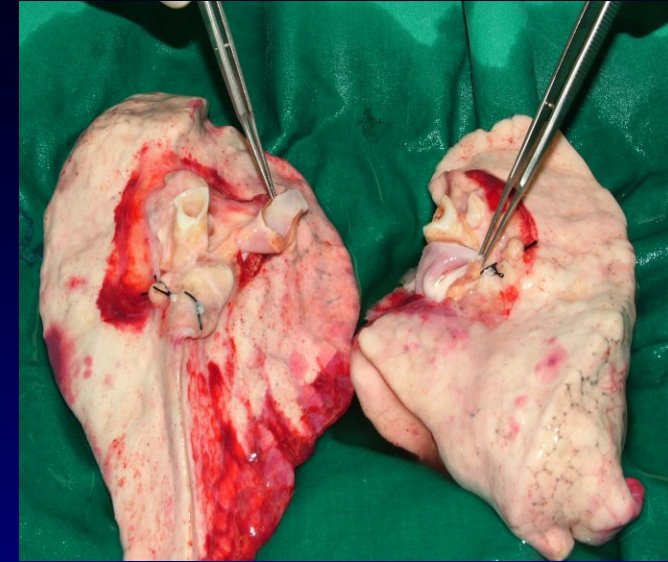
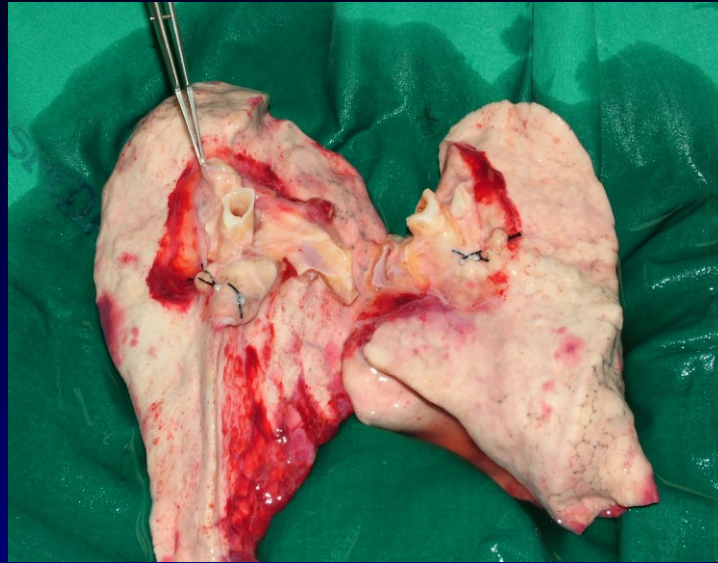
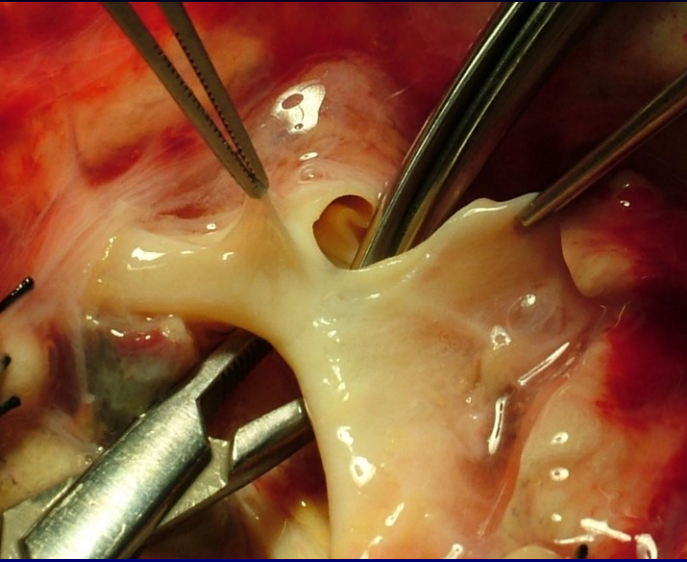


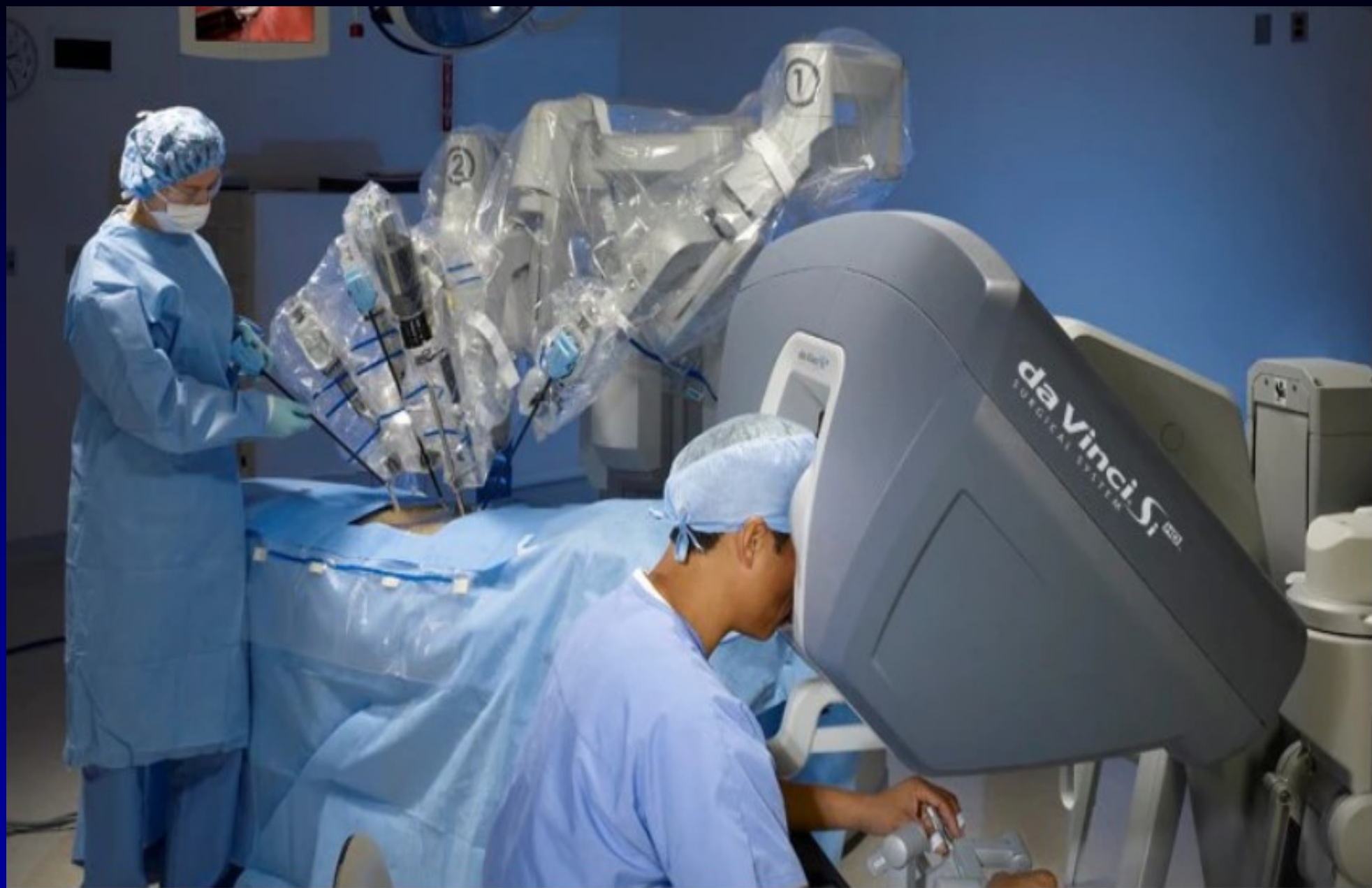CENTRO PER IL TRAPIANTO DI POLMONE DAL 2003 – COLLABORAZIONE FINO al 2018

TRAPIANTO BIPOLMONARE PEDIATRICO CON POLMONE SINISTRO DA DONATORE ADULTO TECNICA SPLIT (1)



TRAPIANTO BIPOLMONARE PEDIATRICO CON POLMONE SINISTRO DA DONATORE ADULTO TECNICA SPLIT (2)





CONCLUSIONI

- Popolazione ad elevata complessità
- Integrazione di competenze multidisciplinari (Pneumologia, Chirurgia, Oncologia Medica, Radioterapia, Anestesia-Rianimazione)
- Integrazione/Sinergia tra Chirurgia Generale e Chirurgia dei Trapianti